

# Treatment of Acute Acromioclavicular Joint Injuries Using AO Hook Locking Plate

Kyung Cheon Kim<sup>1</sup>, Yoo Sun Jeon

Department of Orthopaedic Surgery, Bumin Hospital, Busan, <sup>1</sup>Department of Orthopaedic Surgery, Chungnam National University School of Medicine, Daejeon, Korea

**Background:** To evaluate clinical and radiological outcome using AO hook locking plate in acute acromioclavicular joint injuries.

**Methods:** This study was based on patients with Rockwood type 3 or 5 acromioclavicular joint injuries who received surgery with AO hook locking plate from June 2008 until June 2009. Among the 22 patients, 19 of them were male and 3 were female, the mean age was  $44.4 \pm 15.57$  years (20–72 years) and follow-up period was  $15.5 \pm 3.90$  months (12–23 months). Preoperatively, postoperatively, and at the final follow-up after the plate removal, both coracoclavicular distances were measured from the anteroposterior radiograph. Also, the Shoulder Rating Scale of the University of California at Los Angeles scores (UCLA scores), the American Shoulder and Elbow Surgeons scores (ASES scores), Constant scores, and the Korean Shoulder Society scores (KSS scores) were measured at the final follow-up to evaluate the function of the shoulder joint.

**Results:** At the time of injury, the mean coracoclavicular distance of the injured side was  $17.69 \pm 4.23$  mm (9.57–27.82 mm) and the unaffected side was  $7.55 \pm 2.20$  mm (3.24–13.05 mm). The mean coracoclavicular distance measured postoperatively and at the final follow-up was  $6.87 \pm 2.34$  mm (4.07–14.13 mm) and  $8.47 \pm 2.96$  mm (4.37–17.48 mm), respectively. The mean UCLA, ASES, Constant, and KSS scores measured in the final follow-up were  $33.5 \pm 1.30$  (31–35),  $90.8 \pm 8.36$  (72–100),  $78.6 \pm 8.80$  (62–100), and  $94.4 \pm 5.08$  (84–100) each.

**Conclusions:** From this short-term research, the surgical treatment using AO hook locking plates in acute acromioclavicular joint injuries is clinically and radiographically satisfying and considered as a useful treatment method.

(*Clin Shoulder Elb* 2014;17(3):114-119)

**Key Words:** Shoulder; Acromioclavicular joint; Hook plate

## Introduction

The treatment of acute acromioclavicular joint injury of the shoulder depends on the degree of injury, and the patients are accordingly allocated either to conservative or surgical treatment. Surgical treatment may be carried out in several ways, choosing from a variety of materials used for insertion and suture, and these variations of surgical methods differ in their rates of success.<sup>1-3)</sup> The surgical method of using material such as pins, wires, suture anchors, non-absorbable suture material have shown mixed results. Whilst their clinical outcomes are satisfactory, their shortfalls include the possibility of reduction loss and the inability to begin early joint exercise.<sup>2-4)</sup> In biomechanical

tests, the Weaver-Dunn method, in which the bone block transfer of coracoacromial ligaments is carried out alone, failed to recover the normal strength of the coracoclavicular ligament.<sup>5)</sup> Also, the modified Phemister method is reported with several complications from failure of hardware, which explains the current decreasing trend of its use.<sup>6-8)</sup> The acromioclavicular hook plate was first designed by Balser<sup>9)</sup> in 1976, and its use began to increase in the 1980s.<sup>10-12)</sup> Only patients with a Rockwood 3 or 5 acute acromioclavicular joint injury were given surgical treatment using AO hook locking plates. Here, we analyze the clinical outcome of the AO hook locking plate surgery via clinical and radiological examinations, observing the pre- and post-surgery coracoclavicular distances, forward flexion angle, as well

Received April 28, 2014. Revised July 10, 2014. Accepted July 14, 2014.

**Correspondence to:** Yoo Sun Jeon

Department of Orthopaedic Surgery, Bumin Hospital, 59 Mandeok-daero, Buk-gu, Busan 616-819, Korea

**Tel:** +82-51-330-3082, **Fax:** +82-51-330-3075, **E-mail:** osdoc2013@hanmail.net

**Financial support:** None. **Conflict of interests:** None.

as four different shoulder function tests.

## Methods

From June 2008 to June 2009, the study targeted patients with Rockwood 3 or 5 acute acromioclavicular joint injuries with pain or compression in the shoulder. The coracoclavicular distance in Rockwood 3 patients were increased by less than two times that of the injured side, whereas in Rockwood 5 patients it was increased by more than two times. All patients undergoing surgical treatment were treated with AO hook locking plates (Locking Compression Clavicle Hook Plate; Synthes, Paoli, Switzerland). The total number of patients that visited the ward during the study period was 28. Of these patients, 2 were excluded because they had neglected the injury for at least 3 months after obtaining it, and a further 4 were excluded because of loss to follow-up for at least 1 year after surgery. Of the remaining 22 patients, 5 and 17 patients were categorized into Rockwood 3 and 5, respectively. The patient profile is as follows: of the 22 patients, 19 were male and 3 were female, 5 were injured on the right and 17 on the left, the average age was  $44.4 \pm 15.57$  years (20–72 years), the average length of observation period was  $15.5 \pm 3.90$  months (12–23 months), and the average period from the point injury to surgery was  $3.5 \pm 1.77$  days (1–7 days). Additionally, in all of the patients, AO hook locking plates were used for fixation and neither coracoclavicular ligament repair nor reconstruction was carried out.

### Surgical Method

All surgical treatments were carried out by the first author. The patients were placed in Fowler's position, and the outer third region of the clavicle in relation to the acromioclavicular joint was identified. Here, an incision of approximately 8 cm was made, which was then peeled to reveal the acromioclavicular joint. The assistant lifted the patient's elbow forward, and at this state, the hook of the plate was pushed below the acromion, thus achieving the reduction of the acromioclavicular joint. To maintain the reduction, a Kocher forcep was used to securely fix the plate and clavicle. At this stage, fluoroscopy was used to check that the depth of the hook was adequate, and in cases of excess reduction or over-reduction, the plate was replaced with one that has a different size hook. Other surgical treatments such as coracoacromial ligament repair were not carried out. Afterwards, around 3 to 4 locking screws of 3.5 mm in size were used to fix the plate, and a bioabsorbable suture was used to suture the muscular and the subcutaneous layers, whilst an ordinary suture was used to suture the skin.

### Postoperative Care

After surgery, all patients used wore an arm brace for 4 weeks, after which all possible passive and active joint motion exercises

were started. Any excessive activity or exercises were restricted, and the removal of the plate was agreed on at 4 months to prevent osteolysis. Accordingly, the plates were removed at an average time of  $5.95 \pm 2.87$  months (4–16 months) after surgery. To remove the plate, the excision line made previously was used, through which the plate was stripped along the posterior border. During the removal of the plate, damage to the acromioclavicular joint and the soft tissue was kept minimal by removing the plate at a rotated angle. After removal, the incision region was sutured.

### Clinical Assessment Method

All patients were assessed by the first author at three different points; before and after the surgery, and at the final follow-up after the removal of the plate. Picture archiving & communication system (PACS) was used to analyze the antero-posterior aspect of both sides of the clavicle, which was then used to obtain the coracoclavicular distance. This distance was measured from the clavicle to the attachment site of the coracoid process. At the final follow-up, the presence of bone erosion or osteoarthritis was determined. Additionally, the shoulder function was assessed, including the range of joint motion for which a simple diagnostic tool, measuring the forward flexion angle, was used. The clinical shoulder function tests used were the Shoulder Rating Scale of the University of California at Los Angeles scores (UCLA scores), the American Shoulder and Elbow Surgeons scores (ASES scores), the Constant scores, and the Korean Shoulder Society scores (KSS scores). Statistical analysis was carried out using PASW Statistics ver. 18.0 (IBM Co., Armonk, NY, USA).

## Results

At the time of injury, the coracoclavicular distance was on average  $7.55 \pm 2.20$  mm (3.24–13.05 mm) on the unaffected side and  $17.69 \pm 4.23$  mm (9.57–27.82 mm) on the injured side. In the after surgery and final follow-up, this distance was on average  $6.87 \pm 2.34$  mm (4.07–14.13 mm) and  $8.47 \pm 2.96$  mm (4.37–17.48 mm), respectively. The results show that, when comparing the distance before the surgery and at the final follow-up, there is a statistically significant improvement following surgery in every patient ( $p < 0.001$ ). At the final follow-up, the forward flexion angle was on average  $173.2^\circ \pm 13.23^\circ$  ( $120^\circ - 180^\circ$ ), and the average UCLA, ASES, Constant, and KSS scores were  $33.5 \pm 1.30$  (31–35),  $90.8 \pm 8.36$  (72–100),  $78.6 \pm 8.80$  (62–100), and  $94.4 \pm 5.08$  (84–100) each (Table 1). No complications were observed after plate insertion or removal (Fig. 1). Complications we looked for included acromioclavicular redislocation, fracture of the clavicle or acromion, damage of the plate or suture anchor, infection etc. In principle, we decided to remove the plate at 4 months after insertion, and on average, the plate was removed at  $5.95 \pm 2.87$  months (4–16 months).

Table 1. Data of Patients with Acromioclavicular Injuries Treated by Operation Using AO Hook Plate

Case No.	Age (yr)	Sex	Type*	Time to surgery (d)	Follow-up period (mo)	Plate size	Time to metal removal (mo)	Normal CC	Preoperative CC	Postoperative CC	Last follow-up CC	Last follow-up FF (°)	UCLA scores	Constant scores	KSS scores	Early erosion	Last follow-up erosion	OA	
1	59	Male	V	7	23	Left, 5H, 15D	12	6.64	14.39	4.63	4.87	120	32	85	70	84	+	-	
2	49	Male	III	2	22	Left, 5H, 15D	8	6.84	13.02	4.93	6.10	180	35	100	85	100	+	-	
3	50	Male	V	3	19	Left, 5H, 15D	7	4.06	17.22	6.80	6.66	180	33	95	83	99	+	-	
4	72	Male	V	1	18	Left, 5H, 15D	5	6.99	17.46	6.56	7.97	170	35	95	85	98	+	+	
5	44	Male	V	4	18	Left, 5H, 15D	5	7.80	19.89	10.24	11.00	170	33	98	71	96	-	-	
6	21	Female	V	3	12	Left, 5H, 15D	6	8.25	18.24	7.55	8.87	180	35	100	75	97	-	+	
7	57	Male	V	5	14	Left, 5H, 15D	16	7.51	20.93	4.07	4.37	170	33	87	84	92	+	-	
8	59	Female	V	7	16	Right, 5H, 15D	5	4.83	15.58	6.84	6.84	180	33	100	71	96	+	-	
9	59	Male	V	4	13	Left, 5H, 15D	4	7.96	21.04	6.70	9.62	170	31	82	74	88	+	-	
10	49	Male	V	4	21	Right, 5H, 18D	7	6.70	19.09	5.17	9.31	180	35	100	85	97	+	-	
11	40	Male	V	7	16	Left, 5H, 15D	5	6.66	16.34	8.21	8.54	180	33	77	79	91	-	-	
12	20	Male	V	2	17	Left, 5H, 12D	4	9.36	22.19	8.87	10.65	170	35	95	100	98	-	-	
13	48	Male	V	2	22	Left, 5H, 12D	4	7.03	22.82	6.26	12.49	180	33	95	85	99	-	-	
14	28	Male	V	4	12	Right, 5H, 15D	5	13.05	27.82	14.13	17.48	180	35	90	74	96	+	-	
15	22	Male	III	4	12	Left, 5H, 15D	4	5.98	11.91	6.21	6.61	180	35	100	75	100	-	+	
16	29	Male	V	3	14	Left, 5H, 15D	5	9.00	21.61	4.64	7.63	170	33	90	95	98	-	-	
17	38	Male	V	2	12	Left, 5H, 18D	5	7.55	14.30	6.65	7.58	180	33	83	68	94	-	-	
18	48	Male	V	2	12	Left, 5H, 15D	5	6.48	16.20	4.72	7.06	180	33	72	62	84	-	-	
19	71	Female	V	5	12	Left, 5H, 15D	5	3.24	9.57	4.33	6.01	180	33	80	76	85	+	+	
20	38	Male	III	2	12	Right, 5H, 15D	4	9.06	14.02	6.99	7.25	180	35	97	73	97	+	-	
21	24	Male	III	2	12	Right, 5H, 15D	5	11.08	20.65	6.84	7.02	160	33	92	80	95	+	-	
22	52	Male	III	3	12	Left, 5H, 18D	5	9.93	14.96	9.70	12.31	170	31	85	79	92	+	-	
Average	44.41			3.55	15.50		5.95	7.55	17.69	6.87	8.47	173.18	33.5	90.8	78.6	94.4	13	8	4

CC: coracoclavicular distance, FF: forward flexion, UCLA scores: University of California at Los Angeles scores, ASES scores: American Shoulder and Elbow Surgeons scores, KSS scores: Korean Shoulder Society scores, OA: osteoarthritis, H: hole, D: depth, +: positive, -: negative.  
\*Classification according to the Rockwood type.

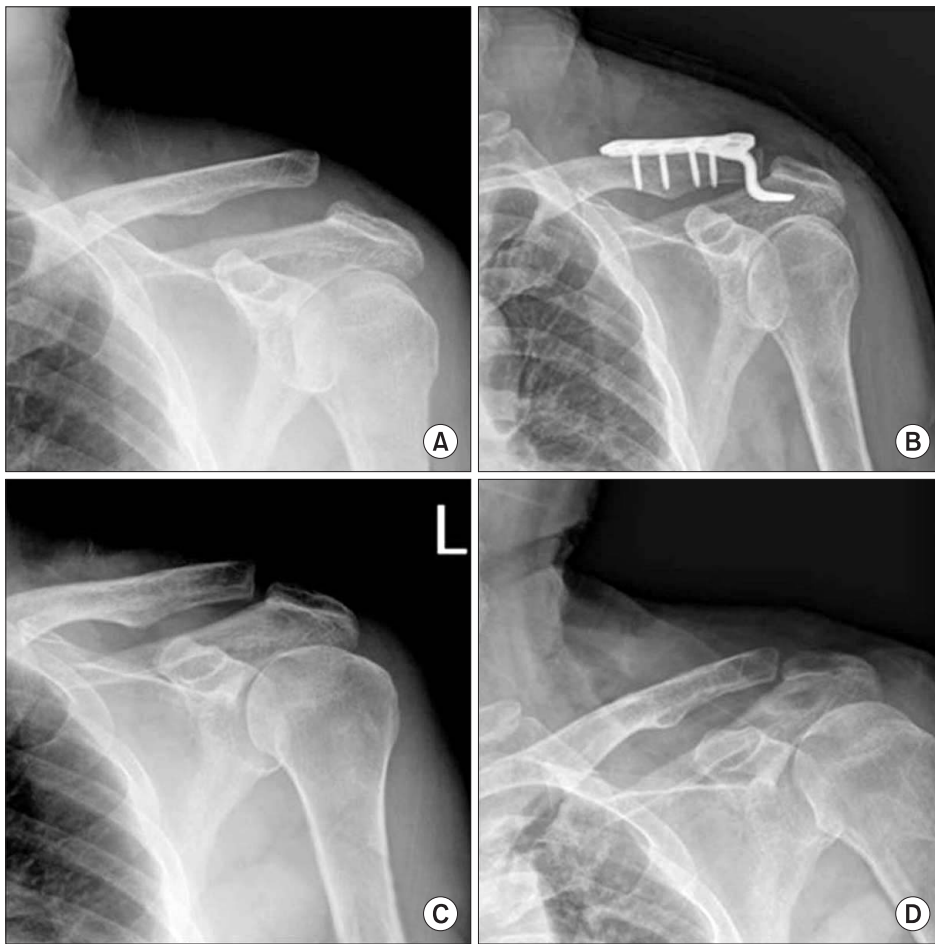


Fig. 1. A 50-year-old male with left shoulder pain due to slip down injury. (A) Initial simple radiograph showing an acromioclavicular joint dislocation (type V). (B) The patient underwent surgery using AO hook locking plate on the third day of injury. (C) The AO hook locking plate was removed at 7 months after the initial surgery. (D) Radiograph taken at 19 months after the initial surgery.

Again, complications were not observed, including plate irritation, and calcification. The removal of the plate was delayed in 2 cases, carried out at 12 months and at 16 months, but symptoms of plate irritation were not observed during clinical visits. However, signs of bone erosion in the lower clavicle were observed during plate removal in 13 cases (59.09%), and at the final follow-up, there were signs of bone erosion in 8 cases (36.36%) and osteoarthritis in 4 cases (18.18%). The patients with signs of bone erosion at the final follow-up had UCLA, ASES, Constant, and KSS scores of on average  $32.63 \pm 1.30$  (31–35),  $90.75 \pm 7.05$  (82–100),  $78.25 \pm 5.90$  (70–85), and  $92.88 \pm 4.97$  (84–99), respectively. Whilst those without signs of bone erosion had scores of  $34.00 \pm 1.04$  (33–35),  $90.86 \pm 9.28$  (72–100),  $78.79 \pm 10.30$  (62–100), and  $95.21 \pm 5.12$  (84–100), respectively. Therefore, there was no statistically significant difference between the two groups.

## Discussion

Plate fixation in acromioclavicular joint injury patients can achieve anatomical reduction in both horizontal and vertical planes.<sup>6)</sup> However, using a plate requires a second surgery to

remove the plate, resulting in an expanded area for surgical incision as well as an increased risk of pain and injury by irritation from the hook.<sup>13)</sup> Using a Wolter plate for the treatment of acromioclavicular joint injury entail an indirect fixation method in which the normal stress is neutralized. This maintains the reduction by indirect fixation, one of the most notable advantages of using plate fixation. However, in 34 cases of acromioclavicular joint dislocation surgery, Ko<sup>14)</sup> found complications including expansion of the hook opening which resulted in pain and fracture of the acromion. Conversely, the use of AO hook locking plates differ from that of Wolter plates in that there is no need to make an opening in the acromion upon which a hook is fixed upon. Because there is no need for such an opening, damage to the normal structure is minimal and the surface area of incision is reduced. Also, there is no direct damage to the acromioclavicular surface and motion is possible between the articular surfaces, so the advantage is that early joint motion exercise is possible after surgery. Further advantages include good vertical stability and low risk of reduction loss or metallic failure, though its disadvantages are that the incision area is large considering the use of suture and wires.<sup>6-8,15-18)</sup> The use of AO hook plates in the treatment of dislocations is simpler and takes less time than

the use of Wolter plates. In fact, Koukakis et al.<sup>19)</sup> have reported that successful treatment of acromioclavicular joint dislocation using AO hook plates is possible even if surgeons are not familiar with such cases, given they are aware of the basics of plate fixation. Henkel et al.<sup>2)</sup> carried out surgery using AO hook locking plates in ligament repair on 19 patients, of which 90% returned to work and resumed normal physical activity. Faraj and Ketzner<sup>8)</sup> carried out surgery using AO hook locking plates and Weaver-Dunn method simultaneously on 9 patients, and reported that all patients showed satisfactory clinical outcomes. Based on these clinical studies, the authors of this study attempted to clinically test the theoretical advantages of using AO hook locking plates. To do this, we studied patients with acute acromioclavicular joint injury who were given surgical treatment using AO hook locking plates. We compared the coracoclavicular distance and looked at 4 different assessment scores during follow-up so that the clinical outcomes are reliable. We saw that during short-term follow-up, there were satisfactory results without any complications.

In the treatment of acromioclavicular joint injury, those categorized into the Rockwood 1 and 2 are given non-surgical treatment involving the use of arm braces, whereas Index 4, 5, 6 patients are given surgical treatment such as open reduction and fixation. For Rockwood 3 patients, Spencer<sup>3)</sup> saw that non-surgical treatment gave satisfactory results, but many other studies have shown that surgical treatment is favored by patients who use much of their muscle, such as the active young, athletes and manual workers.<sup>3,6,7)</sup> The authors of the study treated acromioclavicular joint injury patients with Rockwood 3 and 5, who are also young and active. It is in this context that we attempted to acquire accuracy in the repair of injury during open reduction and fixation using AO hook locking plates.

The complications that may occur in patients after the surgical treatment of acromioclavicular joint injury include redislocation, bone erosion, arthritis, joint ankyloses, infection, inflammation, and so on.<sup>15-17)</sup> De Baets et al.<sup>16)</sup> carried out surgery using hook locking plates on 12 cases of patients, and saw that after 20 months there was satisfactory results. However, all patients had complications of arthritis, so that the author did not hesitate to remove the plate at the specified date in order to limit the possibility of redislocation. In the 4 cases of arthritis in our study, the hook locking plate did not go through the joint, so we believe that the arthritis may be a by-product of physical trauma. Kim et al.<sup>20)</sup> carried out surgery using hook locking plates on 19 cases of acromioclavicular joint injury patients, in which 3 cases of bone erosion occurred. Of these, one case was very severe, and the plate was removed because fracture was suspected. Choi et al.<sup>21)</sup> compared the use of Wolter plates and AO hook locking plates in the correction of acromioclavicular joint dislocation in 32 patients. Of these, bone erosion occurred in 7 patients due

to irritation from the hook. Additionally, Kim et al.<sup>22)</sup> carried out surgery using hook locking plates in distal clavicular fractures in 12 patients. Of these, signs of bone erosion were seen in 3 cases but these symptoms improved in the final follow-up as assessed by radiography. In our study, there were 13 cases showing signs of low-density bone erosion in the acromioclavicular joint according to radiographic assessment, and 8 cases still showed signs of bone erosion in the final follow-up. The authors believe that bone erosion may have occurred by the irritation from the hook. Accordingly, the authors saw some cases of improvement in bone erosion after the removal of the plate. However, additional prospective study is required to fully understand. Generally, the period of plate removal is recommended between 8 to 12 weeks after surgery. If the plate is removed too early, there is risk of redislocation, and if it is removed later, there is increased risk of arthritis and symptoms related to plate irritation. Therefore, the authors decided on a principle of removing the plate at 4 months after surgery. We saw no complications of plate irritation or calcification, but 4 cases of osteoarthritis was observed. After the removal of the plate, the coracoclavicular distance had increased from an average of 6.87 to 8.47 at the final follow-up. However, it is still a significant improvement from pre-surgery levels and clinical assessments also showed improvement. Whether there is on-going loss to the distance requires further successive follow-up.

The clinical assessment of the outcome of the shoulder joint surgery was achieved using a combination of assessment systems. The authors realized the difficulty of making comparisons with results of other studies, which is why as many assessment tools possible were used on all patients to assess the clinical outcome of the surgery of the acromioclavicular joint injury. In this way, the reliability of the assessment was also heightened.

In our study, the authors used AO hook locking plates to treat acute acromioclavicular joint injuries and obtained satisfactory results. However, the limitations of our study are that our observations are short-term, based on more than one criteria and has a small number of patients. And so, further follow-up is being carried out at present, and the need for further study involving more patients as well as comparison of other surgery methods is acknowledged.

## Conclusion

The surgical treatment of acute acromioclavicular joint injury using AO hook locking plates resulted in good clinical outcomes during short-term follow-up, achieving the reduction of the joint, whilst maintaining safety. Furthermore, radiological assessment showed satisfactory outcomes, further indicating its usefulness as a relatively simple and useful surgical treatment.

## References

1. Salem KH, Schmelz A. Treatment of Tossy III acromioclavicular joint injuries using hook plates and ligament suture. *J Orthop Trauma*. 2009;23(8):565-9.
2. Henkel T, Oetiker R, Hackenbruch W. Treatment of fresh Tossy III acromioclavicular joint dislocation by ligament suture and temporary fixation with the clavicular hooked plate. *Swiss Surg*. 1997;3(4):160-6.
3. Spencer EE Jr. Treatment of grade III acromioclavicular joint injuries: a systematic review. *Clin Orthop Relat Res*. 2007;455:38-44.
4. Tossy JD, Mead NC, Sigmond HM. Acromioclavicular separations: useful and practical classification for treatment. *Clin Orthop Relat Res*. 1963;28:111-9.
5. Harris RI, Wallace AL, Harper GD, Goldberg JA, Sonnabend DH, Walsh WR. Structural properties of the intact and the reconstructed coracoclavicular ligament complex. *Am J Sports Med*. 2000;28(1):103-8.
6. Sim E, Schwarz N, Höcker K, Berzlanovich A. Repair of complete acromioclavicular separations using the acromioclavicular-hook plate. *Clin Orthop Relat Res*. 1995;(314):134-42.
7. Folwaczny EK, Yakisan D, Stürmer KM. The Balsler plate with ligament suture. A dependable method of stabilizing the acromioclavicular joint. *Unfallchirurg*. 2000;103(9):731-40.
8. Faraj AA, Ketzer B. The use of a hook-plate in the management of acromioclavicular injuries. Report of ten cases. *Acta Orthop Belg*. 2001;67(5):448-51.
9. Balsler D. Eine neue Methode zur operativen Behandlung der akromioklavikulären Luxation. *Chir Prax*. 1976;24:275.
10. Dittel KK, Pfaff G, Metzger H. Results of treatment following surgical management of complete acromioclavicular joint dislocation (Tossy III injury). Management using ligament sutures and direct transarticular and indirect extra-articular stabilization. *Aktuelle Traumatol*. 1987;17(1):16-22.
11. Schmittinger K, Sikorski A. Experiences with the Balsler plate in dislocations of the acromioclavicular joint and lateral fractures of the clavicle. *Aktuelle Traumatol*. 1983;13(5):190-3.
12. Wolter D, Eggers C. Reposition and fixation of acromioclavicular luxation using a hooked plate *Hefte Unfallheilkd*. 1984;170:80-6.
13. Haberneek H, Weinstabl R, Schmid L, Fialka C. A crook plate for treatment of acromioclavicular joint separation: indication, technique, and results after one year. *J Trauma*. 1993;35(6):893-901.
14. Ko SH. Minimal incision Wolter plate fixation on the displaced lateral end fracture of the clavicle and the acromioclavicular dislocation. *J Korean Shoulder Elb Soc*. 2002;5(1):23-8.
15. Broos P, Stoffelen D, Van de Sijpe K, Fourneau I. Surgical management of complete Tossy III acromioclavicular joint dislocation with the Bosworth screw or the Wolter plate. A critical evaluation. *Unfallchirurgie*. 1997;23(4):153-9; discussion 160.
16. De Baets T, Truijen J, Driesen R, Pittevels T. The treatment of acromioclavicular joint dislocation Tossy grade III with a clavicle hook plate. *Acta Orthop Belg*. 2004;70(6):515-9.
17. Eberle C, Fodor P, Metzger U. Hook plate (so-called Balsler plate) or tension banding with the Bosworth screw in complete acromioclavicular dislocation and clavicular fracture. *Z Unfallchir Versicherungsmed*. 1992;85(3):134-9.
18. Graupe F, Dauer U, Eysel M. Late results of surgical treatment of Tossy III acromioclavicular joint separation with the Balsler plate *Unfallchirurg*. 1995;98(8):422-6.
19. Koukakis A, Manouras A, Apostolou CD, et al. Results using the AO hook plate for dislocations of the acromioclavicular joint. *Expert Rev Med Devices*. 2008;5(5):567-72.
20. Kim MH, Seo JB, Moon SY. Treatment of acromioclavicular joint injuries using clavicle hook plates. *J Korean Shoulder Elb Soc*. 2010;13(1):92-8.
21. Choi JY, Kim E, Jeong HJ, et al. Clinical comparison of two types of hook plate in surgical treatment of acromioclavicular dislocation - AO hook plate and Wolter plate. *Clin Shoulder Elb*. 2012;15(2):123-9.
22. Kim YS, Lee HM, Jang HG. Surgical treatment of unstable distal clavicle fractures: comparison of transacromial pin fixation and hook plate fixation. *Clin Shoulder Elb*. 2013;16(2):123-9.