CiSE

Clinics in Shoulder and Elbow

Volume
25

Number
4

Decemebr
2022

eISSN : 2288-8721

www.cisejournal.org

www.cisejournal.org

eISSN 2288-8721

CiSE
Clinics in Shoulder and Elbow

Volume 25 • Number 4 • December 2022

Aims and Scope

Clinics in Shoulder and Elbow (Clin Shoulder Elbow, CiSE; eISSN: 2288-8721;pISSN: 2383-8337 till 2018) is the official journal of the Korean Shoulder and Elbow Society. The *Clinics in Shoulder and elbow* was first launched in 1998 and was formerly known as the Journal of the Korean Shoulder and Elbow Society until June 2010 (volume 13). It was published semiannually until 2013 and has been published quarterly on the first day of March, June, September, and December since 2014. Articles have been published in English only since 2014, and the journal has been published online only since 2019.

It aims: first, to contribute to the management and education of shoulder and elbow topics; second, to share the latest scientific information among international societies; and finally, to promote communications on shoulder/elbow problems and patient care.

Its scope includes basic and clinical research, focusing on the etiology and epidemiology, biomechanics and pathogenesis, management and surgery, complication and prognosis for the disease of shoulder and elbow. Its regional scope is mainly Asia but it welcomes submissions from researchers all over the world.

Its main publication types are original articles, case reports, invited review articles, editorials, and letters to the editor. Other types are negotiable also with editor-in-chief. All submissions are processed online. The editior-in-chief determines the fate of the submitted manuscripts after hearing from peer reviewers, who are experts in their specific fields of shoulder and elbow.

Articles published in this journal can be obtained freely from the official website of the journal. (https://www.cisejournal.org) including contents, abstracts, and full-text PDF files according to the Creative Commons license (CC-BY-NC).

Clinics in Shoulder and Elbow is indexed/tracked/covered by PubMed, PubMed Central (PMC), Korea Citation Index (KCI), KoreaMed, KoMCI, CrossRef, and Google Scholar.

For subscription, submission, or any other information, please contact the editorial office below.

Open Access

Publisher Korean Shoulder and Elbow Society
Editor-In-Chief Hyung Bin Park

Editorial office
Korean Shoulder and Elbow Society
#6603, 101 Daehak-ro, Jongno-gu, Seoul 03080, Korea
Tel: +82-2-3410-1854 Fax: +82-2-3410-0061 E-mail: journal@cisejournal.org

Printing office
M2PI
8th FL, DreamTower, 66 Seongsui-ro, Seongdong-gu, Seoul 04784, Korea
Tel: +82-2-6966-4930 Fax: +82-2-6966-4945 E-mail: support@m2-pi.com

Published on December 1, 2022

∞ This paper meets the requirements of KS X ISO 9706, ISO 9706-1994 and ANSI/NISO Z39. 48-1992 (Permanence of paper)

eISSN 2288-8721

CiSE
Clinics in Shoulder and Elbow

Editorial Board

eISSN 2288-8721

CiSE
Clinics in Shoulder and Elbow

Contents

Volume 25 · Number 4 · December 2022

Editorial

Original Articles

eISSN 2288-8721

CiSE
Clinics in Shoulder and Elbow

Contents

Volume 25 · Number 4 · December 2022

Editorial

Clin Shoulder Elbow 2022;25(4):255-256
https://doi.org/10.5397/cise.2022.01340

CiSE
Clinics in Shoulder and Elbow

eISSN 2288-8721

Arm position and deforming muscular forces in proximal humeral fracture

Yong-Min Chun

Department of Orthopedic Surgery, Arthroscopy and Joint Research Institute, Severance Hospital, Yonsei University College of Medicine, Seoul, Korea

Proximal humerus fracture account for 5%–6% of all fractures, and represent one of most common fractures in elderly patients [1,2]. Fortunately, in many cases, they are non-displaced or minimally displaced, and exhibit good outcomes overall with conservative treatment [2,3]. Nonetheless, many of the tendons and muscles around the proximal humerus, including rotator cuff, can work as deforming forces on the proximal humerus, which consists of the articular surface of humeral head, greater tuberosity, lesser tuberosity, and shaft. Thus, fracture patterns can be predicted based on the muscle or tendon insertion, such as supraspinatus, infraspinatus, subscapularis, and pectoralis major. Therefore, management to reduce or minimize these deforming forces is necessary during conservative treatment or during the postoperative period.

A study by Chalmers et al. [4] discussed these deforming forces in proximal humerus fracture depending on arm position, using fresh-frozen cadaveric shoulder specimens. They hypothesized that glenohumeral abduction would mitigate varus deformity driven by the supraspinatus, and internal rotation would mitigate varus deformity by the subscapularis, respectively. Medial wedge osteotomy was performed to simulate a surgical neck fracture. Specimens were mounted on a custom shoulder test system for testing. As varus deformity or progress is not uncommon during conservative treatment or after surgical fixation, the authors focused on varus deformity. At 0° and 20° glenohumeral abduction and internal rotation, changes in varus were measured following physiologic muscle loading. The authors concluded that shoulder abduction and internal rotation can reduce varus-driven force in surgical neck fracture by decreasing tension from the supraspinatus and subscapularis tendon and muscle. Thus, they recommended use of a sling placing the shoulder in this position.

To mitigate varus deforming force in a sling, abduction and internal rotation seem to be reasonable [4]. However, in terms of tension around proximal humerus fractures, we also feel the tension caused by pectoralis major abduction is a concern, especially in skinny and small persons. In addition, if proximal humerus fracture involves the greater tuberosity, internal rotation can increase the tension of external rotators such as the infraspinatus, leading to displacement.

Thus, in proximal humerus fracture, it is necessary to consider all components, including muscle and tendon insertion. Arm position in any brace or sling during initial conservative treatment or after surgery should seek to decrease the tension on each fracture component and the inserting muscle or tendon.

Received: November 2, 2022 Accepted: November 11, 2022
Correspondence to: Yong-Min Chun
Department of Orthopedic Surgery, Arthroscopy and Joint Research Institute, Severance Hospital, Yonsei University College of Medicine, 50-1 Yonsei-ro, Seodaemun-gu, Seoul 03722, Korea
Tel: +82-2-2228-5679, Fax: +82-2-363-6248, E-mail: osmin120@yuhs.ac, ORCID: https://orcid.org/0000-0002-8147-6136

Financial support: None.
Conflict of interest: None.

ORCID

Yong-Min Chun https://orcid.org/0000-0002-8147-6136

REFERENCES

1. Court-Brown CM, Garg A, McQueen MM. The epidemiology of proximal humeral fractures. Acta Orthop Scand 2001;72:365-71.
2. Patel AH, Wilder JH, Ofa SA, Lee OC, Savoie FH 3rd, O'Brien MJ, et al. Trending a decade of proximal humerus fracture management in older adults. JSES Int 2021;6:137-43.
3. McLean AS, Price N, Graves S, Hatton A, Taylor FJ. Nationwide trends in management of proximal humeral fractures: an analysis of 77,966 cases from 2008 to 2017. J Shoulder Elbow Surg 2019;28:2072-8.
4. Chalmers CE, Wright DJ, Patel N, Hitchens H, McGarry M, Lee TQ, et al. Muscular forces responsible for proximal humeral deformity after fracture. J Orthop Trauma 2022;36:e18-23.

https://doi.org/10.5397/cise.2022.01340

Original Article

Clin Shoulder Elbow 2022;25(4):257-264
https://doi.org/10.5397/cise.2021.00710

CiSE
Clinics in Shoulder and Elbow

eISSN 2288-8721

Risk factors of chronic subscapularis tendon tear

Hyung Bin Park[1,2], Ji Yong Gwark[1], Jae-Boem Na[3]

[1]*Department of Orthopaedic Surgery, Gyeongsang National University School of Medicine and Gyeongsang National University Changwon Hospital, Changwon, Korea*
[2]*Gyeongsang Institute of Health Sciences, Gyeongsang National University, Jinju, Korea*
[3]*Department of Radiology, Gyeongsang National University School of Medicine and Gyeongsang National University Hospital, Jinju, Korea*

Background: Chronic subscapularis tendon tear (SBT) is a degenerative disease and a common pathologic cause of shoulder pain. Several potential risk factors for chronic SBT have been reported. Although metabolic abnormalities are common risk factors for degenerative disease, their potential etiological roles in chronic SBT remains unclear. The purpose of this study was to investigate potential risk factors for chronic SBT, with particular attention to metabolic factors.
Methods: This study evaluated single shoulders of 939 rural residents. Each subject undertook a questionnaire, physical examinations, blood tests, and simple radiographs and magnetic resonance imaging (MRI) evaluations of bilateral shoulders. Subscapularis tendon integrity was determined by MRI findings based on the thickness of the involved tendons. The association strengths of demographic, physical, social, and radiologic factors, comorbidities, severity of rotator cuff tear (RCT), and serologic parameters for SBT were evaluated using logistic regression analyses. The significance of those analyses was set at $p<0.05$.
Results: The prevalence of SBT was 32.2% (302/939). The prevalence of partial- and full-thickness tears was 23.5% (221/939) and 8.6% (81/939), respectively. The prevalence of isolated SBT was 20.2% (190/939), SBT combined with supraspinatus or infraspinatus tendon tear was 11.9% (112/939). In multivariable logistic regression analysis, dominant side involvement ($p<0.001$), manual labor ($p=0.002$), diabetes ($p<0.001$), metabolic syndrome ($p<0.001$), retraction degree of Patte tendon ($p<0.001$), posterosuperior RCT ($p=0.010$), and biceps tendon injury ($p<0.001$) were significantly associated with SBT.
Conclusions: Metabolic syndrome is a potential risk factor for SBT, as are these factors: overuse activity, diabetes, posterosuperior RCT, increased retraction of posterosuperior rotator cuff tendon, and biceps tendon injury.

Keywords: Subscapularis tendon tears; Prevalence; Risk factors; Metabolic syndrome

INTRODUCTION

The function of the subscapularis muscle and the integrity of the subscapularis tendon are of great importance to shoulder function. Providing approximately 50% of rotator cuff force, the subscapularis is the largest and most powerful of the rotator cuff muscles and its importance in arm elevation outweighs that of both the supraspinatus and infraspinatus [1,2]. Since 1934, when Codman stated that the subscapularis accounted for merely 3.5% of 200 rotator cuff tears (RCTs), the prevalence of subscapularis

Received: December 1, 2021 Revised: May 12, 2022 Accepted: May 12, 2022
Correspondence to: Hyung Bin Park
Department of Orthopaedic Surgery, Gyeongsang National University Changwon Hospital, 11 Samjeongja-ro, Seongsan-gu, Changwon 51472, Korea
Tel: +82-55-214-3820, Fax: +82-55-214-3259, E-mail: hbinpark@gnu.ac.kr, ORCID: https://orcid.org/0000-0001-9468-6282

Financial support: A grant from the Farmers' Musculoskeletal Disease Investigation of the Korean Rural Development Administration supported this work.
Conflict of interest: None.

tendon tear (SBT) has been considered to be much lower than that of supraspinatus tendon tear [3]. An magnetic resonance imaging (MRI) study of 2,167 patients with RCTs revealed a low prevalence of SBT at 2%, of which partial and full-thickness tears accounted for 27% and 73%, respectively [4]. In contrast, several reports have shown the prevalence of SBT to be as high as 30% in all arthroscopic shoulder surgeries and up to 49.4% in arthroscopic rotator cuff procedures [5-7]. To the best of our knowledge, there are no available reports regarding SBT prevalence in non-hospitalized populations.

Chronic SBT is a common pathologic cause of shoulder pain. However, the etiology of chronic SBT remains incompletely understood. Several previous studies that focused mostly on anatomical or radiological parameters have investigated potential SBT risk factors, including subcoracoid stenosis [8], coracoid process morphology (coracoid angle and coracoid distal length) and greater humeral version [9], coracohumeral distance and coracoid overlap [10,11], subscapularis tendon slip number [11], lesser tuberosity cyst [12], coracohumeral index and coracoglenoid inclination [13], and the size of posterosuperior RCT (PS-RCT) and long head of biceps tendon (LHBT) tear [14]. Several metabolic abnormalities or factors, including diabetes or hyperglycemia, dyslipidemia, and metabolic syndrome, have been reported as risk factors for tendinopathy. However, studies investigating the specific association of chronic SBT with metabolic factors, which are known risk factors for degenerative diseases, are lacking. We hypothesized that metabolic factors are associated with chronic SBT; therefore, the purpose of this study was to investigate potential risk factors for chronic SBT, with particular attention to metabolic factors.

METHODS

This study was approved by the Institutional Review Board of Gyeongsang National University Hospital (No. GNUH 2015-02-001). Informed consent was obtained from the volunteers included in this study.

Study Design

A survey of upper extremity morbidity was conducted with support from public health officers. The study cohort was comprised of 1,149 uncompensated volunteers from the studied rural region. One of those recruited volunteers had an amputated shoulder; therefore, 2,297 shoulders were included in the study cohort. Of these volunteers, study subjects were enrolled according to the following inclusion and exclusion criteria. The inclusion criteria were the completion of a written consent and of a questionnaire, physical examinations, fasting blood tests, and simple radiographs (true anteroposterior, axillary lateral, and outlet views) and MRI evaluations of bilateral shoulders. The exclusion criteria were a lack of participation in shoulder MRI studies (n = 17), a relevant history of trauma (n = 26), previous shoulder surgery (n = 13), glenohumeral joint osteoarthritis (n = 12), calcific tendinitis (n = 15), frozen shoulder (n = 9), and/or use of medications that could affect serum lipid profiles (n = 118). After exclusion, a total of 939 enrolled subjects, of whom 462 were male and 477 were female with a mean age of 59.2 ± 8.4 years, were included in the study. Because several non-systemic variables are shoulder-related factors that would not affect both bilateral shoulders similarly, only one shoulder per subject was included in the analysis as the studied side to evaluate the strength of associations among variables. For subjects with either bilateral SBT or no SBT, one shoulder was randomly included (using random number generation by Excel). For each subject with unilateral SBT, only the involved shoulder was included as the studied side (Fig. 1).

MRIs were performed using a 1.5-T scanner (Siemens Medical Systems, Erlangen, Germany). Four sequences, each with a slice thickness of 3 mm, a field of view from 15.9 to 18.0 cm, and one excitation, were obtained as follows: (1) oblique sagittal T1-weighted spin echo, (2) oblique sagittal T2-weighted turbo-spin-echo (TSE) with fat saturation, (3) oblique coronal T2-weighted TSE with fat saturation, and (4) axial T2-weighted TSE with fat saturation. All MRIs were interpreted by one experienced musculo-



Fig. 1. Flowchart for inclusion and exclusion criteria for this study. All 939 subjects met the authors' inclusion and exclusion criteria. MRI: magnetic resonance imaging.

https://doi.org/10.5397/cise.2021.00710

skeletal radiologist who was blind to the clinical findings (JBN). Full thickness RCTs were diagnosed based on a discontinuity or gap in the tendon or an increased signal intensity on T2-weighted images, extending from the articular to the bursal surfaces. Partial thickness RCTs were diagnosed based on partial high intensity in the rotator cuff tendon or on a slight increase in signal intensity in the cuff tendon, without a definite defect on either the intra-articular or the bursal side. Biceps tendon injuries were determined by MRI, then classified as partial or complete tear, or subluxation. Partial biceps tendon tear was identified by increased intra-tendinous T2-weighted signal intensity. A complete tear was identified by absence of the LHBT intra-articularly or within the bicipital groove. Subluxation was identified by displacement of the LHBT from the bicipital groove [15].

The studied variables were as follows. The demographic or general physical factors included age, sex, waist circumference, and dominant side involvement. The social factors included tobacco smoking, alcohol use, and manual labor and the comorbidities included diabetes, hypertension, metabolic syndrome, and dyslipidemia. Previous diagnoses of diabetes and hypertension were accepted. New diagnoses were made during the study using current standards for blood test and blood pressure findings as follows: diabetes, by serum levels of glycated hemoglobin (HbA1c) ≥6.5% or of fasting glucose ≥126 mg/dL [16] and hypertension, by blood pressure >140 mmHg in systolic or >90 mmHg in diastolic [17]. Clinical identification of metabolic syndrome involved meeting at least three of these five criteria: (1) fasting plasma glucose level ≥100 mg/dL or use of antidiabetic medication, (2) systolic blood pressure ≥130 mmHg or diastolic blood pressure ≥85 mmHg, or use of antihypertensive medication, (3) serum triglyceride (TG) level ≥150 mg/dL, (4) serum high-density lipoprotein (HDL) level <40 mg/dL for men or <50 mg/dL for women, and (5) waist circumference ≥90 cm for men or ≥85 cm for women [18,19]. The serological factors were cholesterol, TG, low-density lipoprotein (LDL), HDL, non-HDL (non-HDL), and TG/HDL ≥3.5. Dyslipidemia was determined, using these criteria: hypercholesterolemia (total cholesterol ≥200 mg/dL), hyper-LDLemia (LDL ≥100 mg/dL), hyper-TGmia (TG ≥150 mg/dL), hypo-HDLemia (HDL <40 mg/dL for men and <50 mg/dL for women), and hyper-non-HDLemia (non-HDL ≥130 mg/dL) [20].

Factors related to tear chronicity detected on MRI were Patte retraction degree [21], global fatty degeneration index [22], Goutallier grade of infraspinatus [23], tangent sign [24], and occupation ratio [25]. The radiographic factor was superior displacement of the humeral head [26]. The factors related to tendon involvement were posterosuperior cuff tear and biceps tendon injury. These factors and their prevalence are summarized in Table 1.

Data Analysis

The prevalence and 95% confidence intervals (CIs) of SBTs were analyzed. Using univariate logistic regression analyses, the odds ratios and 95% CIs were calculated to identify any association between SBT and the studied variables. Then, multivariable logistic regression analyses, using only the significant variables identified in the univariate analyses, were performed. Multivariable logistic regression analysis was performed after assessment of multicollinearity using factors with both a variance inflation factor and a condition index <10, indicating no multicollinearity [27]. The goodness of fit for a multivariable logistic regression model was determined using the Hosmer-Lemeshow test. All statistical analyses were performed using the IBM SPSS ver. 24.0 (IBM Corp., Armonk, NY, USA). The significance of the logistic regression analyses and the Hosmer-Lemeshow test were set at $p<0.05$.

RESULTS

The prevalence of SBT among enrolled subjects was 32.2% (302/939); among subjects with overall RCT, it was 74.6% (302/405). The prevalence of SBT when isolated, when combined with PSRCT, and in relation to tear thicknesses is summarized in Table 2. In univariate analyses, age, male sex, dominant side involvement, manual labor, diabetes, metabolic syndrome, TG/HDL ≥3.5, Patte retraction degree, global fatty degeneration index, Goutallier grade, occupation ratio, PSRCT, and biceps tendon injury were significantly associated with SBT ($p \leq 0.006$) (Table 3).

In multivariable analysis, dominant side involvement, manual labor, diabetes, metabolic syndrome, Patte retraction degree, PSRCT, and biceps tendon injury were significantly associated with SBT ($p \leq 0.041$) (Table 4). The p-value of the Hosmer-Lemeshow test was 0.427, indicating a good fit.

DISCUSSION

A notable finding of this study is that metabolic syndrome is a significantly associated factor for SBT, as are the following previously-reported significantly associated factors: dominant side involvement, manual labor, diabetes, Patte retraction degree, PSRCT, and biceps tendon injury. Metabolic syndrome is a well-known risk factor for various degenerative diseases, among which are cardiovascular disease, stroke, diabetes, osteoarthritis,

Table 1. The summary of demographic data, prevalence, mean or median for each of studied variables

Characteristics	Subscapularis tendon tear group (n = 302)	Subscapularis tendon intact group (n = 637)
Age (yr)	60.53 ± 8.43	58.63 ± 8.30
Male	174 (57.6)	288 (45.2)
Waist circumference (cm)	84.82 ± 8.80	83.94 ± 8.39
Dominant side involvement	172 (57.0)	266 (41.8)
Smoking	119 (39.4)	242 (38.0)
Alcohol	201 (66.6)	417 (65.5)
Manual labor	228 (75.5)	424 (66.6)
Diabetes	78 (25.8)	91 (14.3)
Hypertension	73 (24.2)	147 (23.1)
Metabolic syndrome	138 (45.7)	178 (27.9)
Serum lipid level (mg/dL)		
Cholesterol	191.5 ± 33.2	195.7 ± 32.3
TG	109 (81–150)	107 (79–148)
LDL	133.10 ± 28.7	131.8 ± 31.1
HDL	54.0 (45.0–62.0)	56.0 (46.0–66.0)
Non-HDL	145.1 ± 30.5	141.3 ± 28.9
Prevalence of dyslipidemia		
Hyper-cholesterolemia	138 (45.7)	263 (41.3)
Hyper-TGmia	109 (36.1)	181 (28.4)
Hyper-LDLemia	246 (81.5)	505 (79.3)
Hypo-HDLemia	83 (27.5)	167 (26.2)
Hyper-non-HDLemia	195 (64.6)	398 (62.5)
TG/HDL ≥ 3.5	88 (29.1)	126 (19.8)
Patte grade	1.1 ± 1.0	0.7 ± 1.1
Global fatty degeneration index	0.33 (0.33–0.66)	0.33 (0.33–0.66)
Goutallier grade	1.00 (0.00–1.10)	1.00 (0.00–1.00)
Tangent sign	48 (15.9)	87 (13.7)
Occupation ratio grade	0.00 (0.00–0.00)	0.00 (0.00–0.00)
Superior displacement of humeral head	48 (15.9)	90 (14.1)
Posterosuperior cuff tear	135 (44.7)	167 (26.2)
Biceps injury	101 (33.4)	106 (16.6)

Values are presented as mean ± standard deviation, number (%), or median (interquartile range).
TG: triglyceride, LDL: low-density lipoprotein, HDL: high-density lipoprotein.

Table 2. Prevalences of SBT among enrolled subjects

Prevalence	Enrolled subject (n = 939)	95% CI
SBT	32.2 (302/939)	32.17–32.23
Partial-thickness SBT	23.5 (221/939)	23.47–23.53
Full-thickness SBT	8.6 (81/939)	8.58–8.62
Isolated SBT	20.2 (190/939)	20.17–20.23
SBT with PSRCT	11.9 (112/939)	11.88–11.92
Among SBT subjects (n = 302)		
Partial-thickness SBT	73.2 (221/302)	73.17–73.23
Full-thickness SBT	26.8 (81/302)	26.77–26.83
Isolated SBT	62.9 (190/302)	62.86–62.93
SBT with PSRCT	37.1 (112/302)	37.07–37.12
Among over all RCT subjects (n = 405)		
SBT	74.6 (302/405)	73.57–74.63

Values are presented as percent (number).
SBT: subscapularis tendon tear, CI: confidence interval, PSRCT: posterosuperior rotator cuff tear, RCT: rotator cuff tear.

https://doi.org/10.5397/cise.2021.00710

Table 3. Factors significantly associated with subscapularis tendon tear in univariate analyses

Studied variable	Odds ratio (95% CI)	p-value
Age (yr)	1.03 (1.01–1.05)	0.001
Male	1.65 (1.25–2.17)	< 0.001
Dominant side involvement	1.85 (1.40–2.43)	< 0.001
Manual labor	1.55 (1.14–2.11)	0.006
Diabetes	2.09 (1.49–2.94)	< 0.001
Metabolic syndrome	2.17 (1.63–2.89)	< 0.001
TG/HDL ≥ 3.5	1.67 (1.22–2.29)	0.001
Retraction degree of Patte	2.55 (1.91–3.39)	< 0.001
Global fatty degeneration index	2.01 (1.36–2.96)	< 0.001
Goutallier grade	1.32 (1.05–1.68)	0.020
Occupation ratio	1.70 (1.07–2.72)	0.025
Posterosuperior RCT	2.28 (1.71–3.03)	< 0.001
Biceps tendon injury	2.52 (1.83–3.46)	< 0.001

CI: confidence interval, TG: triglyceride, HDL: high-density lipoprotein, RCT: rotator cuff tear.

Table 4. Factors significantly associated with subscapularis tendon tear in multivariable analysis

Studied variable	Odds ratio (95% CI)	p-value
Dominant side involvement	2.00 (1.45–2.76)	< 0.001
Manual labor	1.75 (1.24–2.48)	0.002
Diabetes	2.80 (1.90–4.12)	< 0.001
Metabolic syndrome	2.05 (1.50–2.84)	< 0.001
Retraction degree of Patte	2.03 (1.48–2.83)	< 0.001
Posterosuperior RCT	1.67 (1.15–2.71)	0.010
Biceps tendon injury	2.12 (1.36–2.93)	< 0.001
Hosmer-Lemeshow test	-	0.427

CI: confidence interval, RCT: rotator cuff tear.

and Achilles enthesopathy [28-30]. Metabolic syndrome has also been reported as significantly associated with PSRCT [31]. The current study found, by multivariable analysis and after adjustment for the PSRCT variable, that metabolic syndrome is an independently associated factor for chronic SBT. This finding suggests that the degenerative effect of metabolic syndrome, evident on PSRCT and other tendon tears, also heightens the risk of SBT [30,31]. This finding strongly suggests that metabolic syndrome is a risk factor for SBT. The molecular mechanism and the pathophysiology of that association have not been determined; therefore, future research is needed to clarify the underlying molecular mechanisms and the effect of metabolic syndrome on subscapularis tendon degeneration or tendinopathy.

The prevalence of SBT was found by one cadaveric study to be 37% and also found that all tears were articular side partial tears [32]. According to studies based on arthroscopic findings, the prevalence of SBT was from 27% to 49.4% in all shoulder arthroscopy recipients [5,7]. Several previous studies have reported that SBT was frequently associated with PSRCT [33,34]. One study reported that intra-articular partial SBT was detected in 19% of patients who had arthroscopy and that SBT was significantly associated with supraspinatus and infraspinatus tendon tears [35]. One MRI study of patients visiting a hospital reported about 80% of the SBTs as being combined with PSRCT [4]. In the current study, SBT was significantly associated with PSRCT; the prevalence of SBT in overall RCT was 74.6%. The current study confirmed previous findings that SBT is frequently associated with PSRCT.

The current study found dominant-side involvement to be a significantly associated factor of SBT. Most previous relevant studies reported the greater prevalence of RCT on the dominant side [31,36]. No relation between hand dominance and SBT was found by Mehta et al. [37]; however, the study design differed from that of the present study by including asymptomatic SBT patients. In the present study, which included subjects with either symptomatic or asymptomatic SBT, the involvement of the dominant side was identified as a risk factor for SBT, similar to its role in PSRCT [31]. In addition, manual labor was significantly associated with SBT in the present study. Previous epidemiologic studies indicated high prevalence of RCT among manual laborers, including agricultural workers. Some previous biomechanical studies suggested that manual labor activities, including sustained or repeated arm abduction, heavy lifting or carrying, high task repetitiveness, and physical exertion, are associated with PSRCT [38]. Findings in this study suggest that repetitive manual activity or overuse are a common cause of tendon degeneration and are involved in the development of SBT, similarly as in PSRCT.

The main finding of this study that diabetes is strongly associated with SBT is consistent with the findings of several previous studies that noted diabetes as a risk factor for RCT and for retear after rotator cuff repair [39,40]. One previous study reported a significant association between hyperglycemia and Achilles tendon tendinopathy and found insulin resistance, an aspect of metabolic syndrome, to be a risk factor for tendinopathy [41]. According to another report, even plasma glucose levels at the high end of the normal range may be a risk factor for RCT [42]. On the molecular level, hyperglycemia induces oxidative stress and cytokine production, which lead to inflammation and result in damage to various tissues [43]. Hyperglycemia alters collagen structure through a glycation process, and it also reduces proteoglycan levels through decreased synthesis or sulfation of glycosaminoglycans [44,45]. These molecular mechanisms may affect tendon degeneration, including SBT. Results of the current study

are consistent with and support the findings of previous studies regarding the association of diabetes with tendinopathy or tendon tear.

In this study, Patte retraction degree was significantly associated with SBT. The retraction degree has been reported to be significantly associated with supraspinatus muscle atrophy, which could explain the tear severity and/or tear chronicity of supraspinatus tear that is associated with SBT [46]. Mehta et al. [37] reported that SBT and LHBT pathology are significantly related to the size of the PSRCT. The results from this study confirm those of previous studies and they support the finding that chronic PSRCT is a potential risk factor for SBT.

Several studies reported that lesions of the LHBT are significantly associated with SBT [7,32,47]. Chen et al. [48] reported that 97% of RCTs with subscapularis tendon involvement are combined with LHBT lesions. Several MR studies have reported that medial subluxation or dislocation of the LHBT is associated with SBT [47,49]. Hidden biceps tendon instability has also been reported as a factor associated with SBT [50]. One study reported a sentinel sign, in which biceps tendon scuffing, abrasion, or partial tear of the anterior portion can serve as a warning to clinicians about the presence of SBT [51]. The present study confirms the results of previous studies that found that SBT is significantly associated with biceps long head lesions.

This cross-sectional study has some limitations. Subjects included volunteers only, and they may not have been representative of the entire local population. Agricultural workers made up a major portion of this cohort, and their characteristics may not be generalizable to other populations in other locations. This study did not evaluate differences in ethnic backgrounds, family histories, educational attainments, or activity levels. SBT and biceps tendon injury were diagnosed by 1.5-T MRI, which has been reported to have less diagnostic accuracy than arthroscopy or 3.0-T MRI [14,52]. To minimize the compound variable effect, subjects being medicated with any lipid-lowering drug were excluded, which might affect the study results through reduction of the sample size. However, because supplemental analyses conducted without that exclusion yielded similar results, the exclusion potential for bias is likely to be small and acceptable (Supplementary Table 1). Metabolic syndrome is a potential risk factor for SBT, as are these factors: overuse, diabetes, PSRCT, increased retraction of posterosuperior rotator cuff tendon, and biceps tendon injury.

ORCID

Hyung Bin Park https://orcid.org/0000-0001-9468-6282
Ji Yong Gwark https://orcid.org/0000-0002-2554-0850
Jae-Boem Na https://orcid.org/0000-0002-6182-2986

SUPPLEMENTARY MATERIALS

Supplementary materials can be found via https://doi.org/10.5397/cise.2021.00710.

REFERENCES

1. Keating JF, Waterworth P, Shaw-Dunn J, Crossan J. The relative strengths of the rotator cuff muscles: a cadaver study. J Bone Joint Surg Br 1993;75:137-40.
2. Kuechle DK, Newman SR, Itoi E, Morrey BF, An KN. Shoulder muscle moment arms during horizontal flexion and elevation. J Shoulder Elbow Surg 1997;6:429-39.
3. Lyons RP, Green A. Subscapularis tendon tears. J Am Acad Orthop Surg 2005;13:353-63.
4. Li XX, Schweitzer ME, Bifano JA, Lerman J, Manton GL, El-Noueam KI. MR evaluation of subscapularis tears. J Comput Assist Tomogr 1999;23:713-7.
5. Lafosse L, Jost B, Reiland Y, Audebert S, Toussaint B, Gobezie R. Structural integrity and clinical outcomes after arthroscopic repair of isolated subscapularis tears. J Bone Joint Surg Am 2007;89:1184-93.
6. Arai R, Sugaya H, Mochizuki T, Nimura A, Moriishi J, Akita K. Subscapularis tendon tear: an anatomic and clinical investigation. Arthroscopy 2008;24:997-1004.
7. Bennett WF. Subscapularis, medial, and lateral head coracohumeral ligament insertion anatomy: arthroscopic appearance and incidence of "hidden" rotator interval lesions. Arthroscopy 2001;17:173-80.
8. Lo IK, Burkhart SS. The etiology and assessment of subscapularis tendon tears: a case for subcoracoid impingement, the roller-wringer effect, and TUFF lesions of the subscapularis. Arthroscopy 2003;19:1142-50.
9. Leite MJ, Pinho AR, Sa MC, Silva MR, Sousa AN, Torres JM. Coracoid morphology and humeral version as risk factors for subscapularis tears. J Shoulder Elbow Surg 2020;29:1804-10.
10. Leite MJ, Sa MC, Lopes MJ, Matos RM, Sousa AN, Torres JM. Coracohumeral distance and coracoid overlap as predictors of subscapularis and long head of the biceps injuries. J Shoulder Elbow Surg 2019;28:1723-7.
11. Cetinkaya M, Ataoglu MB, Ozer M, Ayanoglu T, Kanatli U. Subscapularis tendon slip number and coracoid overlap are more related parameters for subcoracoid impingement in subscapularis tears: a magnetic resonance imaging comparison study.

Arthroscopy 2017;33:734-42.
12. Cetinkaya M, Oner AY, Ataoglu MB, Ozer M, Ayanoglu T, Kanatli U. Lesser tuberosity cysts and their relationship with subscapularis tears and subcoracoid impingement. J Orthop Sci 2017;22:63-8.
13. Zhang H, Zhang Q, Li ZL. Coracohumeral index and coracoglenoid inclination as predictors for different types of degenerative subscapularis tendon tears. Int Orthop 2019;43:1909-16.
14. Mohtadi NG, Vellet AD, Clark ML, et al. A prospective, double-blind comparison of magnetic resonance imaging and arthroscopy in the evaluation of patients presenting with shoulder pain. J Shoulder Elbow Surg 2004;13:258-65.
15. Razmjou H, Fournier-Gosselin S, Christakis M, Pennings A, El-Maraghy A, Holtby R. Accuracy of magnetic resonance imaging in detecting biceps pathology in patients with rotator cuff disorders: comparison with arthroscopy. J Shoulder Elbow Surg 2016;25:38-44.
16. International Expert Committee. International Expert Committee report on the role of the A1C assay in the diagnosis of diabetes. Diabetes Care 2009;32:1327-34.
17. Chobanian AV, Bakris GL, Black HR, et al. Seventh report of the Joint National Committee on Prevention, Detection, Evaluation, and Treatment of High Blood Pressure. Hypertension 2003;42:1206-52.
18. Alberti KG, Zimmet P, Shaw J; IDF Epidemiology Task Force Consensus Group. The metabolic syndrome: a new worldwide definition. Lancet 2005;366:1059-62.
19. Grundy SM, Cleeman JI, Daniels SR, et al. Diagnosis and management of the metabolic syndrome: an American Heart Association/National Heart, Lung, and Blood Institute Scientific Statement. Circulation 2005;112:2735-52.
20. Grundy SM, Cleeman JI, Merz CN, et al. Implications of recent clinical trials for the National Cholesterol Education Program Adult Treatment Panel III guidelines. Circulation 2004;110:227-39.
21. Patte D. Classification of rotator cuff lesions. Clin Orthop Relat Res 1990;(254):81-6.
22. Cho NS, Rhee YG. The factors affecting the clinical outcome and integrity of arthroscopically repaired rotator cuff tears of the shoulder. Clin Orthop Surg 2009;1:96-104.
23. Goutallier D, Postel JM, Bernageau J, Lavau L, Voisin MC. Fatty muscle degeneration in cuff ruptures: pre- and postoperative evaluation by CT scan. Clin Orthop Relat Res 1994;(304):78-83.
24. Zanetti M, Gerber C, Hodler J. Quantitative assessment of the muscles of the rotator cuff with magnetic resonance imaging. Invest Radiol 1998;33:163-70.
25. Thomazeau H, Rolland Y, Lucas C, Duval JM, Langlais F. Atrophy of the supraspinatus belly: assessment by MRI in 55 patients with rotator cuff pathology. Acta Orthop Scand 1996;67:264-8.
26. Deutsch A, Altchek DW, Schwartz E, Otis JC, Warren RF. Radiologic measurement of superior displacement of the humeral head in the impingement syndrome. J Shoulder Elbow Surg 1996;5:186-93.
27. Belsley DA, Kuh E, Welsch RE. Regression diagnostics: identifying influential data and sources of collinearity. Hoboken, NJ: Wiley; 2005.
28. Eckel RH, Grundy SM, Zimmet PZ. The metabolic syndrome. Lancet 2005;365:1415-28.
29. Wang H, Cheng Y, Shao D, et al. Metabolic syndrome increases the risk for knee osteoarthritis: a meta-analysis. Evid Based Complement Alternat Med 2016;2016:7242478.
30. Abate M, Di Carlo L, Salini V, Schiavone C. Metabolic syndrome associated to non-inflammatory Achilles enthesopathy. Clin Rheumatol 2014;33:1517-22.
31. Park HB, Gwark JY, Im JH, Jung J, Na JB, Yoon CH. Factors associated with atraumatic posterosuperior rotator cuff tears. J Bone Joint Surg Am 2018;100:1397-405.
32. Sakurai G, Ozaki J, Tomita Y, Kondo T, Tamai S. Incomplete tears of the subscapularis tendon associated with tears of the supraspinatus tendon: cadaveric and clinical studies. J Shoulder Elbow Surg 1998;7:510-5.
33. Gerber C, Krushell RJ. Isolated rupture of the tendon of the subscapularis muscle: clinical features in 16 cases. J Bone Joint Surg Br 1991;73:389-94.
34. Gerber C, Hersche O, Farron A. Isolated rupture of the subscapularis tendon. J Bone Joint Surg Am 1996;78:1015-23.
35. Kim TK, Rauh PB, McFarland EG. Partial tears of the subscapularis tendon found during arthroscopic procedures on the shoulder: a statistical analysis of sixty cases. Am J Sports Med 2003;31:744-50.
36. Yamamoto A, Takagishi K, Osawa T, et al. Prevalence and risk factors of a rotator cuff tear in the general population. J Shoulder Elbow Surg 2010;19:116-20.
37. Mehta SK, Teefey SA, Middleton W, Steger-May K, Sefko JA, Keener JD. Prevalence and risk factors for development of subscapularis and biceps pathology in shoulders with degenerative rotator cuff disease: a prospective cohort evaluation. J Shoulder Elbow Surg 2020;29:451-8.
38. Bodin J, Ha C, Chastang JF, et al. Comparison of risk factors for shoulder pain and rotator cuff syndrome in the working population. Am J Ind Med 2012;55:605-15.
39. Kim YK, Jung KH, Kim JW, Kim US, Hwang DH. Factors affecting rotator cuff integrity after arthroscopic repair for medi-

um-sized or larger cuff tears: a retrospective cohort study. J Shoulder Elbow Surg 2018;27:1012-20.
40. Cho NS, Moon SC, Jeon JW, Rhee YG. The influence of diabetes mellitus on clinical and structural outcomes after arthroscopic rotator cuff repair. Am J Sports Med 2015;43:991-7.
41. Gaida JE, Alfredson L, Kiss ZS, Wilson AM, Alfredson H, Cook JL. Dyslipidemia in Achilles tendinopathy is characteristic of insulin resistance. Med Sci Sports Exerc 2009;41:1194-7.
42. Longo UG, Franceschi F, Ruzzini L, Spiezia F, Maffulli N, Denaro V. Higher fasting plasma glucose levels within the normoglycaemic range and rotator cuff tears. Br J Sports Med 2009;43:284-7.
43. Esposito K, Nappo F, Marfella R, et al. Inflammatory cytokine concentrations are acutely increased by hyperglycemia in humans: role of oxidative stress. Circulation 2002;106:2067-72.
44. Reddy GK. Glucose-mediated in vitro glycation modulates biomechanical integrity of the soft tissues but not hard tissues. J Orthop Res 2003;21:738-43.
45. Reddy GK, Stehno-Bittel L, Enwemeka CS. Glycation-induced matrix stability in the rabbit achilles tendon. Arch Biochem Biophys 2002;399:174-80.
46. Bergin D, Parker L, Zoga A, Morrison W. Abnormalities on MRI of the subscapularis tendon in the presence of a full-thickness supraspinatus tendon tear. AJR Am J Roentgenol 2006;186:454-9.
47. Erickson SJ, Fitzgerald SW, Quinn SF, Carrera GF, Black KP, Lawson TL. Long bicipital tendon of the shoulder: normal anatomy and pathologic findings on MR imaging. AJR Am J Roentgenol 1992;158:1091-6.
48. Chen CH, Hsu KY, Chen WJ, Shih CH. Incidence and severity of biceps long head tendon lesion in patients with complete rotator cuff tears. J Trauma 2005;58:1189-93.
49. Adams CR, Brady PC, Koo SS, et al. A systematic approach for diagnosing subscapularis tendon tears with preoperative magnetic resonance imaging scans. Arthroscopy 2012;28:1592-600.
50. Chae SH, Jung TW, Lee SH, et al. Hidden long head of the biceps tendon instability and concealed intratendinous subscapularis tears. Orthop J Sports Med 2020;8:2325967119898123.
51. Sahu D, Fullick R, Giannakos A, Lafosse L. Sentinel sign: a sign of biceps tendon which indicates the presence of subscapularis tendon rupture. Knee Surg Sports Traumatol Arthrosc 2016;24:3745-9.
52. Beall DP, Williamson EE, Ly JQ, et al. Association of biceps tendon tears with rotator cuff abnormalities: degree of correlation with tears of the anterior and superior portions of the rotator cuff. AJR Am J Roentgenol 2003;180:633-9.

https://doi.org/10.5397/cise.2021.00710

CiSE
Clinics in Shoulder and Elbow

Original Article

Clin Shoulder Elbow 2022;25(4):265-273
https://doi.org/10.5397/cise.2022.00836

eISSN 2288-8721

Dynamic three-dimensional shoulder kinematics in patients with massive rotator cuff tears: a comparison of patients with and without subscapularis tears

Yuji Yamada[1,2], Yoshihiro Kai[1,3], Noriyuki Kida[4], Hitoshi Koda[5], Minoru Takeshima[6], Kenji Hoshi[7], Kazuyoshi Gamada[7], Toru Morihara[8]

[1]*Graduate School of Health Science, Kyoto Tachibana University, Kyoto, Japan*
[2]*Department of Rehabilitation, Marutamachi Rehabilitation Clinic, Kyoto, Japan*
[3]*Faculty of Health Science, Kyoto Tachibana University, Kyoto, Japan*
[4]*Faculty of Arts and Sciences, Kyoto Institute of Technology University, Kyoto, Japan*
[5]*Department of Rehabilitation, Faculty of Health Science, Kansai Welfare Science University, Osaka, Japan*
[6]*Department of Orthopedics, Tanabe Central Hospital, Kyoto, Japan*
[7]*Graduate School of Medical Technology and Health Welfare Sciences, Hiroshima International University, Hiroshima, Japan*
[8]*Department of Orthopedics, Marutamachi Rehabilitation Clinic, Kyoto, Japan*

Background: Massive rotator cuff tears (MRCTs) with subscapularis (SSC) tears cause severe shoulder dysfunction. In the present study, the influence of SSC tears on three-dimensional (3D) shoulder kinematics during scapular plane abduction in patients with MRCTs was examined.
Methods: This study included 15 patients who were divided into two groups: supraspinatus (SSP) and infraspinatus (ISP) tears with SSC tear (torn SSC group: 10 shoulders) or without SSC tear (intact SSC group: 5 shoulders). Single-plane fluoroscopic images during scapular plane elevation and computed tomography (CT)-derived 3D bone models were matched to the fluoroscopic images using two-dimensional (2D)/3D registration techniques. Changes in 3D kinematic results were compared.
Results: The humeral head center at the beginning of arm elevation was significantly higher in the torn SSC group than in the intact SSC group (1.8±3.4 mm vs. −1.1±1.6 mm, $p<0.05$). In the torn SSC group, the center of the humeral head migrated superiorly, then significantly downward at 60° arm elevation ($p<0.05$). In the intact SSC group, significant difference was not observed in the superior-inferior translation of the humeral head between the elevation angles.
Conclusions: In cases of MRCTs with a torn SSC, the center of the humeral head showed a superior translation at the initial phase of scapular plane abduction followed by inferior translation. These findings indicate the SSC muscle plays an important role in determining the dynamic stability of the glenohumeral joint in a superior-inferior direction in patients with MRCTs.

Keywords: 3D-to-2D registration technique; Massive rotator cuff tears; Subscapularis tear; Shoulder kinematics; Center of humeral head

Received: February 3, 2022 Accepted: February 22, 2022
Correspondence to: Yuji Yamada
Graduate School of Health Science, Kyoto Tachibana University, 34 Yamada-cho, Oyake, Yamashina-ku, Kyoto 607-8175, Japan
Tel: +81-75-571-1111, E-mail: yuji12237311@gmail.com

Financial support: None.
Conflict of interest: None.

INTRODUCTION

Rotator cuff tear is a common shoulder disorder. The main symptoms are pain, restricted range of motion, muscle weakness, and other functional impairments. The primary function of the rotator cuff is to dynamically stabilize the shoulder joint by compressing the humeral head into the glenoid cavity and maintaining the centripetal position of the humeral head [1,2]. Burkhart [3] states that balance of force couples in the transverse and coronal planes is important in maintaining the stability and function of the glenohumeral (GH) joint. The balance of forces in the transverse plane is maintained by the subscapularis (SSC) muscles located anteriorly and the infraspinatus (ISP) and teres minor muscles located posteriorly [1,3]. In the coronal plane, the force couple is mainly formed by the supraspinatus (SSP) and deltoid muscles [4]. Rotator cuff tears disrupt the balance of the force couples, affecting the kinematics of the GH joint, resulting in the loss of ability to elevate the arm [3,5].

Some patients with massive rotator cuff tears (MRCTs) lose the ability to elevate the arm due to secondary changes such as muscle atrophy [6], fatty infiltration [7], and osteoarthritis [8]. This condition is called pseudoparalysis and is associated with abnormal GH joint kinematics, including superior migration of the humeral head on arm elevation [5,9]. Collin et al. [9] classified MRCTs into five types and investigated their relationship to active motion. The authors reported that a tear in the SSP and entire SSC (type B) or SSP, ISP, and superior SSC (type C) were risk factors for developing pseudoparalysis [9].

Furthermore, these patients had difficulty recovering elevation function in a rehabilitation program [10]. Sahara et al. [8] reported that although abnormal GH kinematics were identified in pseudoparalysis, significant difference was not observed in tear type between patients with and without pseudoparalysis. Although SSC tears are considered a risk factor for pseudoparalysis [10], some patients with MRCTs can perform active elevation [8,11]. The influence of SSC tears on GH kinematics in patients with MRCTs without pseudoparalysis is unclear.

In previous studies, cadaveric simulations [4,5], two-dimensional (2D) or three-dimensional (3D) static radiographs [12,13], and dynamic 3D analysis using the 3D-to-2D registration technique were used to measure joint kinematics in rotator cuff tears [8,14-16]. The 3D-to-2D registration technique allows accurate measurement of joint kinematics based on matching a bone model created from computed tomography (CT) images to X-ray fluoroscopic images. High in-plane accuracy is a strong point of these techniques employing single-plane radiographic imaging, with a reported accuracy of 0.47 mm and 1.53 mm for in-plane and out-of-plane translations, respectively, and 0.76° and 3.72° for in-plane and out-of-plane rotations, respectively [17]. In previous studies [14,16] in which this method was used, tear sizes were limited to medium or large rotator cuff tears. To the best of our knowledge, the effects of SSC tears on joint dynamics have not been previously investigated.

Knowledge of the effect of SSC muscle tears on GH kinematics may also provide important information for determining an effective treatment strategy. In the present study, the effects of SSC tears on 3D GH kinematics during scapular plane abduction were examined in patients with MRCTs without pseudoparalysis. We hypothesized that MRCTs with a torn SSC would exhibit greater translation of the humeral head relative to the glenoid cavity than MRCTs without such a tear.

METHODS

This study was conducted in compliance with the principles of the Declaration of Helsinki. The Institutional Review Board of Kyoto Prefectural Rehabilitation Hospital for the Disabled approved the study protocol (No. 11) and all subjects provided their written informed consent before participation.

Subjects

Patients with MRCTs involving at least two tendons, including the SSP and ISP, with or without the SSC, were recruited for the present study. MRCTs were confirmed based on magnetic resonance imaging (MRI) of all patients. Exclusion criteria included a concurrent neuromuscular disorder, a history of shoulder joint surgery, a score >3 on the numerical pain rating scale during arm elevation, and an inability to elevate the arm by at least 140°.

A total of 15 patients (15 shoulders; mean age, 76.1 years) were divided into two groups: 10 shoulders in the SSP and ISP with SSC tears (torn SSC group; mean age, 75.0 ± 7.4 years) and 5 shoulders in the SSP and ISP tears (intact SSC group; mean age, 78.4 ± 2.3 years). The demographic data for the two groups are shown in Table 1.

Image Evaluation

T1-weighted and T2-weighted MR images were obtained (3.0-T, X-series; Philips Healthcare, Best, the Netherlands). in the coronal oblique, sagittal oblique, and axial planes. The tear sizes were measured using MRI. For the SSP and ISP, the classification by DeOrio and Cofield was used [18]. A massive tear was defined as >5 cm retraction in the coronal plane. For the SSC, the modified Lafosse's classification [19] was used as follows: type I, a partial tear of the upper one-third of the SSC; type II, a complete tear of

https://doi.org/10.5397/cise.2022.00836

Table 1. Demographic, radiographic, and MRI data

Variable	Intact SSC group	Torn SSC group	p-value
Demographic data			
Patient:shoulder	5:5	10:10	-
Mean age (yr)	78.4 ± 2.3	75.0 ± 7.4	0.61
Male:female	1:4	4:6	0.60
Tear size of SSC			
Type I	-	0	
Type II	-	5	
Type III	-	3	
Type IV	-	2	
Fatty infiltration stage			
SSP	3.2 ± 0.8	3.6 ± 0.7	0.34
ISP	2.6 ± 1.1	3.7 ± 0.5	0.10
SSC	0.2 ± 0.4	2.7 ± 0.9	< 0.001
Cuff tear arthropathy			0.29
Grade 2	2	1	
Grade 3	2	4	
Grade 4A	1	1	
Grade 4B	0	4	

Values are presented as number or mean ± standard deviation.
MRI: magnetic resonance imaging, SSC: subscapularis, SSP: supraspinatus, ISP: infraspinatus.

the upper one-third of the SSC; type III, a complete tear of the upper two-thirds of the SSC; and type IV, a complete tear of the entire width of the SSC. Fatty infiltration of the SSP, ISP, and SSC muscles was graded using the 5-point semiquantitative scale described originally by Goutallier et al. [7] and modified for MRI analysis by Fuchs et al. [20] as follows: 0, normal; 1, some fat streaks; 2, fatty degeneration < 50% but still more muscle than fat; 3, fatty degeneration of 50% (equal fat and muscle); and 4, fatty infiltration > 50%. Furthermore, the radiologic evaluation of cuff tear arthropathy was classified into six types according to Hamada et al. [21]: grade 1, acromiohumeral interval (AHI) ≥ 6 mm; grade 2, AHI ≤ 5 mm; grade 3, AHI ≤ 5 mm, with acetabulization; grade 4A, GH arthritis, without acetabulization; grade 4B, GH arthritis, with acetabulization; grade 4A, humeral head collapse, which is characteristic of cuff tear arthropathy. The imaging evaluation data for the two groups are shown in Table 1.

Image Acquisition and 3D Modeling

Scapular plane abduction was recorded using a flat panel radiography/fluoroscopy (R/F) system (Sonialvision Safire, Shimadzu, 0.286 × 0.286 mm/pixel) and fluoroscopic images were acquired in a single anterior-posterior direction. Patients elevated the arm in the scapular plane (30° anteriorly to the frontal plane) from a natural hanging position to a maximum elevation over 3 seconds, with the elbow joint extended while standing. The distance from the tube of the flat panel R/F system to the target shoulder was 1,500 mm, and the sampling rate was 7.5 frames per second.

CT was then used to obtain 0.5 mm tomographic images of the humerus and scapula. A 3D bone model of the humerus and scapula was created from the tomographic images using segmentation software (3D-Doctor; Able Software Corp., Lexington, MA, USA). The 3D bone models were converted to a polygonal surface model and a smoothing process was applied using a 3D mesh processing software (MeshLab; www.meshlab.net/). A single experienced researcher embedded the local coordinate system of the glenoid and humerus onto the 3D bone models using the 3D-Aligner software (GLAB Corp., Higashihiroshima, Japan). Humerus coordinates were set with their origin at the center of the humeral head, a Y-axis parallel to the humeral shaft, and an X-axis passing through the center of the intertubercular groove [22]. Scapular coordinates were set with their origin at the center of the scapular glenoid cavity, a Y-axis parallel with a line connecting the topmost and lowermost edges of the glenoid cavity, and a Z-axis parallel to a line connecting the anterior-most and posterior-most edges of the glenoid cavity [22].

Model-Image Registration

JointTrack (open-source software; www.sourceforge.net/projected/jointtrack) was used to match the completed 3D bone model with the fluoroscopic images. Outlines in the 3D bone model were matched to outlines in the fluoroscopy images. The greater tubercle, lesser tubercle, humeral head, and humeral shaft were used as landmarks when matching the humerus. The acromial process, coracoid process, glenoid cavity, scapular spine, superior angle, medial margin, and inferior angle were used as landmarks when matching the scapula (Fig. 1).

Data Processing

The 3D shoulder kinematics were obtained using the 3D-Joint Manager software (GLAB Corp.). For the 3D joint orientation, the position of the distal bone in the local coordinate system of the proximal bone was calculated using the Euler angle [23]. Humeral elevation was defined as rotation about the Z-axis. Scapular motion was defined as anterior-posterior tilt about the X-axis, internal-external rotation about the Y-axis, and upward-downward rotation about the Z-axis. Internal-external humeral rotation relative to the scapula was defined as rotation about its Y-axis. The humeral head translation (in the superior-inferior, anterior-posterior, and medial-lateral directions) was calculated as the position of the humeral head center relative to the glenoid center. All kinematics data were measured from the beginning to the

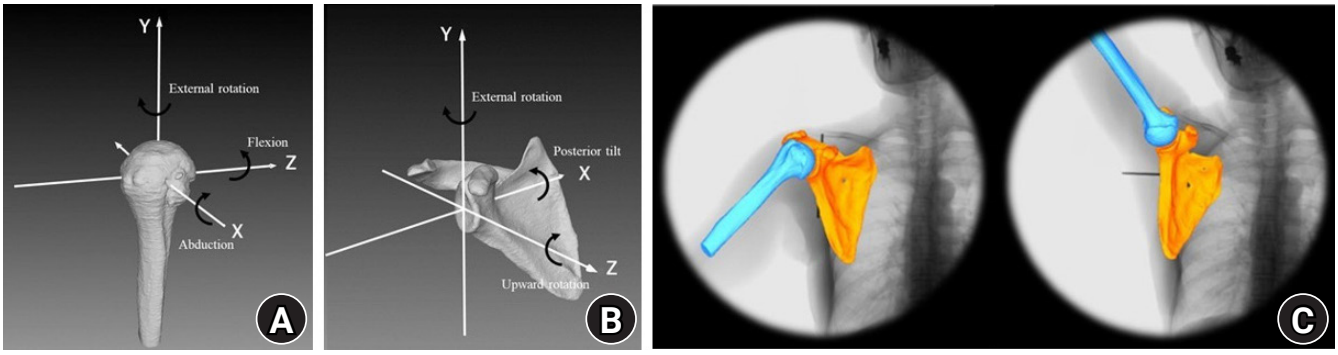

Fig. 1. Matching the three-dimensional (3D) bone model and fluoroscopic images. Fluoroscopic images are acquired, a 3D bone model of the humerus (A) and scapula (B) is created using the computed tomography images, and the bone model is matched with outlines on the fluoroscopy images (C).

end of arm elevation. In addition, translation on each axis was measured three times and the root-mean-square (RMS) error calculated to investigate measurement error. The RMS error observed in this study was an in-plane error of 0.12 mm and an out-of-plane error of 0.61 mm, which are comparable to previous validation studies [17].

Statistical Analysis

Image evaluation and kinematics results were compared between the intact and torn SSC groups. The Mann-Whitney U-test was used to compare age, fatty infiltration, and GH and scapular rotation angles at the beginning and end of arm elevation. Chi-square tests were used to analyze categorical data such as gender and rotator cuff tear arthropathy. The effect of the subject group (torn SSC group and intact SSC group) on the GH kinematics in the three translation directions of the humeral head was analyzed using a two-factor linear mixed-effects model. When a significant interaction between the subject group and arm elevation angle was observed, post hoc Bonferroni correction was used for further significance testing. The software used for statistical processing was IBM SPSS ver. 24 (IBM Corp., Armonk, NY, USA) and the statistical significance level was set at $p < 0.05$.

RESULTS

GH Positions

A significant nonlinear interaction was found for superior-inferior translation between the two independent factors, indicating the subject group effect on superior-inferior translation depended on elevation angle ($F = 3.85$, $p < 0.05$). The humeral head in patients in the torn SSC group was positioned significantly more superiorly than in the intact SSC group at the beginning of arm elevation (−1.1 ± 1.6 mm in the intact SSC group and 1.8 ± 3.4 mm in the torn SSC group, $p < 0.05$). In the torn SSC group, the center of the humeral head had migrated superiorly by 2.3 ± 3.9 mm at 50° arm elevation, then showed significant inferior translation (1.5 ± 3.9 mm) at 60° arm elevation ($p < 0.05$). In the intact SSC group, significant difference was not observed in superior-inferior translation between each arm elevation. Superior-inferior translation of the humeral head during arm elevation is shown in Fig. 2.

In both groups, anterior translation relative to the glenoid cavity was observed in the initial phase of arm elevation, then the humeral head gradually migrated posteriorly with increasing elevation (Fig. 3). However, significant interaction was not observed between the two independent factors in the anterior-posterior translation models ($F = 0.62$, $p = 0.43$). Furthermore, significant interaction was not observed between the two independent factors in the medial and lateral translation of the humeral head ($F = 0.03$, $p = 0.86$) (Fig. 4).

Rotation

Significant difference was not found in GH abduction angle between the intact and torn SSC groups at the beginning and end of arm elevation, although the GH abduction angle was slightly smaller in the torn SSC group at the end of elevation (Table 2). Significant difference was not observed between the two groups in the GH external rotation angles at the beginning and end of arm elevation.

The scapula showed upward rotation, posterior tilting, and external rotation in both groups during arm elevation. The upward scapular rotation at the end of arm elevation was significantly greater in the torn SSC group (52.1° ± 10.6°) than in the intact SSC group (42.0° ± 5.5°, $p < 0.05$) (Table 2). However, significant difference was not found at the beginning of elevation. Significant differences in posterior tilting and external scapular rotation

https://doi.org/10.5397/cise.2022.00836

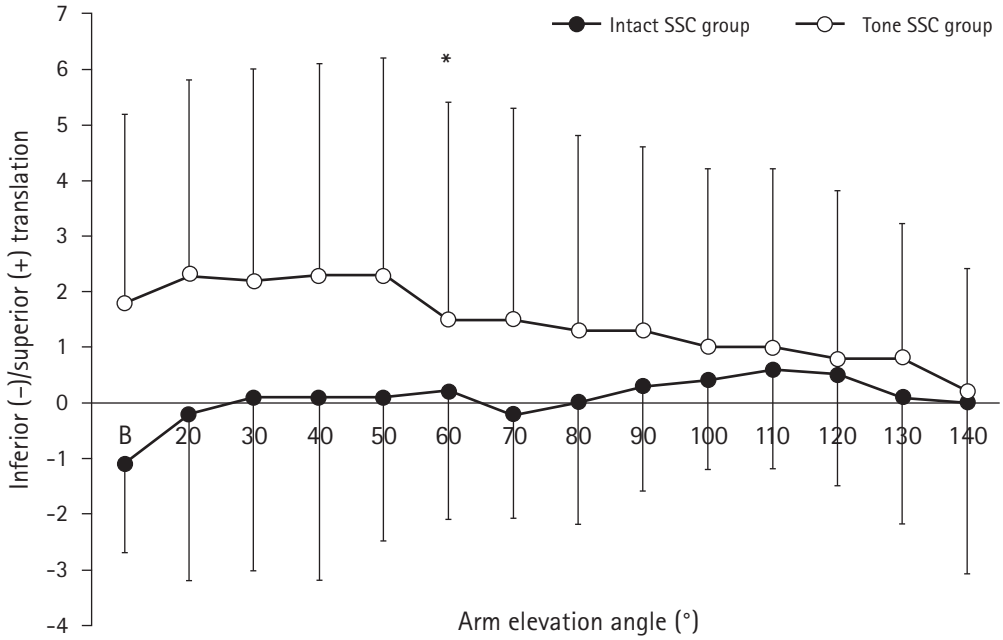

Fig. 2. Superior-inferior translation of the humeral head during arm elevation. The mean and standard deviation values are shown for the intact subscapularis (SSC) and tone SSC groups. In the torn SSC group, the center of the humeral head superiorly migrated by 2.3±3.9 mm at 50° arm elevation, which then showed a significant inferior translation (1.5±3.9 mm) at 60° arm elevation (*$p<0.05$). In the Intact SSC group, significant difference was not observed in the superior-inferior translation of the humeral head between the elevation angles. B: beginning of arm elevation.

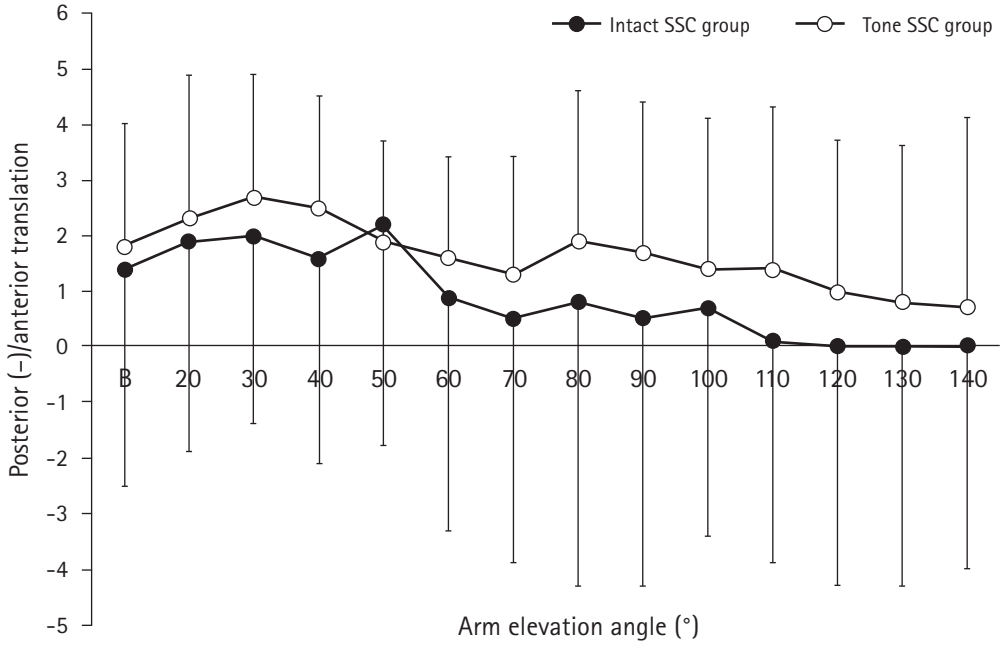

Fig. 3. Anterior-posterior translation of the humeral head during arm elevation. The mean and standard deviation values are shown for the intact subscapularis (SSC) and tone SSC groups. Significant difference was not observed between the two groups. B: beginning of arm elevation.

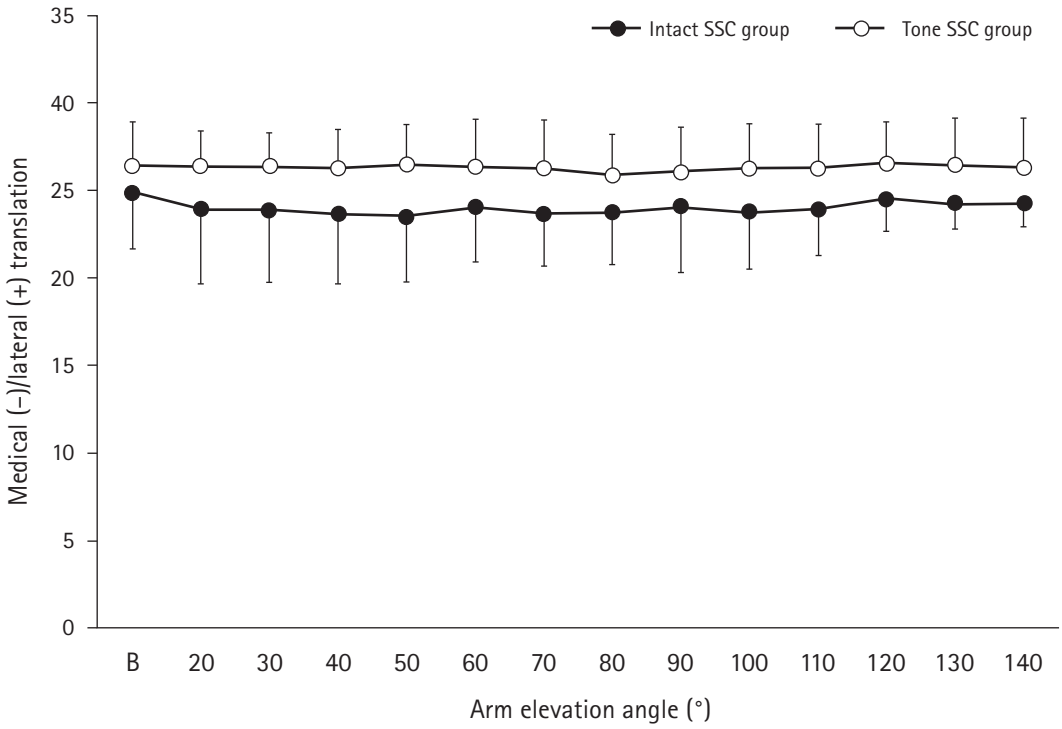

Fig. 4. Medial-lateral translation of the humeral head during arm elevation. The mean and standard deviation values are shown for the intact subscapularis (SSC) and tone SSC groups. Significant difference was not observed between the two groups. B: beginning of arm elevation.

Table 2. Kinematic results

Variable	Intact SSC group	Torn SSC group	p-value
Glenohumeral rotation (°)			
Abduction			
Beginning	12.6 ± 9.5	10.8 ± 8.4	0.70
End	97.1 ± 8.3	90.1 ± 9.4	0.17
External rotation			
Beginning	42.3 ± 28.5	44.2 ± 28.3	0.90
End	5.2 ± 12.5	9.4 ± 20.7	0.68
Scapular rotation (°)			
Upward rotation			
Beginning	13.8 ± 5.0	15.7 ± 9.3	0.66
End	42.0 ± 5.5	52.1 ± 10.6	0.03*
Posterior tilting			
Beginning	22.1 ± 5.0	25.6 ± 10.5	0.49
End	−13.7 ± 12.3	−9.5 ± 11.8	0.52
External rotation			
Beginning	43.9 ± 2.4	41.3 ± 9.2	0.54
End	37.4 ± 7.3	28.5 ± 12.2	0.16

Values are presented as mean ± standard deviation.
SSC: subscapularis.
*Statistically significant ($p < 0.05$).

were not observed between the two groups at the beginning and end of arm elevation (Table 2).

DISCUSSION

In previous studies, tears of the SSC in MRCTs were reported a risk factor for the development of pseudoparalysis [9,10]. However, in some studies, tear size alone was suggested insufficient to predict the ability to elevate the arm [8,11]. Furthermore, despite the abnormal joint kinematics affecting arm elevation, the effect of SSC tears on GH kinematics remains unclear. In the present study, SSC tear led to greater superior migration of the humeral head center, which then migrated inferiorly as the elevation progressed. To the best of our knowledge, this is the first study in which the effects of SSC tears on GH kinematics were investigated in patients with MRCTs using 3D kinematics analysis with 3D-to-2D registration technique.

Burkhart [3] reported that MRCTs with a torn SSC failed to maintain the coronal plane force couple and showed obvious superior migration of the humeral head into contact with the subacromial surface. These patients showed "captured fulcrum kinematics," in which the undersurface or anterior end of the acromion was used as a fulcrum to elevate the shoulder [3]. In the present study, the humeral head was located significantly more superiorly at the beginning of arm elevation in the torn SSC group than in the intact SSC group. However, the ability to elevate the arm was maintained. This result may support Burkhart's theory

https://doi.org/10.5397/cise.2022.00836

[3] that a superiorly migrated humerus head creates a fulcrum on the acromion's undersurface.

Regarding the resultant force applied to the humeral head during arm elevation, the vertical force on the glenoid cavity is greatest at 90° elevation and the shear force acting superiorly on the humeral head is greatest between 30° and 60° elevation [2,24]. Because the force of the deltoid muscle causes the upward shearing force on the humeral head to be greatest in the initial phase of the arm elevation, the rotator cuff must exert its greatest force at 60° of elevation and hold the humeral head in the glenoid cavity [2]. In the present study, the humeral head migrated superiorly up to 50° of elevation and inferiorly at 60° of elevation in the torn SSC group, consistent with the importance of the downward action of the humeral head against the upward shear force at 50° to 60° of elevation to enable active elevation in patients with MRCTs with SSC tears.

In contrast, the intact SSC group showed no superior migration of the humeral head relative to the glenoid on arm elevation. Kijima et al. [14] and Millet et al. [16] observed GH kinematics of medium tears with an intact SSC and reported the humeral head did not show significant superior migration in patients with or without symptoms. Kozono et al. [15] found slight superior migration of the humeral head during active arm elevation in patients with large or massive tears (whether these were with or without SSC tears is unknown) compared with healthy subjects. However, significant difference was not found in humeral head position between the two groups. Thus, the presence or absence of SSC tears in patients with MRCTs may affect the dynamic stability of the GH joint in the superior and inferior directions.

Significant difference was not observed in the anterior-posterior and medial-lateral translation of the humeral head between the intact SSC and the torn SSC groups. In cadaveric studies, the effects of rotator cuff tears on GH motion were investigated and tears involving the upper half of the SSC led to anterosuperior translation [25], whereas SSP and ISP tears led to posterior translation [26]. In contrast, Kozono et al. [15] observed anterior-posterior and medial-lateral migration of the humeral head *in vivo* and found no significant difference between patients with massive tears and healthy subjects. In their study, both groups showed a slight anterior translation after the beginning of arm elevation [15]. In the present study, the humeral head was located anteriorly at the beginning of arm elevation in both groups and gradually migrated posteriorly as elevation progressed. The alterations in GH motion observed in this study may be characteristic of massive tears *in vivo*.

The torn SSC group had a slightly smaller GH abduction angle and a greater upward rotation of the scapula (i.e., reduced scapulohumeral rhythm) compared with the intact SSC group. Miura et al. [27] measured 3D scapular kinematics in patients with MRCTs and showed the GH abduction angle was significantly smaller and the upward rotation of the scapula was greater than in elderly people without rotator cuff tears. Simulation studies using cadavers showed that as the size of the rotator cuff tear increases, the force required for the deltoid muscle to elevate the arm also increases [28,29]. Furthermore, in electromyographic studies, significantly increased muscle activity was observed in the upper trapezius and the serratus anterior muscle that rotates the scapula in patients with MRCTs [30]. The results of these previous studies [27-30] support our findings and indicate a compensatory increase in upward rotation of the scapula to compensate for the GH abduction torque compromised by the rotator cuff tear.

The present study had several limitations. First, only MRCT subjects capable of active arm elevation were studied. Patients with pseudoparalysis were excluded because humeral head migration was compared at different arm elevation angles. Second, intact rotator cuff and other shoulder muscle activities that affect GH kinematics were not investigated using electromyography or other methods. Finally, a sufficient sample size to improve the statistical power of the study could not be obtained because the target was very severe MRCTs. Electromyographic and simulation analyses are necessary in future studies to investigate the compensatory functions involved in active arm elevation and comparison of joint dynamics with pseudoparalysis patients.

We hypothesized that MRCTs with a torn SSC would exhibit greater translation of the humeral head relative to the glenoid cavity than MRCTs without this type of tear. In cases of MRCT with a torn SSC, the center of the humeral head showed a superior translation at the initial phase of scapular plane abduction followed by inferior translation. These findings indicate the SSC muscle plays an important role in determining the dynamic stability of the GH joint in a superior-inferior direction in patients with MRCTs.

ACKNOWLEDGMENTS

The authors would like to thank H. Itou for providing technical assistance with the experiments. We also thank Y. Miura and H. Fukushima for their expertise on shoulder rehabilitation.

REFERENCES

1. Burkhart SS. Arthroscopic treatment of massive rotator cuff tears: clinical results and biomechanical rationale. Clin Orthop

Relat Res 1991;(267):45-56.
2. Inman VT, Saunders JB, Abbott LC. Observations of the function of the shoulder joint. 1944. Clin Orthop Relat Res 1996;(330):3-12.
3. Burkhart SS. Fluoroscopic comparison of kinematic patterns in massive rotator cuff tears: a suspension bridge model. Clin Orthop Relat Res 1992;(284):144-52.
4. Parsons IM, Apreleva M, Fu FH, Woo SL. The effect of rotator cuff tears on reaction forces at the glenohumeral joint. J Orthop Res 2002;20:439-46.
5. Mura N, O'Driscoll SW, Zobitz ME, et al. The effect of infraspinatus disruption on glenohumeral torque and superior migration of the humeral head: a biomechanical study. J Shoulder Elbow Surg 2003;12:179-84.
6. Warner JJ, Higgins L, Parsons IM 4th, Dowdy P. Diagnosis and treatment of anterosuperior rotator cuff tears. J Shoulder Elbow Surg 2001;10:37-46.
7. Goutallier D, Postel JM, Bernageau J, Lavau L, Voisin MC. Fatty muscle degeneration in cuff ruptures: pre- and postoperative evaluation by CT scan. Clin Orthop Relat Res 1994;(304):78-83.
8. Sahara W, Yamazaki T, Inui T, Konda S. Three-dimensional kinematic features in large and massive rotator cuff tears with pseudoparesis. J Shoulder Elbow Surg 2021;30:720-8.
9. Collin P, Matsumura N, Lädermann A, Denard PJ, Walch G. Relationship between massive chronic rotator cuff tear pattern and loss of active shoulder range of motion. J Shoulder Elbow Surg 2014;23:1195-202.
10. Collin PG, Gain S, Nguyen Huu F, Lädermann A. Is rehabilitation effective in massive rotator cuff tears. Orthop Traumatol Surg Res 2015;101(Suppl 4):S203-5.
11. Wieser K, Rahm S, Schubert M, et al. Fluoroscopic, magnetic resonance imaging, and electrophysiologic assessment of shoulders with massive tears of the rotator cuff. J Shoulder Elbow Surg 2015;24:288-94.
12. Dennis DA, Mahfouz MR, Komistek RD, Hoff W. In vivo determination of normal and anterior cruciate ligament-deficient knee kinematics. J Biomech 2005;38:241-53.
13. Keener JD, Wei AS, Kim HM, Steger-May K, Yamaguchi K. Proximal humeral migration in shoulders with symptomatic and asymptomatic rotator cuff tears. J Bone Joint Surg Am 2009;91:1405-13.
14. Kijima T, Matsuki K, Ochiai N, et al. In vivo 3-dimensional analysis of scapular and glenohumeral kinematics: comparison of symptomatic or asymptomatic shoulders with rotator cuff tears and healthy shoulders. J Shoulder Elbow Surg 2015;24:1817-26.
15. Kozono N, Okada T, Takeuchi N, et al. Dynamic kinematics of the glenohumeral joint in shoulders with rotator cuff tears. J Orthop Surg Res 2018;13:9.
16. Millett PJ, Giphart JE, Wilson KJ, Kagnes K, Greenspoon JA. Alterations in glenohumeral kinematics in patients with rotator cuff tears measured with biplane fluoroscopy. Arthroscopy 2016;32:446-51.
17. Matsuki K, Matsuki KO, Yamaguchi S, et al. Dynamic in vivo glenohumeral kinematics during scapular plane abduction in healthy shoulders. J Orthop Sports Phys Ther 2012;42:96-104.
18. DeOrio JK, Cofield RH. Results of a second attempt at surgical repair of a failed initial rotator-cuff repair. J Bone Joint Surg Am 1984;66:563-7.
19. Lafosse L, Jost B, Reiland Y, Audebert S, Toussaint B, Gobezie R. Structural integrity and clinical outcomes after arthroscopic repair of isolated subscapularis tears. J Bone Joint Surg Am 2007;89:1184-93.
20. Fuchs B, Weishaupt D, Zanetti M, Hodler J, Gerber C. Fatty degeneration of the muscles of the rotator cuff: assessment by computed tomography versus magnetic resonance imaging. J Shoulder Elbow Surg 1999;8:599-605.
21. Hamada K, Yamanaka K, Uchiyama Y, Mikasa T, Mikasa M. A radiographic classification of massive rotator cuff tear arthritis. Clin Orthop Relat Res 2011;469:2452-60.
22. Saka M, Yamauchi H, Yoshioka T, Hamada H, Gamada K. Scapular kinematics during late cocking of a simulated throwing activity in baseball players with shoulder injury: a cross-sectional study using a 3D-to-2D registration technique. J Sport Rehabil 2015;24:91-8.
23. Hébert LJ, Moffet H, McFadyen BJ, Dionne CE. Scapular behavior in shoulder impingement syndrome. Arch Phys Med Rehabil 2002;83:60-9.
24. Poppen NK, Walker PS. Forces at the glenohumeral joint in abduction. Clin Orthop Relat Res 1978;(135):165-70.
25. Su WR, Budoff JE, Luo ZP. The effect of anterosuperior rotator cuff tears on glenohumeral translation. Arthroscopy 2009;25:282-9.
26. Oh JH, Jun BJ, McGarry MH, Lee TQ. Does a critical rotator cuff tear stage exist?: a biomechanical study of rotator cuff tear progression in human cadaver shoulders. J Bone Joint Surg Am 2011;93:2100-9.
27. Miura Y, Kai Y, Morihara T, et al. Three-dimensional scapular kinematics during arm elevation in massive rotator cuff tear patients. Prog Rehabil Med 2017;2:20170005.
28. Dyrna F, Kumar NS, Obopilwe E, et al. Relationship between deltoid and rotator cuff muscles during dynamic shoulder abduction: a biomechanical study of rotator cuff tear progression. Am J Sports Med 2018;46:1919-26.

https://doi.org/10.5397/cise.2022.00836

29. Hansen ML, Otis JC, Johnson JS, Cordasco FA, Craig EV, Warren RF. Biomechanics of massive rotator cuff tears: implications for treatment. J Bone Joint Surg Am 2008;90:316-25.
30. Hawkes DH, Alizadehkhaiyat O, Kemp GJ, Fisher AC, Roebuck MM, Frostick SP. Shoulder muscle activation and coordination in patients with a massive rotator cuff tear: an electromyographic study. J Orthop Res 2012;30:1140-6.

Original Article

Clin Shoulder Elbow 2022;25(4):274-281
https://doi.org/10.5397/cise.2022.00864

CiSE
Clinics in Shoulder and Elbow

eISSN 2288-8721

Constant score in asymptomatic shoulders varies with different demographic populations: derivation of adjusted score equation

Nitesh Gahlot, Ankit Rai, Jeshwanth Netaji

Department of Orthopaedics, All India Institute of Medical Sciences (AIIMS), Jodhpur, India

Background: In the present study, the age- and sex-adjusted Constant score (CS) in a normal Indian population was calculated and any differences with other population cohorts assessed.
Methods: The study participants were patients who visited the outpatient department for problems other than shoulder and healthy volunteers from the local population. Patients without shoulder pain/discomfort during activity were included in the study. Subjects with any problem that might affect shoulder function (e.g., cervical, thoracic spine, rib cage deformity, inflammatory arthritis) were excluded. Constant scoring of all participants was performed by trained senior residents under the supervision of the senior faculty. Shoulder range of movement and strength were measured following recommendations given by the research and Development Committee of the European Society for Shoulder and Elbow Surgery (2008). A fixed spring balance was used for strength measurement; one end was fixed on the floor and the other end tied with a strap to the wrist of the participant, arm in 90° abduction in scapular plane with palm facing down.
Results: Among the 248 subjects (496 shoulders), the average age was 37 years (range, 18–78 years), 65.7% were males (326 shoulders) and 34.3% females (170 shoulders). The mean CS was 84.6±2.9 (males, 86.1±3.0; females, 81.8±2.9). CS decreased significantly after 50 years of age in males and 40 years of age in females ($p<0.05$). The mean CS was lower than in previous studies for both males and females. Heavy occupation workers had higher mean CS ($p<0.05$). A linear standardized equation was estimated for calculating the adjusted CS for any age.
Conclusions: Mean CS and its change with age differed from previous studies among various population cohorts.

Keywords: Shoulder joint; Adult; Healthy volunteers; Occupations; Constant–Murley score; Functional assessment

INTRODUCTION

Numerous methods and scoring systems have been implemented to evaluate and quantify the function in normal and diseased shoulders. The constant shoulder score first published as a university thesis in 1986 is widely accepted among shoulder surgeons and has been mandated by the European Shoulder and Elbow Society [1]. Constant score (CS) incorporates both subjective and objective assessment regardless of the diagnosis, rendering it widely applicable. CS is a 100-point scoring system: 35 points for the subjective assessment (pain, 15 points; arm position and ability to perform daily routine activities, 20 points) and 65 points for the objective assessment (range of motion [ROM]: lateral and forward elevation, internal and external rotation, and

Received: February 7, 2022 Revised: June 2, 2022 Accepted: June 20, 2022
Correspondence to: Nitesh Gahlot
Department of Orthopaedics, All India Institute of Medical Sciences (AIIMS), Jodhpur, Rajasthan 342005, India
Tel: +91-91-1609-6665, E-mail: doc.nitesh@gmail.com, ORCID: https://orcid.org/0000-0001-7352-5228

Financial support: None.
Conflict of interest: None.

shoulder strength) [2].

Shoulder strength and functional demand vary among age groups, sex, and demographic populations [3,4]. The age- and sex-adjusted normative data are essential for any patient-reported outcome measure to ensure the patient outcomes can be compared with similar population cohorts because the normal score values can differ for various populations. Individual-adjusted CS comparing CS of the diseased shoulder with the contralateral side can be used for unilateral shoulder pathologies, however, bilateral shoulder affiliations limit its use. In addition, comparing CS with the contralateral shoulder does not provide the normal CS that should be achieved for a good outcome categorization. The age- and sex-adjusted CSs not only simplify post-injury and post-surgery outcome assessment but also mitigate the biases that may arise due to demographic variation [5].

Normative data for the CS have been published by a few authors representing their respective regional populations (American, Australian, and European) [4,6-9]. Currently, there are no studies in the literature in which South Asian populations, specifically the Indian population, have been investigated. Therefore, in the present study, the age- and sex-adjusted CSs in the normal population were calculated and any gradient of change in the CS with increasing age determined. In addition, the effect of work profile on normal shoulder function was evaluated.

METHODS

The present study included patients who visited the outpatient department for problems other than shoulder (i.e., normal shoulders) and healthy volunteers from the local population. The study was conducted at a tertiary care hospital. Prior to the start of the study, ethical approval from the All India Institute of Medical Sciences, Jodhpur Ethical Committee (No. AIIMS/IEC/2021/3720, Date 06/09/2021) was obtained. Data were collected for more than 3 months after obtaining institutional review board approval. Informed and written consent was obtained from the participants regarding documentation of the research findings. Patients were assured the study results would not affect their treatment protocol.

All the included subjects had normal shoulders according to the original definition given by Constant (no limitation of movements and absence of pain during activities of daily living) [4]. Only patients with no shoulder pain/discomfort when using their shoulder were included in the study. Skeletal maturity was a requirement for inclusion in the study, thus, 18 years was the lower cut-off age. Subjects with any problem that might affect shoulder function (cervical, thoracic spine, rib cage deformity, inflammatory arthritis) were excluded from the study. Any pathology of cervical and thoracic spine or chest might cause painful shoulder movements due to muscle spasm, and inflammatory arthritis can involve the shoulder joint. Therefore, a thorough history was recorded and physical examination performed for each patient to exclude any shoulder pathology. Any specialized test (e.g., magnetic resonance imaging or radiology) was not considered ethical because the participants did not have any symptoms.

Constant scoring of all participants was performed by senior residents under the supervision of the senior faculty. Participants completed questionnaires regarding their subjective pain sensation and ability to perform daily routine activities. ROM was recorded using a goniometer with thoracic spine as reference for abduction. ROM was measured according to recommendations of the European Society for Shoulder and Elbow Surgery [3]. The participant sat in a chair or bed with weight evenly distributed across the ischial tuberosities. During the examination, no rotation of the upper body was permitted and participants had to lift their arm to a pain-free level [3]. To measure the shoulder strength, the recommendations provided by the research and development committee of the European Society for Shoulder and Elbow Surgery in 2008 were followed [3]. A fixed spring balance was used; one end was fixed on the floor and the other end tied with a strap to the wrist of the participant. Subjects were asked to hold the spring balance in $>90°$ abduction in the scapular plane with the palm facing down. The maximum effort at 5 seconds was recorded. Three measurements were taken at 1-minute intervals; the highest reading was used as strength of shoulder abduction [10]. The mean CS was graded according to Bahrs et al. [11] as follows: 86–100, very good; 71–85, good; 56–70, fair; and <56, poor.

All participants in this study were classified based on occupation according to the International Standard Classification of Occupations (ISCO-08) published by the International Labour Organization (ILO) at Geneva in 2012. The ISCO-08 classifies occupational activity into 10 major groups: (1) managers, (2) professionals, (3) technicians and associate professionals, (4) clerical support workers, (5) services and sales workers, (6) skilled agricultural, forestry and fishery workers, (7) craft and related trades workers, (8) plant and machine operators and assemblers, (9) elementary occupations, and (10) armed forces occupations. In the present study, the participants were divided into two categories based on work profile and involvement of physical labor. Category I consisted of the light work group (groups 1–5) and category II consisted of the heavy work group (groups 6–10) [12].

The data collected and recorded on a standardized sheet included demographic variables, relevant history, and the CS with

its subsections. For analysis, the participants were classified into six age groups: <20, 20–29, 30–39, 40–49, 50–59, and ≥ 60 years. Descriptive statistics (mean and standard deviation, minimum, maximum, and 95% confidence interval) were calculated for each age group overall and separately for males and females. The mean CS was compared between males and females using the independent t-test. A p-value <0.05 was considered statistically significant. The CS was modeled for each age group using linear regression. A linear standardized equation was estimated for each age group by calculating the adjusted CS for any age belonging to that decade. Statistical analysis was performed using the IBM SPSS version 23.0 (IBM Corp., Armonk, NY, USA). Multivariate regression analysis was performed for various age groups and sex. The independent variables considered were age and occupation. For assessing multicollinearity, collinearity statistics were analyzed using tolerance and variance inflation factor. The tolerance was nearly equal to 1 and variance inflation factor was <v2.

RESULTS

A total of 1,926 patients visited the outpatient department during the data collection period; 1,728 patients were excluded from the study based on the previously mentioned exclusion criteria and 198 patients were finally included in the study. Healthy subjects visiting the hospital as well as patients and hospital staff were selected as controls (n=50). A total of 248 subjects (496 shoulders) were finally enrolled for analysis. The average age of the participants in this study was 37 years and ranged from 18–78 years; 65.7% were males (326 shoulders) and 34.3% were females (170 shoulders) (Table 1). The age and sex distribution of study subjects was not statistically different (p>0.05). Multivariate analysis was performed based on age and occupation as dependent variables. The independent variables were non-colinear.

The overall mean CS was 84.6±2.9. The mean CS in males was 86.1±3.0 and 81.8±2.9 in females (p<0.05). The mean CS decreased with age both in males and females and was significant after 50 years of age in males and 40 years of age in females (p<0.05) (Fig. 1). Significant difference was observed between the mean CS for males and females in each age group except the <20 years age group (Table 2). A multivariate linear regression equation was derived based on the present data to calculate the

Table 1. Age and sex distribution of study subjects

Age group (yr)	Male (n=163)	Female (n=85)	Total (n=248)
<20	3 (1.8)	1 (1.2)	4 (1.6)
20–29	52 (31.9)	27 (31.8)	79 (31.9)
30–39	55 (33.7)	24 (28.2)	79 (31.9)
40–49	24 (14.7)	13 (15.3)	37 (14.9)
50–59	18 (11.0)	12 (14.1)	30 (12.1)
≥60	11 (6.7)	8 (9.4)	19 (7.7)

Values are presented as number (%).

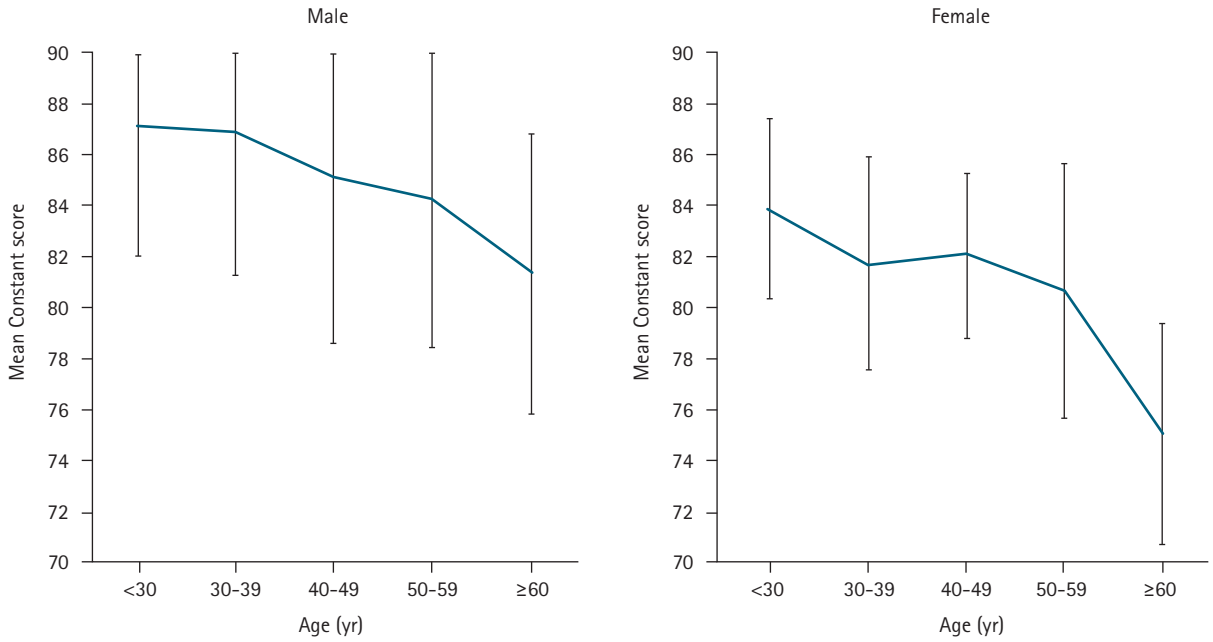

Fig. 1. Changes in mean Constant score based on age and sex. The <20 year and 20–29 year groups were merged for the sake of better calculation of mean as the number of participants in the <20 year age group was significantly less.

https://doi.org/10.5397/cise.2022.00864

Table 2. Comparison of mean Constant score by sex in different age groups

Age group (yr)	Sex	Number	Constant score	p-value
< 20	Male	6	86.67 ± 3.36	0.647
	Female	2	86.00 ± 0.00	
20–29	Male	104	87.22 ± 5.16	< 0.001
	Female	54	83.87 ± 3.56	
30–39	Male	110	86.96 ± 5.62	< 0.001
	Female	48	81.77 ± 4.16	
40–49	Male	48	85.21 ± 6.55	0.009
	Female	26	82.15 ± 3.20	
50–59	Male	36	84.31 ± 5.81	0.016
	Female	24	80.71 ± 4.99	
≥ 60	Male	22	81.41 ± 5.51	< 0.001
	Female	16	75.06 ± 4.31	

Values are presented as mean ± standard deviation. The difference was significant in all the age groups except < 20 years age group.

Table 3. Sex wise regression equations for estimating the mean Constant score for different age groups

Age group (yr)	Sex	Number	Regression equation
< 20	Male	6	Insufficient data*
	Female	2	Insufficient data*
20–29	Male	104	80.628+(0.195 × age)+(1.382 × occupation)
	Female	54	86.374+(0.063 × age)–(3.753 × occupation)
30–39	Male	110	79.398+(0.285 × age)–(1.810 × occupation)
	Female	48	80.349+(0.222 × age)–(5.747 × occupation)
40–49	Male	48	111.251+(0.690 × age)+(2.462 × occupation)
	Female	26	86.229–(0.182 × age)+(3.529 × occupation)
50–59	Male	36	112.858–(0.554 × age)+(0.756 × occupation)
	Female	24	107.151–(0.481 × age)†
≥ 60	Male	22	92.972–(0.132 × age)–(2.519 × occupation)
	Female	16	72.984–(0.030 × age)†

*The number of participants in these age groups was significantly less for calculating any meaningful equation; †All the females in these age groups belonged to the light work group, hence the equation did not have the occupation factor.

normal adjusted CS at any particular age (Table 3). Among participants, 14% had very good mean CS, 60% good, 25% fair, and 1% poor. The mean CS for the right shoulder was 84.5 ± 3 and 84.8 ± 2.9 for the left shoulder and was not statistically significantly different ($p > 0.05$). Therefore, both shoulders were included for assessment of the overall mean CS (Table 4).

The subjective portion of the CS was equal for all participants because the subjects did not experience pain during shoulder movements, were able to fully perform activities of daily living and/or recreational sports, and sleep was unaffected. All participants were able to move their arm above their head, thus, the subjective score was 35 for all participants. The objective assessment included the strength and ROM measurements. The overall mean strength score was 11.4 ± 2.5. The mean strength score also significantly decreased with age ($p < 0.05$) (Fig. 2). Males had a statistically higher mean strength score (12.9 ± 2.7) than females (8.6 ± 1.6, $p < 0.05$). Forward flexion, lateral elevation, and external rotation did not show any change with advancing age ($p > 0.05$). All participants (except one) scored 10 each in the above three movements. One participant scored 8 points in the forward flexion although she had no functional limitation in her daily activities or job as office clerk. Internal rotation in males remained steady throughout all age decades (CS range, 4–10 points; $p > 0.05$), however, internal rotation in elderly females deteriorated after the fifth decade (CS range, 2–10 points; $p < 0.05$).

In terms of occupational activity, heavy occupational activity subjects (category II) showed a higher mean CS (85.66) than lower occupational activity subjects (category I, 84.29; $p < 0.05$) (Table 5). Although category II patients had higher strength and

Table 4. Constant score for left and right shoulders

Type of occupation	Number	Constant score	Range	p-value
Left	248	84.48 ± 5.99	66–100	0.595*
Right	248	84.76 ± 5.83	70–98	

Values are presented as mean ± standard deviation.
*Not significant.

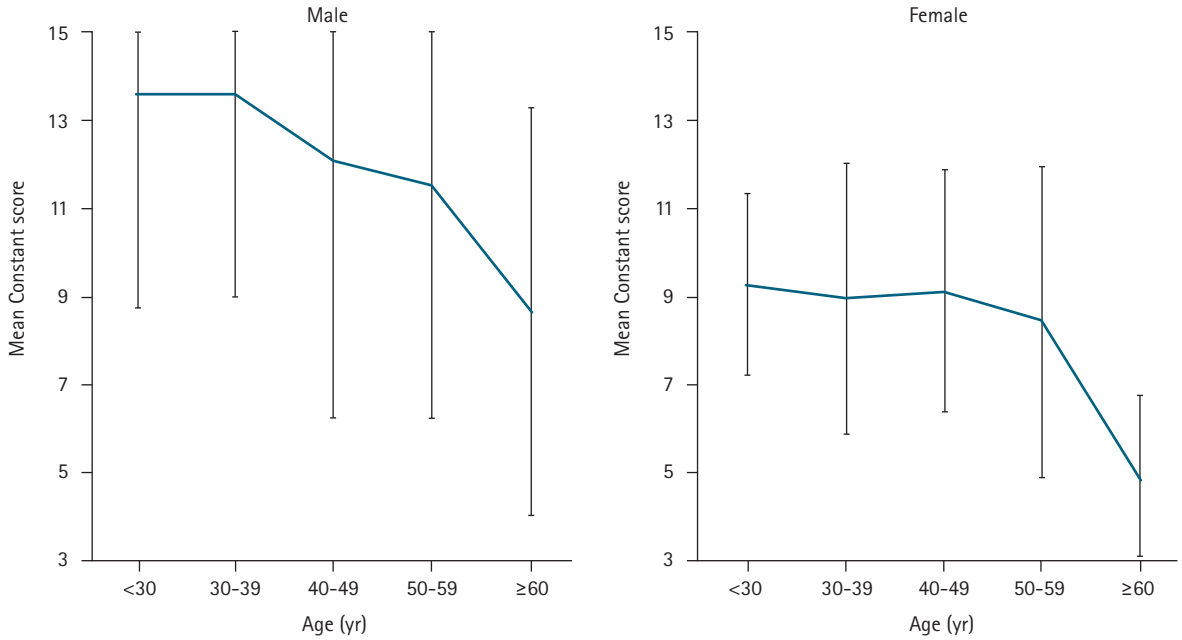

Fig. 2. Changes in strength measurement across age groups. The <20 year and 20–29 year groups were merged for the sake of better calculation of mean as the number of participants in the <20 year age group was significantly less.

Table 5. Comparison of mean Constant score by occupation between light work (category I) and heavy work (category II)

Type of occupation	Number	Constant score	Range	p-value
Light (category I)	376	84.29 ± 5.78	68–98	0.024*
Heavy (category II)	120	85.66 ± 5.75	75–99	

Values are presented as mean ± standard deviation.
*Significant.

internal rotation values compared with the category I patients, the difference was statistically non-significant ($p > 0.05$).

DISCUSSION

Method of Measurement

The CS is a reliable outcome measurement method for assessing patients before and after surgical treatment, however, its comparability in patients from different demographic population has not yet been confirmed. Despite the widespread usage and applicability, CS has been criticized due to its poor standardization [13], problems with strength measurement method [14], and inability to evaluate shoulder instability [15]. In 2008, modifications were implemented and a proper methodology with instrumentation was presented, focusing on the assessment method of shoulder abduction strength [3]. Among the multiple methods described by various authors in the literature, the fixed spring balance method and the dynamometer method have been found accurate and reproducible for assessing shoulder strength [16,17]. In the present study, the fixed spring balance method was used. Measuring the strength in the scapular plane provides maximum biomechanical advantage due to the optimum glenohumeral conformity and perfect length-tension ratio in the abductor musculature. This testing position has also been used by Katolik et al. [6] to evaluate the CS.

https://doi.org/10.5397/cise.2022.00864

Age Effect

The functional demands of a young adult male/female differ from an elderly individual. Walton et al. [18] have raised concerns regarding different score results in males versus female patients and score reduction with age. Constant et al. [4] (France) initially observed a steady CS with minimal change across the age groups, followed by a steady decline in males 50 years of age. The variation in scores was higher in females across the age groups. Yian et al. [8] (Switzerland) reported minimal decrease in the CS with aging, especially in females over 40 years of age and males over 60 years of age. Katolik et al. [6] (America) calculated the normalized CS. The authors reported a decrease in CS after 60 years of age, which became significant after 70 years of age in males. The CS decreased in female subjects after 50 years of age. Tavakkolizadeh et al. [7] (UK) reported a decrease in CS in the fifth decade in males, which increased after 70 years of age. The decrease in CS was greater in females after 60 years of age and CS further decreased after 70 years age. The mean CSs in the present study were lower in each age group (Table 6). In the present study, a sharp decrease in CS was observed after 50 years of age in males and 40 years of age in females. The differences in results among studies that included various demographic populations indicates that normative data of the same patient population should be compared. Therefore, normative CS data from different geographic populations are needed.

Sex Effect

In previous studies, statistically significantly higher mean CS was observed in males than in females [4,6-8]. In addition, a similar trend was observed in the present study population with higher mean CSs in males (86.1±3.0) than in females (81.8±2.9, $p<0.05$). The declining shoulder strength with age and greater shoulder strength in males explain this variation in mean CSs [19,20] allowing reasonable comparisons of outcome scores with age- and sex-adjusted CSs in that population [8]. To compare patients from the same demographic population, an equation based on linear regression for each age group was separately derived in male and female groups. Patient age can be added to the equation to calculate the ideal CS at that age based on the CS in the normal population of the same age group (Table 2).

Score Subsections

The shoulder strength is a major determinant of the CS and contributes 25 points. In the present study, mean strength score significantly decreased with age ($p<0.05$), and males had a statistically higher mean strength score than females ($p<0.05$).The strength scores decreased after the fifth decade. Yian et al. [8] also reported statistically higher mean abduction strength in male than in female participants, declining steadily after 40 years of age. In the present study, ROM scores did not change with advancing age in males although females experienced reduced internal rotation after the 5th decade. Significant detrimental effects of aging or sex on shoulder ROM were not proven in previous studies except by Yian et al. [8] who reported decreased ROM with age; however, the change was less than 12°. The lower internal rotation in the elderly female population in the current study could not be explained, however, this could be due to lower functional demand in older females as well as local cultural practices.

Left/Right Side Effects

Significant variations were not found in overall mean CSs between dominant and non-dominant sides as reported in prior studies [4,7,8], which was the reason both shoulders were evaluated in the present study. In addition, the practice of comparing the affected shoulder CS with the opposite shoulder CS can be misleading in shoulder patients because many patients have as-

Table 6. Comparison of the mean Constant scores between the current study and the previously reported Constant score data in different studies on different demographic populations

Age group (yr)	Male					Female				
	Constant et al. [4]	Yian et al. [8]	Katolik et al. [6]	Tavakkolizadeh et al. [7]	This study	Constant et al. [4]	Yian et al. [8]	Katolik et al. [6]	Tavakkolizadeh et al. [7]	This study
<20	-	-	-	94.5	86.7	-	-	-	85	86
21–30	98	94	95	94	87.2	97	86	88	85	83.8
31–40	93	94	95	94	86.9	90	86	87	86	81.7
41–50	92	93	96	94	85.2	80	85	86	86	82.1
51–60	90	91	94	92	84.3	73	83	84	86	80.7
61–70	83	90	92	91	81.4*	70	82	83	83	75.1*
71–80	75	86	88	78	-	69	81	81	79.5	-

*The mean score in our study was calculated for ≥60 year age group.

ymptomatic bilateral shoulder problems which can lead to a false sense of achieving the target CS in postoperative follow-up.

Occupation Effect

Individuals engaged in high-level activities had a higher mean CS than subjects engaged in low-level activities which could be explained because individuals who perform high-level activities have a higher functional demand that requires more muscle strength and shoulder ROM than individuals performing low-level activities. When evaluating the functional outcome of a treatment or surgery using the CS, occupational needs of the patients should also be considered. The normal CS in terms of the job profile of the participants was not assessed in any of the previous studies.

Limitations

The present study had several limitations. The sample size was relatively small. A statistically ideal normative data study requires randomly selected samples from the general population. Another limitation is the non-homogenous data due to the higher number of male participants that could have caused bias. In addition, participants were unequally distributed in the age groups which could create bias in the results. Despite these limitations, the data fairly represents the target population because the participants were from the general population compared with previous studies in which participants were attending a sports medicine clinic [6], resulting in a strong bias because athletes are expected to have better physical activity and shoulder function than the general population. The above-mentioned limitations should be addressed in future studies and the results of this study used as a basis in multicenter research that includes a larger cohort representative of diverse populations.

Conclusion

The results of the present study provide data for the CS in normal shoulders in a specific population and a statistical equation to calculate the expected score at any age. The calculated CS represents the target score to be achieved in a specific age- and sex-matched patient, thus, simplifying the assessment of intervention outcome. The adjusted score derived from our equation allows analysis and comparison of the outcome scores from different hospitals when the standard method of scoring is used. However, differences between the CS data in this study and previously published studies existed, indicating the importance of using normal data from the same population cohort of patients when reporting the outcomes. This is the first study in which normal CS was defined in age- and sex-matched local South Asian subjects without shoulder pathology. Data in the present study regarding age- and sex-adjusted CS can be incorporated in future multicenter studies to better understand and implement the results.

ORCID

Nitesh Gahlot https://orcid.org/0000-0001-7352-5228
Ankit Rai https://orcid.org/0000-0003-0356-8964
Jeshwanth Netaji https://orcid.org/0000-0001-8081-1863

REFERENCES

1. Kirkley A, Griffin S, Dainty K. Scoring systems for the functional assessment of the shoulder. Arthroscopy 2003;19:1109-20.
2. Fialka C, Oberleitner G, Stampfl P, Brannath W, Hexel M, Vécsei V. Modification of the Constant-Murley shoulder score-introduction of the individual relative Constant score individual shoulder assessment. Injury 2005;36:1159-65.
3. Constant CR, Gerber C, Emery RJ, Søjbjerg JO, Gohlke F, Boileau P. A review of the Constant score: modifications and guidelines for its use. J Shoulder Elbow Surg 2008;17:355-61.
4. Constant CR, Murley AH. A clinical method of functional assessment of the shoulder. Clin Orthop Relat Res 1987;(214):160-4.
5. Brinker MR, Cuomo JS, Popham GJ, O'Connor DP, Barrack RL. An examination of bias in shoulder scoring instruments among healthy collegiate and recreational athletes. J Shoulder Elbow Surg 2002;11:463-9.
6. Katolik LI, Romeo AA, Cole BJ, Verma NN, Hayden JK, Bach BR. Normalization of the Constant score. J Shoulder Elbow Surg 2005;14:279-85.
7. Tavakkolizadeh A, Ghassemi A, Colegate-Stone T, Latif A, Sinha J. Gender-specific Constant score correction for age. Knee Surg Sports Traumatol Arthrosc 2009;17:529-33.
8. Yian EH, Ramappa AJ, Arneberg O, Gerber C. The Constant score in normal shoulders. J Shoulder Elbow Surg 2005;14:128-33.
9. McLean JM, Awwad D, Lisle R, Besanko J, Shivakkumar D, Leith J. An international, multicenter cohort study comparing 6 shoulder clinical scores in an asymptomatic population. J Shoulder Elbow Surg 2018;27:306-14.
10. Imatani RJ, Hanlon JJ, Cady GW. Acute, complete acromioclavicular separation. J Bone Joint Surg Am 1975;57:328-32.
11. Bahrs C, Badke A, Rolauffs B, et al. Long-term results after non-plate head-preserving fixation of proximal humeral fractures.

 https://doi.org/10.5397/cise.2022.00864

Int Orthop 2010;34:883-9.
12. Steeves JA, Tudor-Locke C, Murphy RA, King GA, Fitzhugh EC, Harris TB. Classification of occupational activity categories using accelerometry: NHANES 2003-2004. Int J Behav Nutr Phys Act 2015;12:89.
13. Razmjou H, Holtby R, Christakis M, Axelrod T, Richards R. Impact of prosthetic design on clinical and radiologic outcomes of total shoulder arthroplasty: a prospective study. J Shoulder Elbow Surg 2013;22:206-14.
14. Hirschmann MT, Wind B, Amsler F, Gross T. Reliability of shoulder abduction strength measure for the Constant-Murley score. Clin Orthop Relat Res 2010;468:1565-71.
15. Kemp KA, Sheps DM, Beaupre LA, Styles-Tripp F, Luciak-Corea C, Balyk R. An evaluation of the responsiveness and discriminant validity of shoulder questionnaires among patients receiving surgical correction of shoulder instability. ScientificWorldJournal 2012;2012:410125.
16. Bankes MJ, Crossman JE, Emery RJ. A standard method of shoulder strength measurement for the Constant score with a spring balance. J Shoulder Elbow Surg 1998;7:116-21.
17. Yun YH, Jeong BJ, Seo MJ, Shin SJ. Simple method of evaluating the range of shoulder motion using body parts. Clin Should Elbow 2015;18:13-20.
18. Walton MJ, Walton JC, Honorez LA, Harding VF, Wallace WA. A comparison of methods for shoulder strength assessment and analysis of Constant score change in patients aged over fifty years in the United Kingdom. J Shoulder Elbow Surg 2007;16:285-9.
19. Bäckman E, Johansson V, Häger B, Sjöblom P, Henriksson KG. Isometric muscle strength and muscular endurance in normal persons aged between 17 and 70 years. Scand J Rehabil Med 1995;27:109-17.
20. Hughes RE, Johnson ME, O'Driscoll SW, An KN. Age-related changes in normal isometric shoulder strength. Am J Sports Med 1999;27:651-7.

Original Article

Clin Shoulder Elbow 2022;25(4):282-287
https://doi.org/10.5397/cise.2022.00885

CiSE
Clinics in Shoulder and Elbow

eISSN 2288-8721

Biomechanical investigation of arm position on deforming muscular forces in proximal humerus fractures

Christen E. Chalmers[1], David J. Wright[1], Nilay A. Patel[1], Hunter Hitchens[2], Michelle McGarry[3], Thay Q. Lee[3], John A. Scolaro[1]

[1]*Department of Orthopedic Surgery, University of California Irvine, Irvine, CA, USA*
[2]*Cornell University, Ithaca, NY, USA*
[3]*Orthopaedic Biomechanics Laboratory, Congress Medical Foundation, Pasadena, CA, USA*

Background: Muscular forces drive proximal humeral fracture deformity, yet it is unknown if arm position can help mitigate such forces. Our hypothesis was that glenohumeral abduction and humeral internal rotation decrease the pull of the supraspinatus and subscapularis muscles, minimizing varus fracture deformity.
Methods: A medial wedge osteotomy was performed in eight cadaveric shoulders to simulate a two-part fracture. The specimens were tested on a custom shoulder testing system. Humeral head varus was measured following physiologic muscle loading at neutral and 20° humeral internal rotation at both 0° and 20° glenohumeral abduction.
Results: There was a significant decrease in varus deformity caused by the subscapularis ($p<0.05$) at 20° abduction. Significantly increasing humeral internal rotation decreased varus deformity caused by the subscapularis ($p<0.05$) at both abduction angles and that caused by the supraspinatus ($p<0.05$) and infraspinatus ($p<0.05$) at 0° abduction only.
Conclusions: Postoperative shoulder abduction and internal rotation can be protective against varus failure following proximal humeral fracture fixation as these positions decrease tension on the supraspinatus and subscapularis muscles. Use of a resting sling that places the shoulder in this position should be considered.

Keywords: Proximal humeral fracture; Biomechanics; Rotator cuff; Shoulder joint

INTRODUCTION

Surgical fixation of proximal humeral fractures remains a clinical challenge and an area of ongoing investigation [1,2]. Alternative treatment options, including nonoperative management and arthroplasty, have been proposed for some fracture patterns and patient populations given the challenges experienced with surgical fracture fixation. Intra-operative techniques to augment fixation have been extensively explored and implemented to improve fracture fixation [3,4]. A paucity of research exists on post-surgical interventions and rehabilitation protocols that could potentially decrease the rates of fixation failure and malalignment.

Muscular forces acting on the shoulder have been shown to drive fracture deformity [5]. Muscle tension drives initial fracture

Received: February 22, 2022 Revised: April 12, 2022 Accepted: April 28, 2022
Correspondence to: John A. Scolaro
Department of Orthopedic Surgery, University of California Irvine, 101 The City Drive S Pavilion III, Building 29A Orange, CA 92868, USA
Tel: +1-714-456-7012, Fax: +1-714-456-7547, E-mail: jscolaro@hs.uci.edu, ORCID: https://orcid.org/0000-0001-7926-5017

Financial support: This study was funded by a grant from the Foundation for Orthopedic Trauma.
Conflict of interest: None.

displacement, counteracts fracture reduction efforts, is present at all points following surgery, and has a role in reduction failure. Initial work with a two-part proximal humeral fracture model demonstrated that the supraspinatus and subscapularis muscles are the primary and secondary drivers of varus fracture deformity with the arm in a neutral position. However, patients are typically placed in a sling or brace with the arm in variable abduction and/or internal rotation during the postoperative period.

The purpose of this study was to determine if arm position affected the deforming muscular forces of the shoulder. We specifically sought to identify if humeral abduction or internal rotation affected varus deformity. Our hypothesis was that glenohumeral abduction would mitigate deformity caused by the superior cuff muscles, while internal rotation would decrease varus fracture deformity caused by the anterior cuff muscles.

METHODS

No Institutional Review Board approval was required for this biomechanical laboratory study which did not require patient consent or involve patient protected health information.

Eight fresh-frozen cadaveric shoulder specimens from four female and four male donors (mean age, 64 years; range 48–72 years) were used. All subcutaneous tissue and muscle bellies were removed from specimens, while the coracoacromial ligament and tendinous insertions of the subscapularis, supraspinatus, infraspinatus, teres minor, and deltoid remained intact. A standard Krackow locking suture was placed through each tendon using No. 2 FiberWire (Arthrex, Naples, FL, USA). The humerus was transected 2 cm distal to the deltoid tuberosity, and the proximal humerus was disarticulated from the glenoid through the shoulder capsule. Rotator cuff repairs had been previously performed in some specimens and were evaluated and reinforced, if necessary. In two specimens, a full thickness single rotator cuff muscle tear was discovered during dissection. Therefore, an allograft tendon was attached via suture anchors to the anatomic footprint.

Next, a two-part fracture (AO/OTA 11A2.2) consisting of a head fragment and shaft fragment was created by first making a 1-cm medial wedge osteotomy in each specimen. The wedge extended two thirds of the medial-to-lateral diameter of the proximal humerus just distal to the humeral head articular surface. After creation of the medial wedge, the final one third of the osteotomy was completed through the lateral cortex in a linear fashion to complete the two-part fracture. By preserving cortical contact at the lateral aspect of the medial wedge osteotomy, the fracture model was able to be anatomically aligned after each testing trial. This created a consistent, reproducible starting position prior to muscle loading. To digitize the position of the humerus in each loading condition, a MicroScribe (Model G; Revware Inc., Raleigh, NC, USA) was used. Digitization reference points included six unicortical screws placed 1.5 cm apart on either side of the osteotomy along the lateral cortex of the proximal humerus (Fig. 1). One screw was placed in the coracoid and two screws were placed in the acromion for use as constant reference points. Finally, two elastic bands were placed parallel to each other, around the lateral reference screws adjacent to the osteotomy site. The purpose of these bands was to maintain stable cortical contact between the proximal and distal fragments at the lateral one-third of the osteotomy, while still allowing for motion in all planes between the humeral head and shaft.

Each specimen was mounted with the scapula fixed to a metal plate and positioned at 0° abduction and 20° anterior tilt in the sagittal plane on a custom, validated shoulder testing system (Fig. 2) [6]. The humeral shaft was fixed to an intramedullary rod connected to a 360° goniometer sensor (Novotechnik U.S. Inc., Southborough, MA, USA) and secured to a hemi-

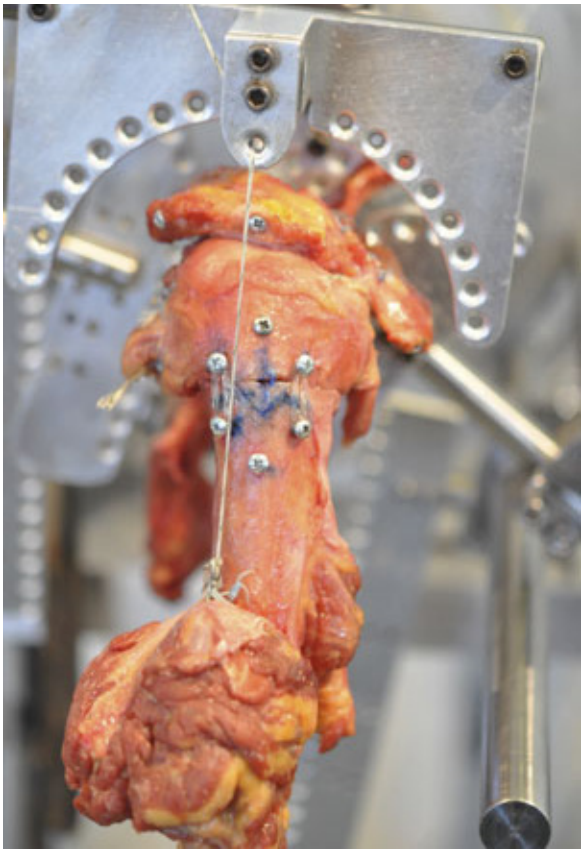

Fig. 1. Lateral view of the proximal humerus and digitization reference screws surrounding osteotomy along the lateral cortex.



Fig. 2. Lateral view of the proximal humerus and scapula mounted on the custom shoulder testing jig.

spheric arc that allowed for varying angles of abduction and rotation. Glenoid inclination was measured, and 0° glenohumeral abduction was set to match glenoid inclination. Neutral humeral axial rotation was set with the humeral head concentrically aligned within the glenoid cavity.

Physiologic muscle loading during testing was simulated using braided low-stretch fishing line (Izorline, Paramount, CA, USA) tied to the Krakow sutures at the musculotendinous junctions. The lines were fed through adjustable pulleys on the shoulder testing system, which reproduced the native force vector generated by each muscle *in vivo*. To maintain concentric positioning of the humeral head, a balanced muscle loading consisting of the following loads was applied: subscapularis, 5 N; infraspinatus, 2.5 N; teres minor, 2.5 N; deltoid, 5 N. Due to the presence of the medial wedge, any load applied to the supraspinatus caused the humeral head to fall into varus deformity, so the supraspinatus was not included in the balanced muscle load. For unbalanced individual loading, each muscle was tested by applying an additional 2.5 N, 5 N, and 7.5 N to the balanced load condition. To evaluate the role of glenohumeral abduction and humeral internal rotation on varus fracture deformity based on shoulder musculature, measurements were performed following muscle loading at neutral and 20° internal rotation and at 0° and 20° glenohumeral abduction.

All measurements were performed twice in all testing conditions, and the average of these values was used in data analysis. The primary outcome of this study was impact of glenohumeral abduction on the deforming muscular forces contributing to varus collapse (Fig. 3). The secondary outcome was impact of humeral internal rotation on varus collapse. A Shapiro-Wilk Normality test was performed, and the data were deemed not normal. Thus, a non-parametric Wilcoxon signed-rank test was used to compare varus collapse between testing conditions. Data are presented as mean ± standard error of the mean. The threshold for statistical significance was defined as $p < 0.05$.

RESULTS

Primary Outcome

At a load of 2.5 N or 5 N, there were no significant differences in varus fracture deformity caused by the rotator cuff musculature or deltoid when comparing glenohumeral abduction. At a load of 7.5 N, with the shoulder internally rotated, there was a significant decrease in varus fracture deformity caused by the subscapularis (13.8° ± 3.1° vs. 12.0° ± 2.2°, $p = 0.018$). There were no significant differences in varus deformity with changing abduction angle caused by the infraspinatus, teres minor, supraspinatus, or deltoid (Figs. 4-6).

Secondary Outcomes

At a load of 2.5 N, humeral internal rotation significantly decreased varus fracture deformity caused by the supraspinatus (13.6° ± 3.5° vs. 6.9° ± 2.8° varus deformity, $p = 0.021$) and infraspinatus (9.5° ± 3.3° vs. 5.1° ± 2.6° varus deformity, $p = 0.036$) at 0° glenohumeral abduction but not at 20° glenohumeral abduction. Alternatively, at 20° glenohumeral abduction, humeral head internal rotation significantly decreased varus deformity caused by the subscapularis (6.3° ± 3.2° vs. 3.4° ± 2.0° varus deformity, $p = 0.028$); this did not occur at 0° glenohumeral abduction. There were no significant differences in varus deformity with humeral internal rotation caused by the teres minor or deltoid at a load of 2.5N (Figs. 4-6).

At a load of 5N, humeral internal rotation significantly de-

https://doi.org/10.5397/cise.2022.00885

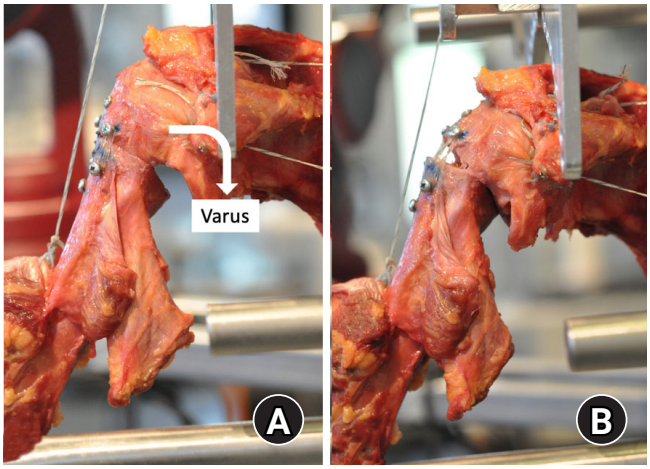

Fig. 3. Anterior to posterior view of the two-part proximal humerus fracture with defining direction of varus fracture deformity (A). Varus fracture deformity produced by loading the supraspinatus (B).

creased varus deformity caused by the subscapularis at both 0° (15.5°±1.6° vs. 6.1°±2.2° varus deformity, p=0.017) and 20° (12.9±2.6° vs. 8.4±2.0° varus deformity, p=0.018) glenohumeral abduction. Humeral head internal rotation also significantly decreased varus deformity caused by the supraspinatus (28.1°±1.1° vs. 20.2°±3.8° varus deformity, p=0.036) at 0° but not 20° glenohumeral abduction. There were no significant differences in varus deformity caused by the infraspinatus, teres minor, or deltoid with humeral internal rotation at a load of 5 N (Figs. 4-6).

At a load of 7.5 N, humeral internal rotation significantly decreased varus deformity caused by the subscapularis at both 0° (21.7°±3.1° vs. 13.8°±3.1° varus deformity, p=0.028) and 20° (14.5°±2.7° vs. 12.0°±2.2° varus deformity, p=0.028) glenohumeral abduction. There were no significant differences in varus deformity with humeral internal rotation caused by the supraspi-

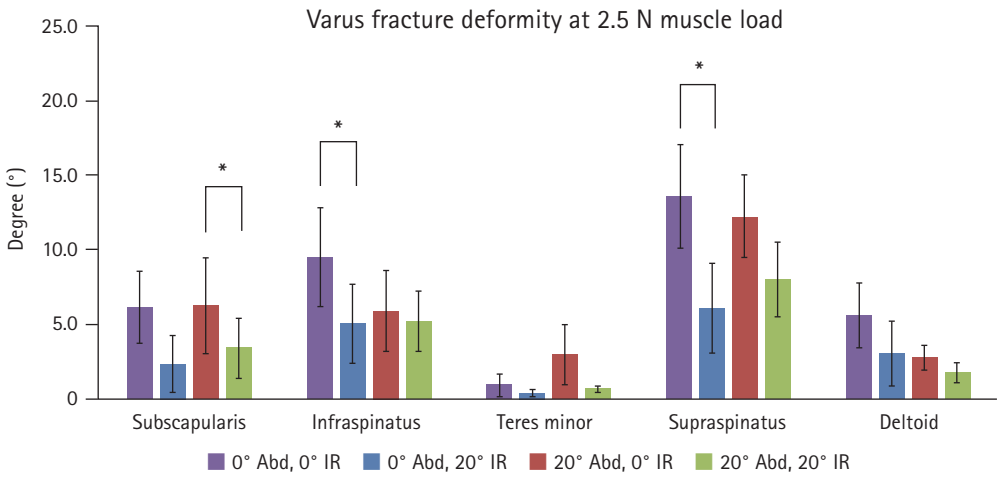

Fig. 4. Relative varus fracture deformity produced by the rotator cuff musculature and deltoid with a load of 2.5 N at 0° and 20° glenohumeral abduction and at neutral and 20° internal rotation. Abd: abduction, IR: internal rotation. *p<0.05.

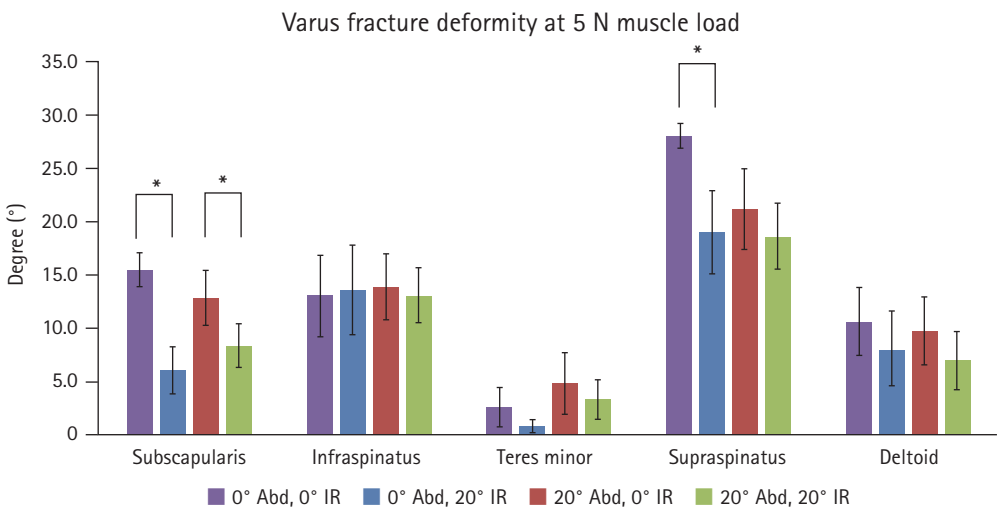

Fig. 5. Relative varus fracture deformity produced by the rotator cuff musculature and deltoid with a load of 5 N at 0° and 20° glenohumeral abduction and at neutral and 20° internal rotation. Abd: abduction, IR: internal rotation. *p<0.05.

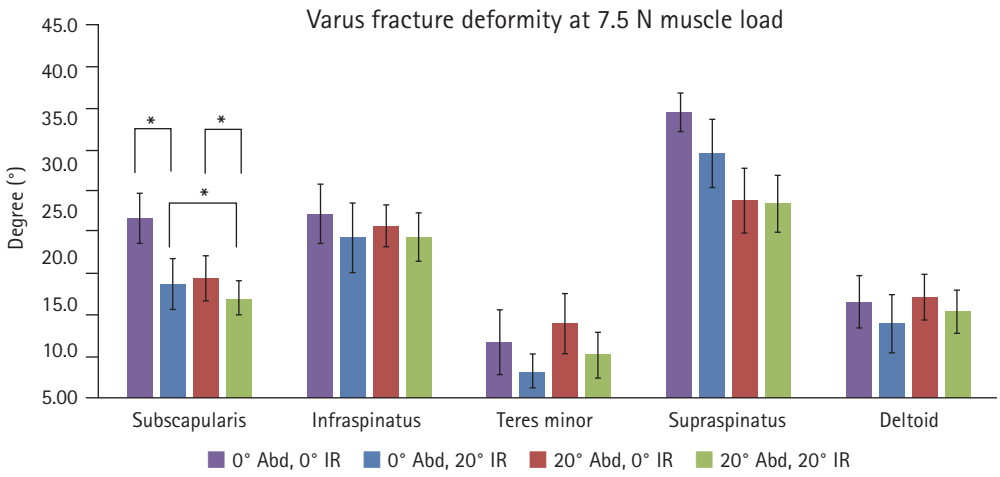

Fig. 6. Relative varus fracture deformity produced by the rotator cuff musculature and deltoid with a load of 7.5 N at 0° and 20° glenohumeral abduction and at neutral and 20° internal rotation. Abd: abduction, IR: internal rotation. *p<0.05.

natus, infraspinatus, teres minor, or deltoid at a load of 7.5 N (Figs. 4-6).

DISCUSSION

Arm position following proximal humerus fracture fixation is an uncommon consideration to decrease the rate of fixation failure. The shoulder musculature has been shown to induce humeral head deformity after fracture, specifically in the varus due to the pull of the supraspinatus and subscapularis [5]. Internal rotation was protective of varus deformity driven by the subscapularis at all loads in 20° of abduction and the supraspinatus at 2.5 N and 5 N in 0° of abduction. While we hypothesized that glenohumeral abduction would mitigate deformity caused by the superior cuff muscles, internal rotation appeared to have stronger impact on decreasing varus fracture deformity caused by both the anterior and superior cuff muscles. Ultimately, our results demonstrate that the arm positioned in abduction and internal rotation decreases tension on the supraspinatus and subscapularis, resulting in decreased varus deformity induced by these muscles.

Little attention has been given to factors within the postoperative period that might improve results of fracture repair. Some studies have researched mobilization protocols following non-operative management of proximal humerus fractures [7-9]. Fewer studies have looked at the effect of postoperative arm position following fracture fixation in the shoulder. Chen et al. [10] recently described their results using a custom neutral position shoulder and elbow sling following proximal humeral fracture fixation. They reported no increase in adverse events or loss of fixation but did report improved functional scores with their custom postoperative sling.

Biomechanical studies have commonly induced varus failure in proximal humerus models by placing a load on the cranial aspect of the humeral head [11-13]. This force can produce varus in the laboratory setting but is dissimilar to any load experienced by the humeral head *in vivo*. Many prior investigations have utilized a medial wedge, gap osteotomy, or gap to replicate comminution at the medial calcar, a factor that has been shown to predict failure [14]. Following surgery, apart from a new trauma, activation of the rotator cuff muscles and glenohumeral motion/contact contribute to early varus collapse and fixation failure. Our study set out to determine if arm position affected the deforming forces of the shoulder musculature in our two-part proximal humeral fracture model. Information could then potentially be used to guide postoperative protocols to minimize fixation failure.

The results of this biomechanical study provide information to support the position of the shoulder in internal rotation and abduction as a protective factor against varus failure following proximal humeral fracture fixation, especially for fractures at risk of fixation failure. In the clinical setting, consideration should be given to use of a resting sling that holds the shoulder in this position. Similarly, passive and active motion protocols can potentially utilize this information to mobilize the shoulder in a position that decreases the deforming pull of rotator cuff muscles.

Limitations of this study include the biomechanical investigation design that did not include concurrent proximal humeral fixation. Additionally, in some specimens, rotator cuff repairs had been previously performed, and two specimens had a full-thickness single rotator cuff muscle tear. However, these tendon repairs were re-enforced or reconstructed with an allograft tendon anchored to the anatomic footprint as defined by prior

https://doi.org/10.5397/cise.2022.00885

studies [15]. In addition, the fracture model was not stabilized with plates/screws, and arm position was not tested dynamically. We have recently established this physiologically relevant biomechanical fracture model, and future work will include evaluation of proximal humerus fracture characteristics as well as fixation constructs in order to improve the care of these injuries.

In this biomechanical study of a two-part proximal humerus fracture with an incompetent medial calcar, humeral abduction resulted in significantly less varus fracture deformity caused by the subscapularis. Increasing humeral internal rotation significantly decreased varus fracture deformity caused by primarily the subscapularis and supraspinatus. While early motion protocols are important following fracture surgery, postoperative positioning of the shoulder in abduction and internal rotation can be protective against varus failure for fractures at risk for loss of fixation. This position decreases the tension generated by rotator cuff muscles that drive varus deformity.

ORCID

Christen E. Chalmers https://orcid.org/0000-0002-5049-610X
David J. Wright https://orcid.org/0000-0001-5952-2602
John A. Scolaro https://orcid.org/0000-0001-7926-5017

REFERENCES

1. Rangan A, Handoll H, Brealey S, et al. Surgical vs nonsurgical treatment of adults with displaced fractures of the proximal humerus: the PROFHER randomized clinical trial. JAMA 2015;313:1037-47.
2. Pizzo RA, Gianakos AL, Haring RS, et al. Are arthroplasty procedures really better in the treatment of complex proximal humerus fractures?: a comprehensive meta-analysis and systematic review. J Orthop Trauma 2021;35:111-9.
3. Biermann N, Prall WC, Böcker W, Mayr HO, Haasters F. Augmentation of plate osteosynthesis for proximal humeral fractures: a systematic review of current biomechanical and clinical studies. Arch Orthop Trauma Surg 2019;139:1075-99.
4. Davids S, Allen D, Desarno M, Endres NK, Bartlett C, Shafritz A. Comparison of locked plating of varus displaced proximal humeral fractures with and without fibula allograft augmentation. J Orthop Trauma 2020;34:186-92.
5. Chalmers CE, Wright DJ, Patel N, et al. Muscular forces responsible for proximal humeral deformity after fracture. J Orthop Trauma 2022;36:e18-23.
6. Lee YS, Lee TQ. Specimen-specific method for quantifying glenohumeral joint kinematics. Ann Biomed Eng 2010;38:3226-36.
7. Aguado HJ, Ariño B, Moreno-Mateo F, et al. Does an early mobilization and immediate home-based self-therapy exercise program displace proximal humeral fractures in conservative treatment?: observational study. J Shoulder Elbow Surg 2018;27:2021-9.
8. Carbone S, Razzano C, Albino P, Mezzoprete R. Immediate intensive mobilization compared with immediate conventional mobilization for the impacted osteoporotic conservatively treated proximal humeral fracture: a randomized controlled trial. Musculoskelet Surg 2017;101(Suppl 2):137-43.
9. Lefevre-Colau MM, Babinet A, Fayad F, et al. Immediate mobilization compared with conventional immobilization for the impacted nonoperatively treated proximal humeral fracture: a randomized controlled trial. J Bone Joint Surg Am 2007;89:2582-90.
10. Chen X, Yu ZX, Wang HY, et al. Proximal humeral internal locking plate combined with a custom neutral-position shoulder and elbow sling for proximal humerus fractures: a randomized study. Medicine (Baltimore) 2019;98:e15271.
11. Bai L, Fu Z, An S, Zhang P, Zhang D, Jiang B. Effect of calcar screw use in surgical neck fractures of the proximal humerus with unstable medial support: a biomechanical study. J Orthop Trauma 2014;28:452-7.
12. Rusimov L, Zderic I, Ciric D, et al. Does supplemental intramedullary grafting increase stability of plated proximal humerus fractures. J Orthop Trauma 2019;33:196-202.
13. Hast MW, Chin M, Schmidt EC, Sanville J, Van Osten GK, Mehta S. Mechanical effects of bone substitute and far-cortical locking techniques in 2-part proximal humerus fracture reconstruction: a cadaveric study. J Orthop Trauma 2020;34:199-205.
14. Osterhoff G, Hoch A, Wanner GA, Simmen HP, Werner CM. Calcar comminution as prognostic factor of clinical outcome after locking plate fixation of proximal humeral fractures. Injury 2012;43:1651-6.
15. Park MC, ElAttrache NS, Tibone JE, Ahmad CS, Jun BJ, Lee TQ. Part I: footprint contact characteristics for a transosseous-equivalent rotator cuff repair technique compared with a double-row repair technique. J Shoulder Elbow Surg 2007;16:461-8.

Original Article

Clin Shoulder Elbow 2022;25(4):288-295
https://doi.org/10.5397/cise.2022.00892

CiSE
Clinics in Shoulder and Elbow

eISSN 2288-8721

Good functional results with open reduction and internal fixation for locked posterior shoulder fracture–dislocation: a case series

Nicolás Morán[1,2], Michael Marsalli[3], Mauricio Vargas[4], Joaquín De la Paz[4], Marco Cartaya[4]

[1]*Shoulder and Elbow Unit, Orthopedic Department, Hospital Militar de Santiago, Santiago, Chile*
[2]*Orthopedic Department, Clínica RedSalud Santiago, Santiago, Chile*
[3]*Department of Orthopedic Surgery, Clínica Universidad de Los Andes, Santiago, Chile*
[4]*Shoulder Surgery Unit, Orthopedic Department, Hospital del Trabajador, Santiago, Chile*

Background: There is no standardized therapeutic strategy for locked posterior shoulder fracture–dislocation (PSFD), and no consensus exists on the analysis of preoperative factors. This retrospective study aimed to evaluate functional results and complications in a series of PSFD cases managed with open surgical treatment.
Methods: Patients diagnosed with locked PSFD who underwent open surgical treatment with reduction and osteosynthesis between April 2016 and March 2020 were included. All participants were treated with open reduction and internal fixation. Functional assessment used the modified University of California, Los Angeles (UCLA) mod scale, American Shoulder and Elbow Surgeons (ASES) questionnaire, subjective shoulder value (SSV), and visual analog scale (VAS). Complications were evaluated clinically and radiologically by X-ray and computed tomography.
Results: Twelve shoulders were included (11 patients; mean age, 40.6 years; range, 19– 62 years). The mean follow-up duration was 23.3 months (range, 12–63 months). The UCLA mod, ASES, SSV, and VAS scores were 29.1±3.7, 81.6±13.5, 78±14.8, and 1.2±1.4 points, respectively. The overall complication rate was 16.6%, with one case of post-traumatic stiffness, 1 case of chronic pain, and no cases of avascular necrosis.
Conclusions: Open surgical treatment of locked PSFD can achieve good functional results. A correct understanding of these injuries and good preoperative planning helped us to achieve a low rate of complications.

Keywords: Posterior shoulder dislocation; Posterior shoulder fracture–dislocation; Posterior instability; Locked posterior shoulder dislocation

INTRODUCTION

Locked posterior shoulder dislocation (LPSD) is a rare injury [1] associated with electric shocks, seizures, or high-impact injuries [2-4]. LPSD can be underdiagnosed because the clinical and imaging patterns may not be as clear as those of anterior shoulder dislocation [5], which unfortunately has a negative effect on prognosis. The most common associated injury is an impaction

Received: February 23, 2022 Revised: April 13, 2022 Accepted: April 15, 2022
Correspondence to: Nicolás Morán
Shoulder and Elbow Surgery Unit, Orthopedic Department, Hospital Militar de Santiago, Av. Fernando Castillo Velasco 9100, La Reina, Santiago 7880035, Chile
Tel: +56-9932-3402, E-mail: nimoran@miuandes.cl, ORCID: https://orcid.org/0000-0003-3705-8022

Financial support: None.
Conflict of interest: None.

fracture of the anterior humeral articular surface, known as "reverse Hill-Sachs (RHS)," also called a simple posterior shoulder fracture–dislocation (PSFD). Cases involving a fracture of the anatomic/surgical neck or tuberosities are considered complex PSFD [2,4,6-8].

The most critical factors for therapeutic planning for a PSFD are the size of the RHS lesion, temporality, and type of associated fracture [9]. However, the analysis of these factors remains controversial [4]. Correct measurement of an RHS lesion is still under discussion [10,11]. This allows classification of joint involvement according to size (mild, <25%; moderate, 25%–50%; and severe, >50%) to guide the choice of treatment option. The time from injury has also been defined in various ways in the literature. According to the European Federation of National Associations of Orthopaedics and Traumatology [12], for an "acute" injury, the time from injury to surgery (TFIS) should be <3 weeks from the initial trauma; for a "neglected" injury, the time should be 3–6 weeks; and, for a "chronic" injury, the time should be >6 weeks [7,13]. Finally, management of associated fractures adds complexity and is still under discussion among surgeons [2,4,14]. For these reasons, multiple treatment options have been described for these patients (e.g., reverse fill, modified McLaughlin, auto/allograft, arthroplasty) [4,7,12,15,16]. To date, there is no standardized therapeutic strategy, and no consensus has been reached on the analysis of preoperative factors due to the lack of cohort studies with a high level of evidence.

The primary aim of this study was to evaluate the functional outcomes of a case series of patients treated for locked PSFD with open reduction and internal fixation (ORIF). The secondary aim of this study was to describe the incidence of complications and the re-intervention rate in these patients. The study hypothesis was that good functional results and a low rate of complications can be achieved with early and standardized open surgical treatment.

METHODS

Approval for this study was obtained from the Ethics Committee of Hospital del Trabajador. The procedures used in this study adhered to the tenets of the Declaration of Helsinki. All patients provided informed written consent for participation in the study and eventual publication.

Demographic Characteristics of the Patients

This was a retrospective study. Between April 2016 and March 2020, 12 shoulders with locked PSFD were admitted to our institution (level I trauma center). The inclusion criteria were as follows: (1) acute first-time locked PSFD, (2) underwent ORIF with osteosynthesis, (3) age >18 years, (4) signed informed consent for study participation, and (5) had ≥12 months of follow-up data available. The exclusion criteria were as follows: (1) acute first-time posterior instability event involving a subluxation without the engagement of the humeral head or spontaneous reduction, (2) recurrent dynamic posterior instability, (3) chronic static posterior glenohumeral instability with degenerative changes, and (4) irreparable fracture candidate for a prosthesis [8]. Data were collected from the pre- and postoperative registries of the study hospital. Table 1 presents the evaluated demographic characteristics.

Intervention

All patients had an acute, locked PSFD at the time of their initial evaluation at the emergency department. Patients underwent shoulder radiography (anteroposterior and outlet views) and computed tomography (CT) imaging of the injured shoulder for initial assessment and preoperative planning. A closed reduction was not successful or was not attempted because patients had an associated proximal humeral fracture or an RHS lesion affecting >25% of the humeral head articular surface with a high risk of fracture propagation. For these reasons, ORIF with osteosynthesis was indicated in all included cases.

Surgical Technique

The procedure was performed under general anesthesia and an interscalene block with the patient in a beach chair position. A standard deltopectoral approach was used for all patients. In some cases, when open reduction was difficult, a posterior arthroscopic portal was made to insert a spatula until the humeral head was felt. The spatula was slid in close to the humeral head until contact with the posterior glenoid wall was achieved. The procedure could be performed under fluoroscopy. The humerus

Table 1. Demographic characteristics

Variable	Value
Age (yr)	40.6 (19–62)
Male sex	12 (100)
Injury mechanism	
Direct trauma	8 (66.7)
Electrocution	3 (25)
Seizure	1 (8.3)
Side affected, right	7 (58)
Follow-up (mo)	23.3 (12–63)
TFIS (day)	1 (0–55)

Values are presented as median (range) or number (%).
TFIS: median time from injury to surgery.

was internally rotated to create a gap to insert the spatula between the posterior glenoid rim and the humeral head. Once the spatula came to sit on the posterior glenoid rim, it could act as a lever, using the glenoid as a fulcrum, to push the head laterally to unlock it. Gentle external rotation was performed so that the humeral head could glide over the spatula, and the joint was reduced (Fig. 1). Then, according to preoperative imaging planning and intraoperative findings, definitive surgical treatment was performed to achieve joint reconstruction. If there was a significant RHS (>25% by McLaughlin [16]) (Fig. 2), a joint exploration of the articular surface was performed. Joint exposure was performed through the lesser tuberosity (LT) fracture or osteotomy of the LT in patients without an LT fracture (Fig. 2). Any significant articular head fragment was disimpacted, anatomically reduced, and fixed with headless cannulated compression screws (Fig. 3). If an anterior residual humeral head defect remained after disimpaction of the articular surface, it was filled with the subscapularis (SSC) tendon or medialization of the LT (modified McLaughlin [16,17]) with or without the use of complementary allograft bone chips. Fixation of the LT was performed with 3.5-mm cancellous screws or 4.75–5.5-mm titanium anchors (Fig. 4). Finally, if there was significant displacement of a greater-tuberosity fracture and/or neck fracture, a proximal humerus-locked plate was added (Fig. 4).

After surgery, all patients were placed in a neutral-rotation shoulder-immobilization device for 4–6 weeks. Pendulum exer-

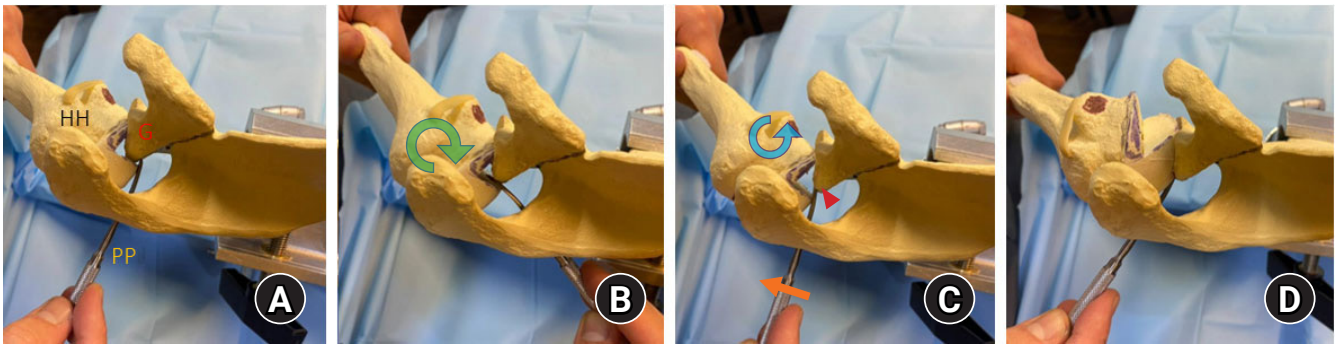

Fig. 1. Left shoulder, superior view. (A) A classic posterior arthroscopic portal is made to allow insertion of a spatula until the humeral head (HH) is felt; then, the spatula is slid in close to the humeral cartilage until contact with the posterior glenoid (G) wall is achieved. (B) The humerus is internally rotated to create a gap to insert the spatula between the posterior glenoid rim and the HH. (C) The spatula sits on the posterior glenoid rim so that it can act as a second-class lever, using the glenoid as the fulcrum to push the head laterally while gentle external rotation is performed, so the HH can glide over the spatula. (D) The joint was reduced. Green arrow, internal rotation; blue arrow, external rotation; arrowhead, fulcrum; orange arrow, effort. PP: posterior portal.

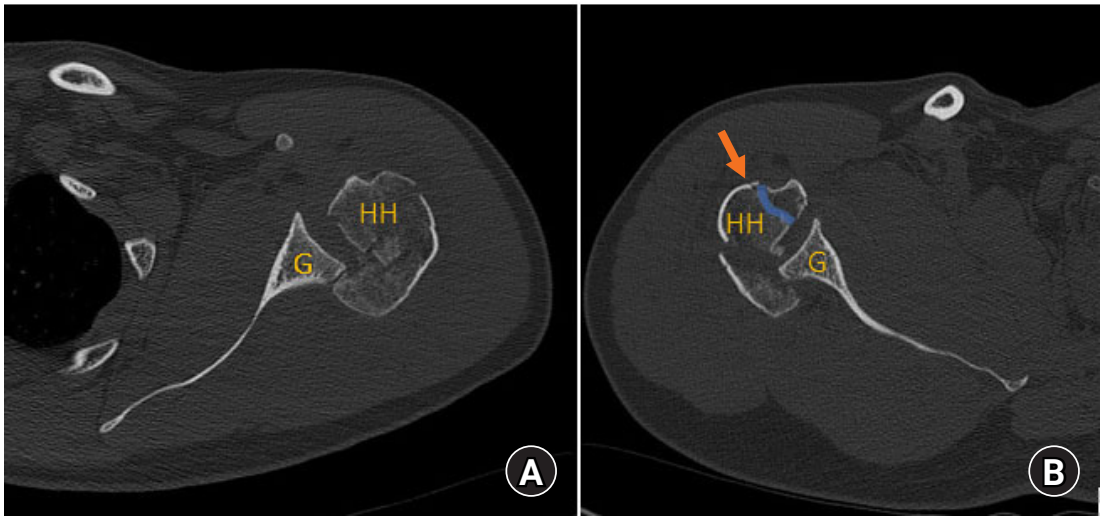

Fig. 2. (A) Axial view of computed tomography of a left shoulder showing a posterior shoulder fracture–dislocation with significant reverse Hill-Sachs of 50%. (B) Axial view of computed tomography of a right shoulder showing the entry point for joint exploration (orange arrow) of a posterior locked dislocation when a lesser tuberosity fracture is present (blue line). HH: humeral head, G: glenoid.

https://doi.org/10.5397/cise.2022.00892

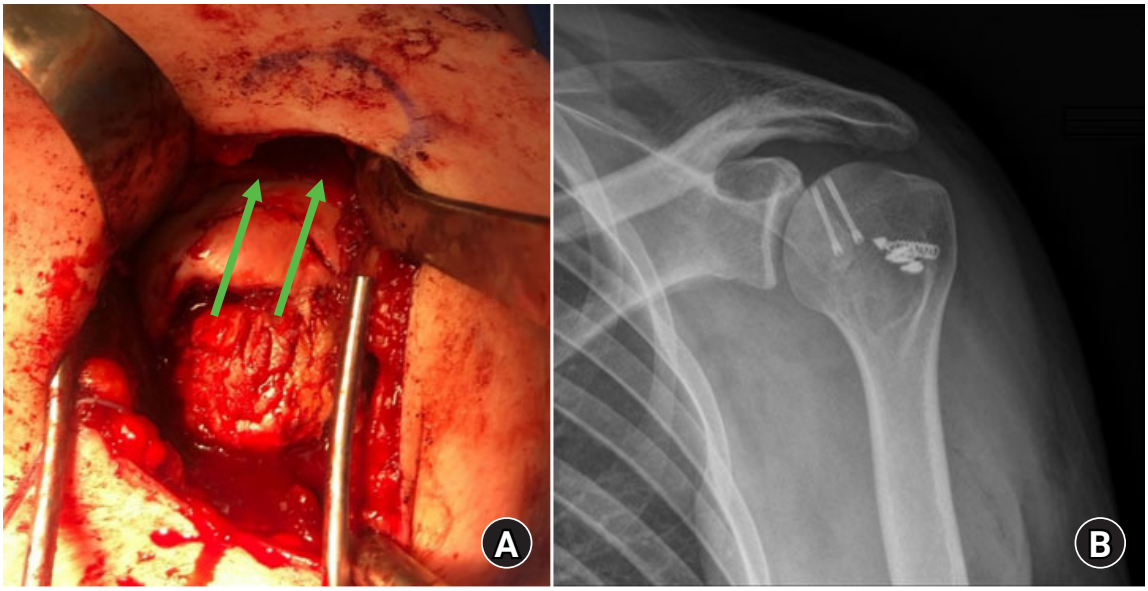

Fig. 3. (A) Intraoperative photo of a left shoulder through a deltopectoral approach showing humeral articular surface reduction and headless screws direction (green arrows). (B) Left shoulder X-rays showing postoperative anatomical reduction and fixation.

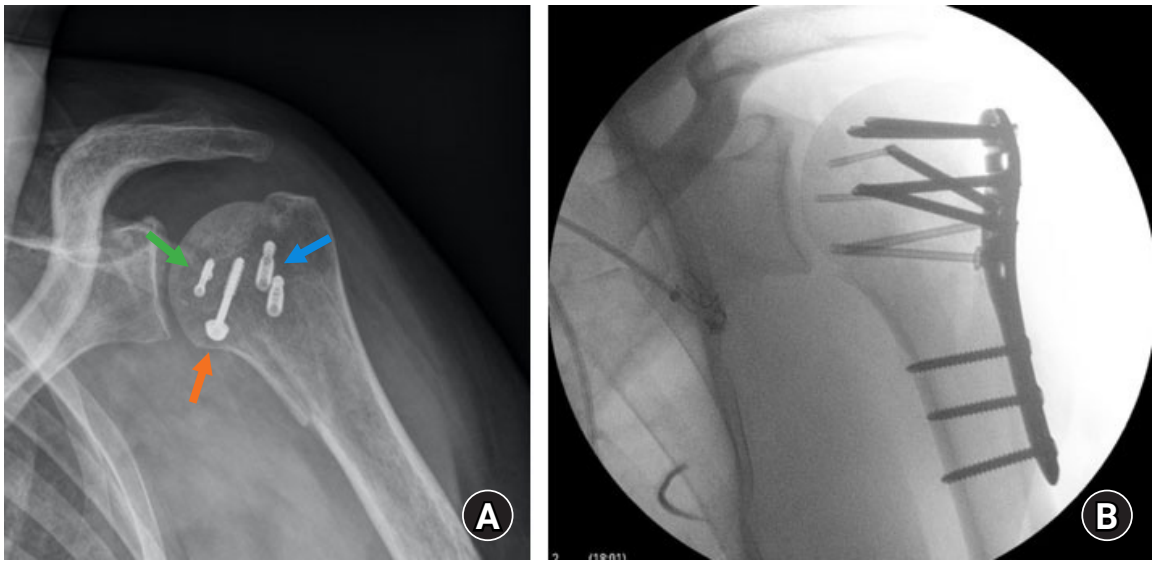

Fig. 4. (A) Left shoulder X-ray showing headless compression screws for articular surface reduction (green arrow), a 4.0-mm cancellous screw for modified McLaughlin fixation (orange arrow), and knotless suture anchors for subscapularis tendon reinforcement (blue arrow). (B) Left shoulder postoperative X-ray showing the use of a PHILOS (DePuy Synthes, Raynham, MA, USA) plate to fix an associated greater-tuberosity fracture on top of the articular reduction with headless cannulated screws.

cises were started at 2 weeks of surgery passive mobilization was started at 4 weeks, and active exercises were started 8 weeks after surgery, respectively. There were no differences in the postoperative rehabilitation program according to the type of fracture.

Outcome Measurements

The clinical outcomes were evaluated at the end of the follow-up. We used the modified University of California, Los Angeles (UCLA) mod scoring system, American Shoulder and Elbow Surgeons (ASES) questionnaire, subjective shoulder value, and visual analog scale (VAS). Clinically, the following complications were evaluated: reluxation, postoperative neurovascular injuries, and reoperation rate. Imaging follow-up was performed using shoulder radiographs at 6 and 12 months. The variables registered were failed osteosynthesis, varus collapse, avascular necrosis (AVN), and non-union. If necessary, during follow-up, a new

CT scan was requested by the surgeon. AVN of the humeral head was classified according to the system reported by Cushner and Friedman [18], and non-union was defined as a complete absence of trabecular bone formation or cortical continuity.

Statistical Analysis

Data were analyzed using the IBM SPSS ver. 25 (IBM Corp., Armonk, NY, USA). The Shapiro-Wilk test was used to verify the normal distribution of quantitative variables. The correlation between the preoperative variables (age and TFIS) and functional scores was analyzed using Pearson's coefficient for parametric variables and Spearman's ρ for non-parametric variables. An independent two-sample t-test was used to identify any significant mean difference in functional scores according to preoperative variables like laterality of the injury, dominant side injury, RHS, and articular bone fragment. The significance level was set at $p = 0.05$.

RESULTS

Twelve shoulders (11 patients) were included in this study, with a mean age of 40.6 years (range, 19–62 years). The mean follow-up period was 23.3 months (range, 12–63 months). The most frequent mechanism of injury was high-energy trauma (car/motorcycle accident and fall from a height). Eleven (91.6%) patients were treated in the acute stage after the initial injury. Eight of these patients (66.7%) underwent surgery between days 0–2, and the other 4 underwent surgery on days 12, 14, 17, and 55, respectively.

Table 2 describes the patterns of injury and surgical treatment performed for each patient. Ten patients had complex PSFD. RHS injury of >25% was present in nine cases, and only 1 patient had a glenoid defect, which was found to be non-significant (<20%). At the 12-month follow-up visit, 10 patients (83.3%) completed a clinical evaluation with functional scores (Table 3).

No significant correlations were found between age, TFIS, and functional scores. Moreover, no significant mean differences were found in scores according to preoperative variables (laterality of the injury, dominant-side injury, and presence of articular bone fragments). The overall complication rate was 16.6%. One patient had post-traumatic stiffness that required plate removal and joint release, and another patient developed chronic pain that required permanent management from the chronic pain unit. No other re-interventions were performed. No cases of reluxation, hardware failure, AVN, varus collapse, non-union, or neurological or vascular injury were reported (Table 3).

Table 2. Injury patterns and surgical treatment

Patient	TFIS (day)	Simple/ complex pattern	Tuberosities/ neck extension	Posterior percutaneous portal reduction	Joint fragment	Joint exploration	Joint reconstruction with headless screw	Fixation of LT	Residual HS defect filled	PH locked plate
1	0	Complex	GT, SNF	No	No	No	No	No	No	Yes
2	12	Complex	LT	Yes	Yes	Through the fracture	Yes	Screw	No	Yes
3	1	Complex	GT, LT, SNF	No	No	Through the fracture	No	Screw	McLaughlin	No
4	1	Complex	GT, LT, SNF	Yes	No	Through the fracture	No	Screw	No	Yes
5 (R)	2	Complex	GT, LT, SNF	Yes	Yes	Through the fracture	Yes	Screw	No	Yes
5 (L)	2	Complex	GT, LT	Yes	Yes	Through the fracture	Yes	screw	No	No
6	1	Complex	GT, LT, SNF	Yes	Yes	Through the fracture	Yes	screw	No	Yes
7	1	Complex	GT	Yes	No	No	No	No	No	Yes
8	14	Simple	Only RHS	Yes	No	Osteotomy LT	No	Anchor	Modified McLaughlin	No
9	55	Complex	GT, SNF	Yes	Yes	Osteotomy LT	Yes	Anchor	Modified McLaughlin	No
10	17	Simple	Only RHS	Yes	Yes	Osteotomy LT	Yes	Anchor	Modified McLaughlin	No
11	1	Complex	GT	Yes	No	No	No	No	No	Yes

TFIS: time from injury to surgery, LT: lesser tuberosity, HS: Hill–Sachs, PH: proximal humeral, GT: greater tuberosity, SNF: surgical neck fracture, R: right side, L: left side, RHS: reverse Hill–Sachs.

https://doi.org/10.5397/cise.2022.00892

Table 3. Functional outcomes and complications

Variable	Value
Functional scale	
ASES score	81.6 ± 13.5 (58–96)
VAS score	1.2 ± 1.4 (0–4)
Modified UCLA scoring system score	29.1 ± 3.7 (24–34)
SSV score	78 ± 14.8 (50–95)
Satisfaction (yes)	100 (10)
Complication	
Post traumatic stiffness	8.3 (1)
Chronic pain	8.3 (1)
Others*	-
Re-intervention	8.3 (1)

Values are presented as mean ± standard deviation (range) or percent (number).
ASES: American Shoulder and Elbow Surgeons, VAS: visual analog scale, UCLA: University of California, Los Angeles, SSV: subjective shoulder value.
*Includes reluxation, hardware failure, avascular necrosis, varus collapse, non-union, and neurological and vascular injuries.

DISCUSSION

The most important finding of this study was that good functional results and a low rate of complications can be achieved with open surgical treatment for locked PSFD. A correct understanding of these injuries and preoperative planning allowed us to apply an adequate surgical technique and obtain good results. There has been increasing interest in posterior shoulder dislocation in recent years. Moroder and Scheibel [8] described a new ABC classification system, including mechanism, imaging, and temporality. Our study only included patients with locked PSFD classified as A2 according to the ABC classification. Most cases were locked dislocations due to high-energy trauma and were associated with a proximal humeral fracture (complex PSFD). However, fractures associated with complex PSFD may facilitate an earlier diagnosis and treatment [7].

In a recent study by Park et al. [1], four of six patients with locked PSFD underwent ORIF, obtaining average Constant, ASES, and VAS scores of 67, 67.5, and 2 points, respectively, after a mean follow-up period of 26.2 months. In another study [3], 13 patients with locked PSFD who underwent a modified McLaughlin procedure had a mean UCLA score of 25.5 points at the end of a mean follow-up period of 12.5 months. Excellent/good results have been reported in surgical treatment of simple locked PSFD in 62%–82% of patients at mid-term follow-up [5,9]. Liu et al. [19] analyzed 18 patients with locked PSFD associated with only an LT fracture who underwent ORIF of the LT and found that a longer TFIS had a negative effect on functional scores. We were unable to demonstrate that the TFIS had a negative effect because of the limited number of participants in our study, with only one patient being treated surgically as a chronic case. Finally, excellent functional results were published by Banerjee et al. [20], who studied seven patients with acute locked PSFD who underwent a modified McLaughlin procedure, obtaining average Constant and ASES scores of 92 and 98 points, respectively. Their good results could be linked to the exclusion of patients with associated proximal humerus fractures and those surgically treated 2 weeks after the initial trauma. As seen in our study, a modified McLaughlin technique is widely used to fill RHS injuries of 20%–40% of the humeral head. We added headless compression screws to fix the disimpacted head bone fragments to ensure absolute stability of the articular fracture and favor the viability of cartilage and subchondral bone. Therefore, the functional results in our study are similar to those of other investigations in the literature.

Until the end of the follow-up period, no case of AVN or bone collapse had been reported. One reason could be that not all patients had enough follow-up, and we did not enroll any patients with 4-part fractures. However, due to AVN occurring mostly in acute cases [7], we cannot attribute our low rate of AVN to temporality because most of our patients were operated on in the acute stage.

The complication rate has varied considerably in previously published studies. AVN has been reported in 0%–50% of cases after surgical treatment at mid-term follow-up [1,3,18,19,21]. Basal et al. [7] published a systematic review on complication rates in 228 patients. An overall complication rate of 15.3% was found, similar to our results, with worse outcomes recorded in chronic cases (23% chronic vs. 8.8% acute). The most frequent complication was AVN (3.5%), and six out of eight cases occurred in patients treated with early surgery.

To date, there are no clear risk factors for AVN in surgically treated patients after PSFD. Further studies are needed to understand whether temporality, initial trauma energy, associated fractures, or type of ORIF are associated risk factors for AVN. As seen in most of the reported case series, no recurrent dislocations occurred during follow-up. This was probably because most of the reconstruction techniques used to treat RHS are sufficient to prevent recurrent glenohumeral instability [4,11,22].

Preoperative image analysis was essential for surgical planning. Understanding fracture patterns and humeral head anterior defects allows us to make a standardized recommendation for future cases. Thus, our main recommendations are as follows. First, use a posterior glenohumeral percutaneous portal to assist joint reduction with a spatula if reduction is difficult, regardless of the type of fracture; this can significantly reduce surgical time. Sec-

ond, identify the presence of an impacted head articular fragment or significant RHS (>25%); if present on preoperative CT images, it will be necessary to explore the joint. Third, joint exploration can be performed by SSC tenotomy or peeling, osteotomy of the LT, or through the LT fracture. Identify any LT fracture on preoperative CT images to avoid unnecessary SSC tenotomy or peeling. In cases where there is no LT fracture, an LT osteotomy could have advantages over peeling or tenotomy of the SSC tendon; this avoids iatrogenic disinsertion of the SSC tendon, allows filling of RHS when it is not possible to reconstruct the joint surface, or it can be used as subchondral support for the reconstructed head joint fragment by medializing the LT. Fourth, always attempt anatomical reconstruction of the articular surface. To do this, elevate fragments, seek anatomical reduction, and add headless cannulated compression screws in large unstable fragments to achieve absolute stability. Fifth, always reinsert the SSC tendon or fix the LT. Any residual anterior joint defect can be filled with the modified McLaughlin procedure or using the SSC tendon. Sixth, in the presence of a greater tuberosity or neck fracture, add a locked proximal humerus plate. These recommendations could aid in decision-making and decrease the surgical time (Fig. 5). Finally, the use of large auto/allografts, rotational osteotomies, or arthroplasties was not necessary. All our cases had <50% of the articular surface compromised, and most underwent early surgery. This allowed the joint surface to be reconstructed in all cases, reducing the final size of the head defect to <25% of the humeral head articular surface.

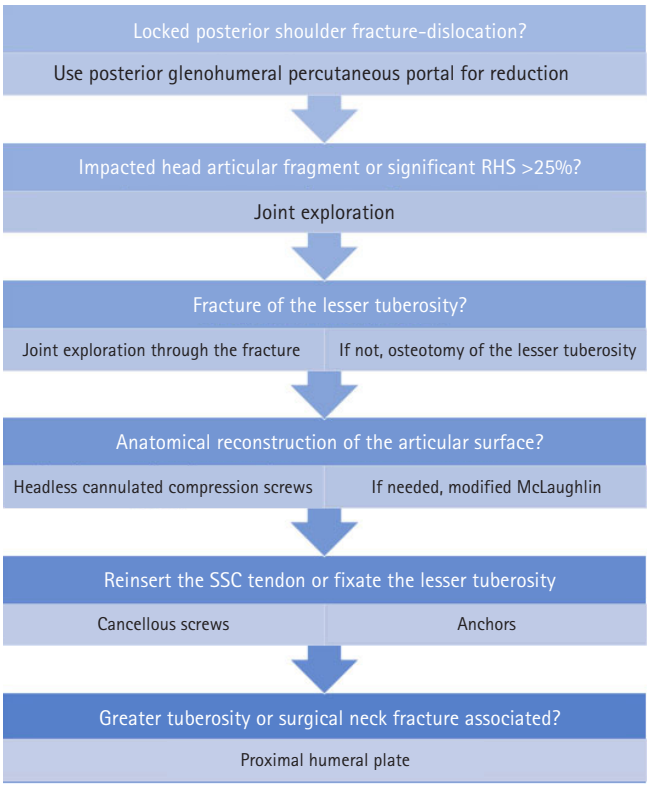

Fig. 5. Decision-making for the treatment of locked posterior shoulder fracture–dislocation. RHS: reverse Hill-Sachs, SSC: subscapularis.

This study has some limitations. The low frequency of a locked PSFD contributed to our small sample size and retrospective study design. Other limitations include a lack of a control group, a heterogeneous sample of patients, and multiple surgeons being involved in the treatment despite the standardized approach. Lastly, the clinical outcomes may differ from those of other studies because all our patients were under workers' compensation insurance, which has been described as a prognostic factor for poorer results in other shoulder injuries [23]. Larger comparative controlled studies should be conducted to evaluate functional and prognostic results in the treatment of patients with a locked PSFD.

Open surgical treatment of locked PSFD can achieve good functional results. Correct understanding of these injuries and preoperative planning helped us to achieve a low rate of complications like AVN and re-interventions. Further comparative controlled studies are needed to understand whether temporality, initial trauma energy, associated fractures, and type of ORIF are associated risk factors for complications and functional results.

ORCID

Nicolás Morán https://orcid.org/0000-0003-3705-8022
Michael Marsalli https://orcid.org/0000-0003-2518-0661

REFERENCES

1. Park HY, Kim SJ, Sur YJ, Jung JW, Kong CG. Treatment of unusual locked posterior fracture-dislocation of the shoulder: a case series. Clin Shoulder Elb 2020;23:190-6.
2. Robinson CM, Akhtar A, Mitchell M, Beavis C. Complex posterior fracture-dislocation of the shoulder: epidemiology, injury patterns, and results of operative treatment. J Bone Joint Surg Am 2007;89:1454-66.
3. Arafa MS, Abdelbadie A. The dual subscapularis procedure: a modified Hawkins' technique for neglected posterior fracture/dislocation of the shoulder. Eur J Orthop Surg Traumatol 2019;29:999-1007.
4. Kokkalis ZT, Iliopoulos ID, Antoniou G, Antoniadou T, Mavrogenis AF, Panagiotopoulos E. Posterior shoulder fracture-dislocation: an update with treatment algorithm. Eur J Orthop Surg Traumatol 2017;27:285-94.

https://doi.org/10.5397/cise.2022.00892

5. Demirel M, Erşen A, Karademir G, Atalar AC, Demirhan M. Transfer of the lesser tuberosity for reverse Hill-Sachs lesions after neglected posterior dislocations of the shoulder: a retrospective clinical study of 13 cases. Acta Orthop Traumatol Turc 2017;51:362-6.
6. Rouleau DM, Hebert-Davies J, Robinson CM. Acute traumatic posterior shoulder dislocation. J Am Acad Orthop Surg 2014;22:145-52.
7. Basal O, Dincer R, Turk B. Locked posterior dislocation of the shoulder: a systematic review. EFORT Open Rev 2018;3:15-23.
8. Moroder P, Scheibel M. ABC classification of posterior shoulder instability. Obere Extrem 2017;12:66-74.
9. Shams A, El-Sayed M, Gamal O, ElSawy M, Azzam W. Modified technique for reconstructing reverse Hill-Sachs lesion in locked chronic posterior shoulder dislocation. Eur J Orthop Surg Traumatol 2016;26:843-9.
10. Cicak N. Posterior dislocation of the shoulder. J Bone Joint Surg Br 2004;86:324-32.
11. Gerber C, Catanzaro S, Jundt-Ecker M, Farshad M. Long-term outcome of segmental reconstruction of the humeral head for the treatment of locked posterior dislocation of the shoulder. J Shoulder Elbow Surg 2014;23:1682-90.
12. Aydin N, Enes Kayaalp M, Asansu M, Karaismailoglu B. Treatment options for locked posterior shoulder dislocations and clinical outcomes. EFORT Open Rev 2019;4:194-200.
13. Aparicio G, Calvo E, Bonilla L, Espejo L, Box R. Neglected traumatic posterior dislocations of the shoulder: controversies on indications for treatment and new CT scan findings. J Orthop Sci 2000;5:37-42.
14. Schliemann B, Muder D, Gessmann J, Schildhauer TA, Seybold D. Locked posterior shoulder dislocation: treatment options and clinical outcomes. Arch Orthop Trauma Surg 2011;131:1127-34.
15. Ponce BA, Millett PJ, Warner JJ. Management of posterior glenohumeral instability with large humeral head defects. Tech Shoulder Elb Surg 2004;5:146-56.
16. McLaughlin HL. Posterior dislocation of the shoulder. J Bone Joint Surg Am 1952;34:584-90.
17. Hawkins RJ, Neer CS 2nd, Pianta RM, Mendoza FX. Locked posterior dislocation of the shoulder. J Bone Joint Surg Am 1987;69:9-18.
18. Cushner MA, Friedman RJ. Osteonecrosis of the humeral head. J Am Acad Orthop Surg 1997;5:339-46.
19. Liu X, Zhu Y, Lu Y, Li F, Wu G, Jiang C. Locked posterior shoulder dislocation associated with isolated fractures of the lesser tuberosity: a clinical study of 22 cases with a minimum of 2-year follow-up. J Orthop Trauma 2015;29:271-5.
20. Banerjee M, Balke M, Bouillon B, et al. Excellent results of lesser tuberosity transfer in acute locked posterior shoulder dislocation. Knee Surg Sports Traumatol Arthrosc 2013;21:2884-8.
21. Castagna A, Delle Rose G, Borroni M, et al. Modified MacLaughlin procedure in the treatment of neglected posterior dislocation of the shoulder. Chir Organi Mov 2009;93 Suppl 1:S1-5.
22. Moroder P, Plachel F, Tauber M, et al. Risk of engagement of bipolar bone defects in posterior shoulder instability. Am J Sports Med 2017;45:2835-9.
23. Kemp KA, Sheps DM, Luciak-Corea C, Styles-Tripp F, Buckingham J, Beaupre LA. Systematic review of rotator cuff tears in workers' compensation patients. Occup Med (Lond) 2011;61:556-62.

Original Article

Clin Shoulder Elbow 2022;25(4):296-303
https://doi.org/10.5397/cise.2022.00976

CiSE
Clinics in Shoulder and Elbow

eISSN 2288-8721

Increased interleukin-6 and TP53 levels in rotator cuff tendon repair patients with hypercholesterolemia

Jong Pil Yoon[1], Seung Gi Min[1], Jin-Hyun Choi[2], Hyun Joo Lee[1], Kyeong Hyeon Park[1], Sung Hyuk Yoon[1], Seong Soo Kim[1], Seok Won Chung[3], Hun-Min Kim[4], Dong Hyun Kim[1]

[1]*Department of Orthopaedic Surgery, School of Medicine, Kyungpook National University, Daegu, Korea*
[2]*Department of Bio-fibers and Materials Science, Kyungpook National University, Daegu, Korea*
[3]*Department of Orthopaedic Surgery, Konkuk University School of Medicine, Seoul, Korea*
[4]*Korea Dyeing and Finishing Technology Institute (DYETEC), Daegu, Korea*

Background: A previous study reported that hyperlipidemia increases the incidence of tears in the rotator cuff tendon and affects healing after repair. The aim of our study was to compare the gene and protein expression of torn rotator cuff tendons in patients both with and without hypercholesterolemia.
Methods: Thirty patients who provided rotator cuff tendon samples were classified into either a non-hypercholesterolemia group (n=19, serum total cholesterol [TC] <200 mg/dL) and hypercholesterolemia group (n=11, serum TC ≥240 mg/dL) based on their concentrations of serum TC. The expression of various genes of interest, including *COL1A1, IGF1, IL-6, MMP2, MMP3, MMP9, MMP13, TNMD*, and *TP53*, was analyzed by real-time quantitative reverse transcription polymerase chain reaction (qRT-PCR). In addition, Western blot analysis was performed on the proteins encoded by interleukin (IL)-6 and TP53 that showed significantly different expression levels in real-time qRT-PCR.
Results: Except for *IGF1*, the gene expression levels of *IL-6, MMP2, MMP9*, and *TP53* were significantly higher in the hypercholesterolemic group than in the non-hypercholesterolemia group. Western blot analysis confirmed significantly higher protein levels of IL-6 and TP53 in the hypercholesterolemic group ($p<0.05$).
Conclusions: We observed an increase in inflammatory cytokine and matrix metalloproteinase (MMP) levels in hypercholesterolemic patients with rotator cuff tears. Increased levels of IL-6 and TP53 were observed at both the mRNA and protein levels. We suggest that the overexpression of IL-6 and TP53 may be a specific feature in rotator cuff disease patients with hypercholesterolemia.

Keywords: Inflammation; Interleukin; Hypercholesterolemia; Rotator cuff

INTRODUCTION

Rotator cuff repair is widely practiced as a treatment method for rotator cuff tears. However, failure of the rotator cuff to heal after surgical treatment is a well-known complication that is reported in 20%-94% of cases [1]. Fatty degeneration is an important prognostic factor that determines the anatomical and functional outcome after rotator cuff repair [2]. However, it is difficult to re-

Received: April 22, 2022 Revised: July 6, 2022 Accepted: July 22, 2022
Correspondence to: Dong Hyun Kim
Department of Orthopaedic Surgery, School of Medicine, Kyungpook National University, 680 Gukchaebosang-ro, Jung-gu, Daegu 41944, Korea
Tel: +82-53-420-5628, Fax: +82-53-422-6605, Email: oskdh87090@gmail.com, ORCID: https://orcid.org/0000-0001-9078-5953

Financial support: This work was supported by Biomedical Research Institute grant, Kyungpook National University Hospital (2021).
Conflict of interest: Jong Pil Yoon is an editorial board member of the journal but was not involved in the peer reviewer selection, evaluation, or decision process of this article. No other potential conflicts of interest relevant to this article were reported.

verse the progress of fatty degeneration by rotator cuff repair alone [2].

Hypercholesterolemia is a crucial health problem that is associated not only with heart disease but also with tendon pathology [3]. Lipid-related changes in tendon pathology affect several mechanical properties of the tendon, including stiffness and modulus [4]. Multiple mechanisms have been proposed to clear these cholesterol-related changes, including alterations in tenocyte protein and gene expression, matrix turnover, cytokine production, and tissue vascularity [5]. A previous study reported that hyperlipidemia increases the incidence of tears in the rotator cuff tendon and affects healing after repair [6]. In animal models, hypercholesterolemia has been found to cause a decrease in the biomechanical properties of the tendon-to-bone healing of the rotator cuff [7]. However, few studies have reported differences in molecular level changes on the effects of hypercholesterolemia in rotator cuff tears.

The rotator cuff healing process is divided into three stages: inflammation, repair, and remodeling. This healing process is accomplished by various molecular mediators. The healing process of the tendon is initially composed of collagen type III, which is replaced by collagen type I, thus increasing the collagen type-I-to-III ratio [8]. Collagen type I is encoded by the COL1A1 and COL1A2 genes, respectively. In an *in vitro* study, tendon cells were shown to synthesize only collagen type I [9]. A different *in vitro* study found that insulin-like growth factor-1 (IGF-1) increased collagen synthesis in tendons and ligaments by stimulating fibroblast proliferation and synthesis of extracellular matrix (ECM) proteins [10]. In addition, it has been demonstrated that IGF-1 promotes the healing of tendons and ligaments in animals [11]. Interleukin (IL)-6 is one of the cytokines involved in triggering the inflammatory cascade in the early phase of the tendon healing process [12]. Moreover, it leads to collagen production in tendons and is significantly elevated after both exercise and trauma [13]. Matrix metalloproteinases (MMPs) are believed to play an important role in ECM remodeling during the remodeling phase of tendon healing [14]. MMP2, MMP9, and MMP13 are involved in cell transformation and morphogenesis as well as degradation in both pathological and non-pathological conditions [15]. Tenomodulin (TNMD) has been confirmed to be a relatively specific molecular marker of late tendon differentiation and plays a central role in the development and maturation of tendons [16,17]. p53 is a tumor suppressor protein known to inhibit fatty acid synthesis and lipid accumulation and to promote programmed cell death of tendon cells in rotator cuff tendinopathy [18-20].

In the present study, the gene expression levels of nine molecular mediators were analyzed in the rotator cuff tendon of patients both with and without hypercholesterolemia. The protein expression levels of the molecular mediators that showed significant differences in gene expression levels were analyzed. We hypothesized that hypercholesterolemia would affect the gene and protein expression of molecular mediators involved in tendon healing in torn rotator cuff tendons. Understanding the molecular basis of lipid-related changes in rotator cuff tendons may eventually prevent the progression of these changes and improve outcomes after rotator cuff repair.

METHODS

This study was approved by the Institutional Review Board of Kyungpook National University (No. KNUH 2016-11-020) including the procedure for informed consent from participants based on the Declaration of Helsinki in the study of human participants.

Participants

From October 2016 to November 2017, 240 patients who underwent arthroscopic rotator cuff repair for a full-thickness rotator cuff tear at our institution were enrolled in this study. Among them, 164 patients who could not contribute tissue from the rotator cuff tendon without prior informed consent were excluded. Among 76 patients, patients without preoperative serum lipid evaluation (n = 31) and with anteroposterior dimension of tear size < 1 cm or > 3 cm (n = 6) were excluded. Finally, patients with a borderline serum total cholesterol (TC) of ≥ 200 mg/dL and ≤ 240 mg/dL (n = 9) were excluded from the diagnostic criteria for hyperlipidemia [21]. Thirty patients were classified into either the non-hypercholesterolemia group (n = 19, TC < 200 mg/dL) or the hypercholesterolemia group (n = 11, TC ≥ 240 mg/dL) based on the concentrations of TC (Fig. 1). In the preoperative magnetic resonance imaging, any fatty infiltration of the supraspinatus, infraspinatus, and subscapularis muscles was graded according to the classification system of Goutallier et al. [22].

Tendon Tissue Collection from Patients

All patients included in the study provided informed consent for tissue collection of residual rotator cuff tendons that occurred during the debridement process during surgery. Specimens of about 5 mm × 5 mm were obtained from the tendons, placed in labeled plastic tubes with RNAlater (QIAGEN, Valencia, CA, USA) for nucleic acid extraction, and then transferred to a −80°C freezer until processing.

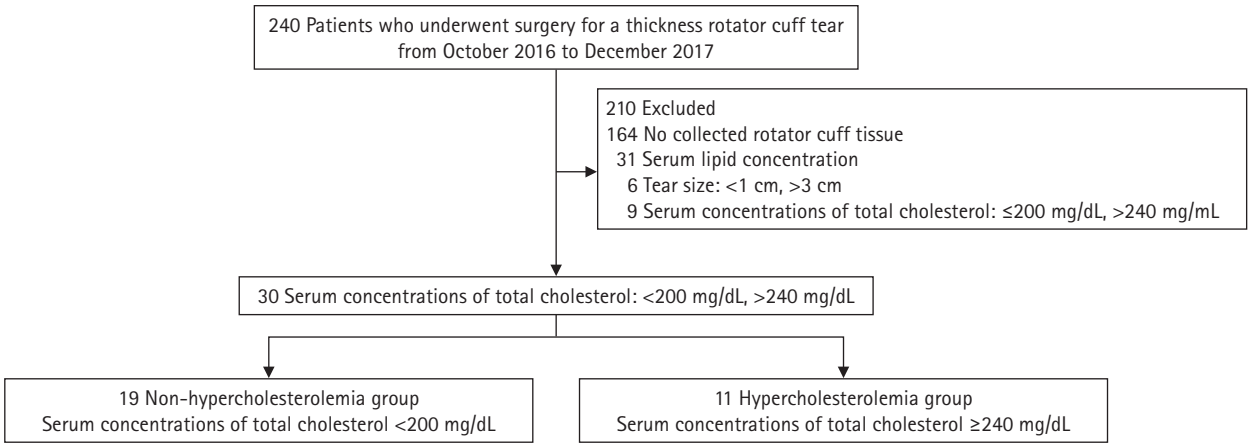

Fig. 1. Patient enrollment.

RNA Extraction and cDNA Synthesis

Frozen tissue samples stored at −80°C were homogenized in TRIzol reagent (Invitrogen, Carlsbad, CA, USA) using an OMNI TH Homogenizer (OMNI International, Kennesaw, GA, USA). RNA extraction was carried out as per the manufacturer's protocol using TRIzol reagent (Invitrogen). The RNA concentration and quality were determined by measuring the ratio of absorbance at 260 nm to that at 280 nm using a NanoDrop 2000 spectrophotometer (Thermo Fisher Scientific, Waltham, MA, USA), with all samples achieving a minimum ratio of 1.80. The RNA (250 ng) was reverse-transcribed using an iScript Reverse Transcription Supermix for quantitative reverse transcription polymerase chain reaction (qRT-PCR; Bio-Rad, Hercules, CA, USA).

Gene Expression by Quantitative Real-Time PCR

Complementary DNA was diluted to 2.5 ng/μL with Rnase-free water, and 5 μL of this solution was used to run a 20-μL quantitative polymerase chain reaction with iTaq Universal Probes Supermix (Bio-Rad). Validated human primers included *GAPDH* (ID: qHsaCEP0041396), *COL1A1* (ID: qHsaCEP0050510), *IGF1* (ID: qHsaCEP0041360), *IL-6* (ID: qHsaCEP0051939), *MMP2* (ID: qHsaCEP0049822), *MMP3* (ID: qHsaCIP0026053), *MMP9* (ID: qHsaCIP0028098), *MMP13* (ID: qHsaCIP0026824), *TNMD* (ID: qHsaCIP0029219), and *TP53* (ID: qHsaCEP0052284) (Bio-Rad). Duplicate reactions for each gene were run on a CFX96 touch real-time PCR machine (Bio-Rad), and the mean value for these duplicates was calculated and used for the analysis. Amplification reactions were performed with 40 cycles (95°C for 2 minutes, 95°C for 5 seconds, and 60°C for 30 seconds), and the results were normalized to *GAPDH* expression and calculated using CFX Manager 3.1 software (Bio-Rad).

Western Blot Analysis

Proteins were detected with the following antibodies and reagents. Total proteins were extracted using a radioimmunoprecipitation assay lysis buffer (Rockland Inc., Limerick, PA, USA) containing a protease inhibitor cocktail (Quartett, Berlin, Germany). The total proteins (20 μg/sample) were applied to sodium dodecyl sulfate-polyacrylamide gel electrophoresis, and the proteins were transferred to nitrocellulose membranes using the Trans-Blot Turbo Transfer System (Bio-Rad). The membranes were blocked with tris-buffered saline containing 5% skim milk and 0.2% Tween 20. Primary antibodies were used against the following proteins: IL-6 (Abcam, Cambridge, MA, USA), p53 (Cell Signaling Technology, Danver, MA, USA), and *GAPDH* (Cell Signaling). After reaction with horseradish peroxidase-conjugated secondary antibodies (Santa Cruz Biotechnology, Santa Cruz, CA, USA), the protein bands on the membranes were visualized using a Clarity Western ECL Substrate Chemiluminescence Assay Kit (Bio-Rad) following the manufacturer's suggested procedure. Densitometry of the bands was performed using a Chemi-Doc XRS+ Imaging System (Bio-Rad) and normalized to *GAPDH* band intensity.

Statistical Analyses

The mean values were compared using the Student t-test or Mann-Whitney U-test for continuous variables and the chi-square or Fisher's exact test for categorical variables to statistically evaluate the differences between groups. The statistical analysis was conducted using SPSS version 12.0 (SPSS Inc., Chicago, IL, USA) with the significance level set at $p < 0.05$. The data are presented as the mean ± standard deviation. A post hoc power analysis was performed on 30 patients, and the true effect size was evaluated using an α of 0.05 and an average effect of 0.8. In order

https://doi.org/10.5397/cise.2022.00976

to derive a significant result, the sample was analyzed as having 66% power.

RESULTS

Demographic Data

According to the demographic and clinical data, age, sex, prevalence of hypertension, diabetes and hyperthyroidism, rotator cuff tear size, fatty infiltration, duration of symptoms, and visual analog scale score were not significantly different between the two groups. The hypercholesterolemia group had higher serum TC and low-density lipoproteins concentrations (246.27 ± 7.79 mg/dL and 157.45 ± 21.93 mg/dL) as compared with the non-hypercholesterolemia group (192.87 ± 16.22 mg/dL and 116.72 ± 28.44 mg/dL) ($p = 0.009$ and $p = 0.009$, respectively). Serum high-density lipoprotein concentrations in the non-hypercholesterolemia group (66.20 ± 12.99 mg/dL) were significantly higher than in the hypercholesterolemia group (43.36 ± 9.08 mg/dL) ($p = 0.012$). Serum triglyceride concentrations were not significantly different between the two groups ($p = 0.108$) (Table 1).

Gene Expression by Quantitative Real-Time PCR

Among the cytokines, *IL-6* mRNA levels were the highest (mean, 10.90 ± 6.71), and the mRNA levels of *MMP2* (mean, 4.98 ± 3.33), *MMP9* (mean, 2.03 ± 1.56), and *TP53* (mean, 8.97 ± 5.79) were also significantly higher in the hypercholesterolemia group. In contrast, only *IGF1* mRNA levels (mean, 8.87 ± 5.87) were significantly higher in the non-hypercholesterolemia group (Table 2). These results indicated that hypercholesterolemia could influence the inflammatory response in rotator cuff tendon tissue ($p < 0.05$).

Western Blot

To investigate the effect of hypercholesterolemia on protein expression, an immunoblotting analysis was performed with antibodies against IL-6 and p53 based on the results of qRT-PCR; GAPDH was used as the loading control. A comparison of the Western blot band intensities (mean, 0.46 ± 0.24 and 0.23 ± 0.19, respectively) for IL-6 and TP53 revealed that their protein levels were significantly higher in patients with hypercholesterolemia (Table 3).

DISCUSSION

In this study, we found that in torn rotator cuff patients, the gene expression levels of IL-6, MMP2, MMP9, and TP53 were significantly higher in patients with hypercholesterolemia compared to those without hypercholesterolemia, and the gene expression of

Table 1. Comparison of demographic and clinical characteristics between patients with and without hypercholesterolemia

Variable	Non-hypercholesterolemia group (n = 19)	Hypercholesterolemia group (n = 11)	p-value
Age (yr)	67.37 ± 6.54 (56–75)	65.55 ± 10.20 (50–82)	0.602
Sex (male:female)	10:9	8:3	
Hypertension	11	4	0.093
Diabetes	1	0	0.176
Hyperthyroidism	1	3	0.087
Tear size, medial retraction (cm)	2.1 ± 1.14	2.05 ± 1.38	0.919
Tear size, anterior to posterior (cm)	1.67 ± 1.03	1.74 ± 0.84	0.838
Fatty infiltration			
Supraspinatus	2.00 ± 0.94	1.91 ± 0.70	0.766
Infraspinatus	0.95 ± 0.78	0.64 ± 0.50	0.196
Subscapularis	0.53 ± 0.84	0.18 ± 0.40	0.143
Duration of symptom (mo)	12.16 ± 11.95	11.18 ± 10.67	0.819
Initial pain, VAS	4.67 ± 1.87	6.27 ± 2.10	0.051
Resting pain, VAS	1.17 ± 1.29	2.09 ± 1.45	0.098
Night pain, VAS	3.72 ± 2.98	4.73 ± 2.83	0.373
TC (mg/dL)	192.87 ± 16.22	246.27 ± 7.79	0.009*
HDL (mg/dL)	66.20 ± 12.99	43.36 ± 9.08	0.012*
LDL (mg/dL)	116.72 ± 28.44	157.45 ± 21.93	0.009*
TG (mg/dL)	182.93 ± 27.78	200.82 ± 25.94	0.108

Values are presented as mean ± standard deviation (range) or mean ± standard deviation.
VAS: visual analog scale, TC: total cholesterol, HDL: high-density lipoprotein, LDL: low-density lipoprotein, TG: triglyceride.
*Statistically significant difference between groups ($p < 0.05$).

Table 2. Comparison of real-time PCR analysis data between two groups

Gene	Non-hypercholesterolemia group	Hypercholesterolemia group	p-value
COL1A1	1.69 ± 2.67	0.62 ± 0.52	0.138
IGF1	8.87 ± 5.87	2.63 ± 3.63	0.002*
IL6	3.01 ± 4.19	10.90 ± 6.71	0.001*
MMP13	0.13 ± 0.29	1.04 ± 1.31	0.013
MMP2	1.84 ± 1.35	4.98 ± 3.33	0.002*
MMP3	1.44 ± 2.70	5.73 ± 9.21	0.095
MMP9	0.96 ± 0.87	2.03 ± 1.56	0.028*
TNMD	1.23 ± 2.18	1.90 ± 3.69	0.545
TP53	3.19 ± 4.76	8.97 ± 5.79	0.006*

Values are presented as mean ± standard deviation.
PCR: polymerase chain reaction.
*Statistically significant difference between groups ($p < 0.05$).

Table 3. Comparison of Western blot analysis data between two groups

Protein	Control group	Hypercholesterolemia group	p-value
IL-6	0.24 ± 0.11	0.46 ± 0.24	0.003*
TP53	0.08 ± 0.08	0.23 ± 0.19	0.007*

Values are presented as mean ± standard deviation.
IL: interleukin.
*Statistically significant difference between groups ($p < 0.05$).

IGF1 was significantly higher in patients without hypercholesterolemia. Upon Western blot analysis, the expression of IL-6 and TP 53 proteins was significantly higher in patients with hypercholesterolemia than in those without.

The incidence of hypercholesterolemia is rapidly increasing in the elderly population and manifests as a debilitating medical condition accompanied by numerous systemic complications. In a high-cholesterol environment, lipids accumulate within the tendon ECM, forming a precipitate called a "yellow species." These lipid-related changes affect a variety of mechanical properties, including modulus and stiffness, in intact tendons [4]. There are several mechanisms that explicate these cholesterol-related changes, including changes in the tenocyte protein and gene expression, matrix turnover, cytokine production, and tissue vascularity. Hypercholesterolemia can alter the ECM of the tendons so that the damage is increased or becomes difficult to heal [5].

A previous study reported that hyperlipidemia increases the incidence of tears in the rotator cuff tendon and affects healing after repair [6]. However, the effects of hypercholesterolemia on the tendon at the molecular level are not yet known. In this study, we found significant overexpression of IL-6 and TP53 in the torn rotator cuff tendons of patients with hypercholesterolemia when compared with those of controls. IL-6 is a cytokine involved in the regulation of the immune response and inflammation or hematopoiesis, and it acts on various cells [12]. Cytokines can influence a wide array of ECM components [23]. In addition, IL-6 has been shown to be responsible for the inhibitory effects of wound fluid on fibroblast division [24]. Moreover, it leads to collagen production in tendons and is significantly elevated after both exercise and trauma [13]. TP53 dominates the cell cycle, induces cell death, and plays an important role in tumor suppression through its regulation of protein-related metabolism. In addition, previous studies have shown that TP53 regulates lipid metabolism by direct protein-protein interactions or transcriptional control of the proteins involved in fatty acid synthesis, fatty acid oxidation, the mevalonate pathway, lipid droplet formation, and cholesterol efflux [18]. Generally, TP-53 suppresses fatty acid synthesis and lipid accumulation.

No studies have been conducted on the changes in TP53 levels in hypercholesterolemia or its effect on the rotator cuff tendon healing process. In their study of different types of organs, Yao et al. [25] confirmed an increase in p53 levels in the kidneys of mice with hypercholesterolemia and reported that p53 induced apoptosis in the kidneys. A previous study reported a significant increase in p53 levels in supraspinatus tears and speculated that tenocyte apoptosis may be a relatively early feature in rotator cuff tendinopathy [20]. Kane and Greenhalgh [26] found that wounds in diabetic animals displayed a delayed onset of *p53* transcription but had persistently greater levels for longer periods of time. Diabetic animals appear to lose the indirect relationship between p53 and bcl-2. These findings suggest that p53 levels are increased in the early phase of healing, after which it becomes necessary to stop the inflammatory process and decrease p53 levels to allow cell proliferation to occur for tissue repair. In patients with hypercholesterolemia, fatty acid synthesis and lipid accumulation in the rotator cuff tendon are increased, which maintains the expression of TP53 in an elevated state for an extended time and may affect rotator cuff healing. Abboud and Kim [6] re-

https://doi.org/10.5397/cise.2022.00976

ported that patients with rotator cuff tears were more likely to have hypercholesterolemia than were those without tears. Chung et al. [3] observed that high cholesterol levels had a significant effect on rotator cuff healing in a rat model. To some extent, controlling hypercholesterolemia could stop or reverse the harmful effects of hypercholesterolemia even after rotator cuff canine repair surgery in a rat model. Despite these findings from these different studies, the pathophysiology of lipid-related tendon pathology remains incompletely understood [27].

In our study, IL-6 and TP53 levels were significantly higher in hypercholesterolemic patients who had undergone a rotator cuff repair. However, little is known about the effects of hyperlipidemia on the rotator cuff tendon at the molecular level. Several studies have reported the effects of lipid-lowering agents on cytokine levels in different tissues. Researchers who investigated the effects of cholesterol synthesis inhibitors on cytokine production capacity *in vitro* have explained the inhibitory effects on the production of several cytokines. Lovastatin inhibits lipopolysaccharide-induced synthesis of proinflammatory cytokines, such as tumor necrosis factor-α, IL-1βα, and IL-6, in rat primary astrocytes, microglia, and macrophages [28]. Sakoda et al. [29] reported that simvastatin reduces IL-1α-induced production of inflammatory cytokines, such as IL-6 and IL-8, in human oral epithelial cells. Thus, simvastatin has an anti-inflammatory effect on human oral epithelial cells via mechanisms that are independent of cholesterol lowering. The effects of statins on cytokine levels in other tissues in hypercholesterolemia remain unclear, which is also the case for the rotator cuff tendon.

This study had some limitations to consider for further study. First, although IL-6 and TP53 levels were significantly higher in patients with hypercholesterolemia, there was still insufficient evidence for the association of IL-6 and TP53 with hypercholesterolemia in this study. In addition, the protein expression of all molecular mediators that showed significant differences in gene expression have not yet been analyzed. Second, although it is known that hypercholesterolemia affects various mechanical properties of the tendon, it is still unclear whether elevations in IL-6 and TP53 expression have any significant effect on the healing of the rotator cuff in the presence of hypercholesterolemia. Third, the present study only analyzed the expression of genes and proteins in tissues either with or without hypercholesterolemia. Thus, we did not consider any other comorbidity that might affect the expression of these genes and proteins. Chung et al. [30] demonstrated that overexpression of MMP-9 and IL-6 may be one of the causes of high healing failure rates after rotator cuff repair in diabetic patients. Fourth, Tucker and Soslowsky [31] showed that treatment with simvastatin for 3 months alters some mechanical and histological properties of the tendon in a model of diet-induced hypercholesterolemia. Their simvastatin group had significantly more spindle-shaped cells in the midsubstance region of the supraspinatus muscle than their hypercholesterolemia group. Additionally, these data suggest that simvastatin use does not have any strong negative effect on the mechanical and histological properties of tendons, which implies that patients prescribed simvastatin may not experience any tendon damage. Among patients with hypercholesterolemia, those who were taking medication for treatment were not excluded from the study. Therefore, drug-induced changes in cytokine and growth factor production were not reflected in the results. Garcia et al. [32] reported that hypercholesterolemia was a significant risk factor for re-tears after arthroscopic rotator cuff repair. However, the type and dose of statin medication did not significantly affect the incidence of re-tears. Fifth, we could not include all the cytokines or growth factors relevant to tendon tears or hypercholesterolemia. Instead, we evaluated only selected cytokines or growth factors that were of our interest. Including more cytokines or growth factors in the analysis could detect other factors that may be related to rotator cuff tears in patients with hypercholesterolemia.

Our results showed an increase in inflammatory cytokine and MMP levels in tendon tissues obtained from patients with hypercholesterolemia who had undergone rotator cuff repair. Significantly higher IL-6 and TP53 levels were observed in the torn cuff tendon tissues not only at the mRNA level but also at the protein level. We suggest that the overexpression of IL-6 and TP53 may be an important feature in rotator cuff tears in patients with hypercholesterolemia.

ORCID

Jong Pil Yoon	https://orcid.org/0000-0001-6446-6254
Seung Gi Min	https://orcid.org/0000-0003-4343-1022
Jin Hyun Choi	https://orcid.org/0000-0002-5548-1230
Hyun Joo Lee	https://orcid.org/0000-0003-2837-3434
Kyeong Hyeon Park	https://orcid.org/0000-0001-7215-6176
Sung Hyuk Yoon	https://orcid.org/0000-0003-2797-4422
Seong Soo Kim	https://orcid.org/0000-0002-2809-1958
Seok Won Chung	https://orcid.org/0000-0002-8221-9289
Hun Min Kim	https://orcid.org/0000-0003-4447-6230
Dong Hyun Kim	https://orcid.org/0000-0001-9078-5953

REFERENCES

1. Gotoh M, Hamada K, Yamakawa H, et al. Interleukin-1-in-

duced glenohumeral synovitis and shoulder pain in rotator cuff diseases. J Orthop Res 2002;20:1365-71.
2. Gladstone JN, Bishop JY, Lo IK, Flatow EL. Fatty infiltration and atrophy of the rotator cuff do not improve after rotator cuff repair and correlate with poor functional outcome. Am J Sports Med 2007;35:719-28.
3. Chung SW, Park H, Kwon J, Choe GY, Kim SH, Oh JH. Effect of hypercholesterolemia on fatty infiltration and quality of tendon-to-bone healing in a rabbit model of a chronic rotator cuff tear: electrophysiological, biomechanical, and histological analyses. Am J Sports Med 2016;44:1153-64.
4. Tsouli SG, Kiortsis DN, Argyropoulou MI, Mikhailidis DP, Elisaf MS. Pathogenesis, detection and treatment of Achilles tendon xanthomas. Eur J Clin Invest 2005;35:236-44.
5. Soslowsky LJ, Fryhofer GW. Tendon homeostasis in hypercholesterolemia. Adv Exp Med Biol 2016;920:151-65.
6. Abboud JA, Kim JS. The effect of hypercholesterolemia on rotator cuff disease. Clin Orthop Relat Res 2010;468:1493-7.
7. Beason DP, Tucker JJ, Lee CS, Edelstein L, Abboud JA, Soslowsky LJ. Rat rotator cuff tendon-to-bone healing properties are adversely affected by hypercholesterolemia. J Shoulder Elbow Surg 2014;23:867-72.
8. Hays PL, Kawamura S, Deng XH, et al. The role of macrophages in early healing of a tendon graft in a bone tunnel. J Bone Joint Surg Am 2008;90:565-79.
9. Riederer-Henderson MA, Gauger A, Olson L, Robertson C, Greenlee TK Jr. Attachment and extracellular matrix differences between tendon and synovial fibroblastic cells. In Vitro 1983;19:127-33.
10. Herchenhan A, Bayer ML, Eliasson P, Magnusson SP, Kjaer M. Insulin-like growth factor I enhances collagen synthesis in engineered human tendon tissue. Growth Horm IGF Res 2015;25:13-9.
11. Dahlgren LA, van der Meulen MC, Bertram JE, Starrak GS, Nixon AJ. Insulin-like growth factor-I improves cellular and molecular aspects of healing in a collagenase-induced model of flexor tendinitis. J Orthop Res 2002;20:910-9.
12. Mitsuyama K, Sata M, Rose-John S. Interleukin-6 trans-signaling in inflammatory bowel disease. Cytokine Growth Factor Rev 2006;17:451-61.
13. Andersen MB, Pingel J, Kjær M, Langberg H. Interleukin-6: a growth factor stimulating collagen synthesis in human tendon. J Appl Physiol (1985) 2011;110:1549-54.
14. Aitken KJ, Block G, Lorenzo A, et al. Mechanotransduction of extracellular signal-regulated kinases 1 and 2 mitogen-activated protein kinase activity in smooth muscle is dependent on the extracellular matrix and regulated by matrix metalloproteinases. Am J Pathol 2006;169:459-70.
15. Choi HR, Kondo S, Hirose K, Ishiguro N, Hasegawa Y, Iwata H. Expression and enzymatic activity of MMP-2 during healing process of the acute supraspinatus tendon tear in rabbits. J Orthop Res 2002;20:927-33.
16. Takimoto A, Oro M, Hiraki Y, Shukunami C. Direct conversion of tenocytes into chondrocytes by Sox9. Exp Cell Res 2012;318:1492-507.
17. Aslan H, Kimelman-Bleich N, Pelled G, Gazit D. Molecular targets for tendon neoformation. J Clin Invest 2008;118:439-44.
18. Goldstein I, Ezra O, Rivlin N, et al. p53, a novel regulator of lipid metabolism pathways. J Hepatol 2012;56:656-62.
19. Yuan J, Murrell GA, Wei AQ, Wang MX. Apoptosis in rotator cuff tendonopathy. J Orthop Res 2002;20:1372-9.
20. Lundgreen K, Lian Ø, Scott A, Engebretsen L. Increased levels of apoptosis and p53 in partial-thickness supraspinatus tendon tears. Knee Surg Sports Traumatol Arthrosc 2013;21:1636-41.
21. Grundy SM, Cleeman JI, Merz CN, et al. Implications of recent clinical trials for the National Cholesterol Education Program Adult Treatment Panel III Guidelines. J Am Coll Cardiol 2004;44:720-32.
22. Goutallier D, Postel JM, Bernageau J, Lavau L, Voisin MC. Fatty muscle degeneration in cuff ruptures: pre- and postoperative evaluation by CT scan. Clin Orthop Relat Res 1994;304:78-83.
23. Sejersen MH, Frost P, Hansen TB, Deutch SR, Svendsen SW. Proteomics perspectives in rotator cuff research: a systematic review of gene expression and protein composition in human tendinopathy. PLoS One 2015;10:e0119974.
24. Lin TW, Cardenas L, Glaser DL, Soslowsky LJ. Tendon healing in interleukin-4 and interleukin-6 knockout mice. J Biomech 2006;39:61-9.
25. Yao Y, Tian X, Liu X, Shao J, Lv Y. The p53-mediated apoptosis in hypercholesterolemia-induced renal injury of rats. J Huazhong Univ Sci Technolog Med Sci 2005;25:408-11.
26. Kane CD, Greenhalgh DG. Expression and localization of p53 and bcl-2 in healing wounds in diabetic and nondiabetic mice. Wound Repair Regen 2000;8:45-58.
27. Ackermann PW, Hart DA. General overview and summary of concepts regarding tendon disease topics addressed related to metabolic disorders. Adv Exp Med Biol 2016;920:293-8.
28. Pahan K, Sheikh FG, Namboodiri AM, Singh I. Lovastatin and phenylacetate inhibit the induction of nitric oxide synthase and cytokines in rat primary astrocytes, microglia, and macrophages. J Clin Invest 1997;100:2671-9.
29. Sakoda K, Yamamoto M, Negishi Y, Liao JK, Node K, Izumi Y. Simvastatin decreases IL-6 and IL-8 production in epithelial cells. J Dent Res 2006;85:520-3.

https://doi.org/10.5397/cise.2022.00976

30. Chung SW, Choi BM, Kim JY, et al. Altered gene and protein expressions in torn rotator cuff tendon tissues in diabetic patients. Arthroscopy 2017;33:518-26.
31. Tucker JJ, Soslowsky LJ. Effect of simvastatin on rat supraspinatus tendon mechanical and histological properties in a diet-induced hypercholesterolemia model. J Orthop Res 2016;34:2009-15.
32. Garcia GH, Liu JN, Wong A, et al. Hyperlipidemia increases the risk of retear after arthroscopic rotator cuff repair. J Shoulder Elbow Surg 2017;26:2086-90.

Original Article

Clin Shoulder Elbow 2022;25(4):304-310
https://doi.org/10.5397/cise.2022.01025

CiSE
Clinics in Shoulder and Elbow

eISSN 2288-8721

What is the interobserver agreement of displaced humeral surgical neck fracture patterns?

Reinier W. A. Spek[1,2,3,*], Laura J. Kim[4,*], Traumaplatform 3D Consortium

[1]*Department of Orthopaedic Surgery, Flinders Medical Centre and Flinders University, Adelaide, Australia*
[2]*Department of Orthopaedic Surgery, OLVG, Amsterdam, The Netherlands*
[3]*Department of Orthopaedic Surgery, University Medical Centre Groningen and University of Groningen, Groningen, The Netherlands*
[4]*Department of Trauma Surgery, University Medical Centre Groningen and University of Groningen, Groningen, The Netherlands*

Background: The Boileau classification distinguishes three surgical neck fracture patterns: types A, B, and C. However, the reproducibility of this classification on plain radiographs is unclear. Therefore, we questioned what the interobserver agreement and accuracy of displaced surgical neck fracture patterns is categorized according to the modified Boileau classification. Does the reliability to recognize these fracture patterns differ between orthopedic residents and attending surgeons?
Methods: This interobserver study consisted of a randomly retrieved series of 30 plain radiographs representing clinical practice in a level 1 and a level 2 trauma center. Radiographs were included from patients (≥18 years) who sustained an isolated displaced surgical neck fracture if they were taken ≤1 week after initial injury. A ground truth was established by consensus among three senior orthopedic surgeons. All images were assessed by 17 orthopedic residents and 17 attending orthopedic trauma surgeons.
Results: Agreement for the modified Boileau classification was fair (κ=0.37; 95% confidence interval [CI], 0.36–0.38) with an accuracy of 62% (95% CI, 57%–66%). Comparison of interobserver variability between residents and attending surgeons revealed a significant but clinically irrelevant difference in favor of attending surgeons (0.34 vs. 0.39, respectively, Δ κ=0.05, 95% CI, 0.02–0.07).
Conclusions: The modified Boileau classification yields a low interobserver agreement with an unsatisfactory accuracy in a panel of orthopedic residents and attending surgeons. This supports the hypothesis that surgical neck fractures are challenging to categorize and that this classification should not be used to determine prognosis if only plain radiographs are available.

Keywords: Surgical neck fractures; Proximal humerus fracture; Shaft translation; Boileau classification; Interobserver variability

INTRODUCTION

Two-part surgical neck fractures of the humerus entail 28% of proximal humerus fractures and can be treated nonoperatively or by several surgical modalities (e.g., plate fixation and intramedullary nailing) [1-3]. However, substantial treatment variability is

Received: October 6, 2022 Revised: October 6, 2022 Accepted: October 6, 2022
Correspondence to: Reinier W. A. Spek
Department of Orthopaedic Surgery, Flinders Medical Centre and Flinders University, Dr. Bedford Park SA 5042, Adelaide, Australia
Tel: +61-08-8204 4289, Fax: +61-08-8374 0832, E-mail: reinierspek@gmail.com, ORCID: https://orcid.org/0000-0002-7509-6508
*These authors contributed equally to this work.

Financial support: The corresponding author (RWAS) has received payments during the study period, in amounts of less than USD 10,000 from Michael van Vloten Fonds (Rotterdam, The Netherlands), less than USD 10,000 from Anna Fonds NOREF (Mijdrecht, The Netherlands), less than USD 10,000 from Flinders Foundation (Adelaide, Australia), and between USD 10,000 and USD 100,000 from Prins Bernhard Cultuurfonds (Amsterdam, The Netherlands). No funding was received to carry out this specific study.
Conflict of interest: None.

observed between clinicians, hospitals, and even among countries [4]. Among other things, classification of the fracture is important for determining the optimal treatment [5]. Ideally, classification should guide the surgeons' decision-making and be taken into account to determine the optimal treatment for proximal humerus fractures.

Currently available classification systems for surgical neck fractures are the fracture patterns according to Neer [6] and Arbeitsgemeinschaft für Osteosynthesefragen (AO) [7]. Neer created three subgroups (impacted angulated, separated, and comminuted two-part surgical neck fractures), while the AO created two subgroups (impacted and non-impacted two-part surgical neck fractures). Nevertheless, clinical implications of these distinct fracture patterns are unclear.

To determine the optimal entry point for intramedullary nailing, Boileau et al. [8] developed a new classification system which categorized displaced surgical neck fractures into three types: type A, partial medial shaft translation with valgus humeral head angulation; type B, entire medial shaft translation without humeral head tilt or angulation; and type C, lateral shaft translation with varus humeral head angulation. Although numerous studies have investigated the agreement on the full array of two-, three-, and four-part proximal humerus fractures, no interobserver study has been carried out regarding surgical neck fracture patterns in particular [9,10]. A reproducible fracture classification is a prerequisite to comparing patient outcomes of different clinical trials [5]. Moreover, if a high level of agreement can be reached, fracture patterns could potentially influence surgical decision-making and might predict prognosis.

The Boileau classification was originally based on radiographs and computed tomography (CT) scans, but as CT scans are not routinely available for every patient, this study aimed to assess its reproducibility on plain radiographs. The following research questions were asked: what is the interobserver agreement and accuracy of displaced surgical neck fracture patterns categorized according to the modified Boileau criteria? And does the reliability to recognize these fracture patterns differ between orthopedic residents and attending surgeons?

METHODS

Ethical approval was received from OLVG (Amsterdam, The Netherlands, No. 19.135) and Flinders Medical Centre (Adelaide, Australia, No. 234.19). Informed consent from patients was waived.

Setting and Study Design

This is an interobserver study in which 30 radiographs were assessed and categorized according to the modified Boileau classification of displaced surgical neck fractures [8]. The study was carried out in March and April 2021, and an observer panel was created with participants from the orthopedic and trauma units of four different teaching hospitals. The panel consisted of 17 orthopedic residents and 17 attending orthopedic trauma surgeons with different levels of experience and subspecialties.

Images

Anteroposterior (true or standard) and lateral radiographic views were included from patients (≥18 years) who sustained an isolated displaced surgical neck fracture which could be classified according to the Boileau classification. Patients were deemed eligible irrespective of the treatment provided; thus, trauma radiographs of both non-operatively treated patients and surgically-treated patients were included. Patients were excluded if they presented to the emergency department more than 1 week after the initial injury or had a concomitant fracture (Hill-Sachs lesion, proximal humerus, humeral shaft, or pathologic fracture).

Classification

Boileau et al. [8] developed this classification system to categorize displaced surgical neck fractures into three types: type A, partial medial shaft displacement with valgus humeral head angulation; type B, entire medial shaft translation without humeral head tilt; and type C, lateral shaft displacement with varus humeral head angulation. A fracture was considered displaced if it was translated >25% of the humeral midshaft width. Displacement was measured from the outer cortex of the most proximal part of the humeral shaft fragment to the outer cortex of the most distal humeral head fragment. To cover all displaced surgical neck fractures, an additional category was incorporated in this study: "non-classifiable." This meant that the head angulation and humeral shaft translation did not match Boileau criteria (e.g., partial lateral humeral shaft translation without head angulation). Therefore, four categories could be chosen by the observers: type A, type B, type C, or non-classifiable (Fig. 1).

Selection of Radiographs

Radiographs of eligible patients were collected from a level 1 trauma center in Australia (March 1, 2016, to July 31, 2020) and a level 2 trauma center in the Netherlands (January 1, 2004, to June 30, 2018). A total of 614 surgical neck fractures were identified, of which 236 patients had a displaced fracture. Among these displaced fractures, 121 patients could be classified according to Boileau classification (type A, n=41; type B, n=20; type C, n=60). While maintaining this mutual distribution between the

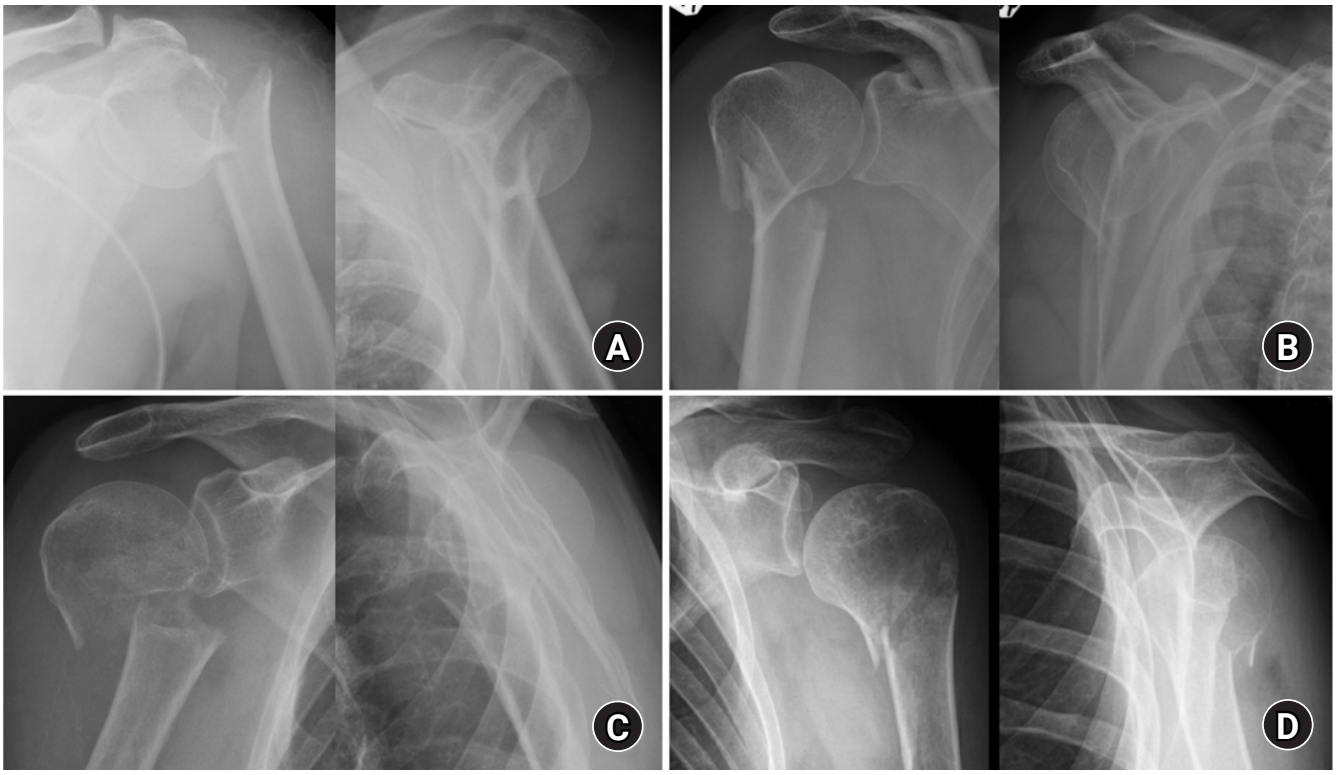

Fig. 1. The modified Boileau classification covers four options: type A, type B, type C, and non-classifiable displaced surgical neck fractures. (A) Type A: medial shaft translation with valgus humeral head tilt. (B) Type B: entire medial (or ventral) shaft translation without humeral head tilt. (C) Type C: lateral shaft displacement with varus angulation of the head. (D) Non-classifiable: shaft translation and/or head angulation do not match with Boileau classification. In this example, there is no varus angulation of the head, meaning it could not be classified according to Boileau. Type A and C were used for training; type B and the non-classifiable radiograph were used for the actual assessments.

three Boileau types, we randomly selected 9 type A fractures, 5 type B, 11 type C, and 5 non-classifiable fractures. The number selected for the non-classifiable category was equal to that of the group with the lowest number (i.e., type B fractures). Randomization was carried out in Microsoft Excel version 2102 (Microsoft Corp., Redmond, WA, USA) by assigning a randomization number which was sorted from low to high. Cases with the lowest randomization number were selected until the predefined sample size (n = 30) was reached. The mean age (range) of included patients was 72.4 years (29–96 years), and the majority were females (80%).

Ground Truth

A ground truth was generated by consensus among three senior orthopedic attending surgeons (two with > 20 years of experience and one with > 15 years of experience after finishing their training). Each of these orthopedic surgeons completed the study prior to the consensus meeting, so they classified all fractures independently before answers were compared. The meeting was led by the first author (RWAS), and discrepancies were resolved by discussion.

Observer Panel

The observer panel consisted of 34 participants: 17 orthopedic residents and 17 attending orthopedic surgeons. Six attending orthopedic surgeons had < 5 years of experience. All other attending surgeons had > 5 years of experience: five were seniors (> 20 years of experience), three were shoulder specialists (they completed fellowship training on the upper extremity), two were dedicated attending trauma surgeons, and one was an orthopedic oncologist. All attending surgeons had substantial experience in treating trauma, and years of experience was defined as years in clinical practice after finishing the training program.

Training and Assessment

Prior to assessment, each observer received training in recognizing the fracture patterns according to Boileau classification. The first part of the training consisted of an explanation of the fracture patterns and the following rules: (1) dorsal head angulation is not considered (e.g., medial translation with valgus head angulation and dorsal head angulation should be classified as a type A fracture) and (2) type B fractures require entire medial or entire ventral humeral shaft translation. It was also emphasized that

https://doi.org/10.5397/cise.2022.01025

both head angulation and shaft displacement had to match Boileau criteria (e.g., medial humeral shaft translation with varus angulation should be categorized as non-classifiable). Following this, four training cases were provided (one case covering each category) (Fig. 2). At the discretion of observers, training was provided either face-to-face (by RWAS or LK) or as self-study via REDCap [11,12]. Face-to-face training was provided to 73.5% of observers, and 26.5% followed the self-study on REDCap.

Each observer classified 30 displaced surgical neck fractures with both anteroposterior and lateral views. Questions and radiographs were both presented on-screen. Illustration sheets depicting the classification system were displayed during the observation. There was no time limit on assessment, and radiographs were presented in the identical order for each observer. Observers could not use radiographic measurement tools. However, they could go back if needed and adjust their answer for each radiograph.

Statistical Analysis

IBM SPSS software ver. 27 (IBM Corp., Armonk, NY, USA) was used for statistical analysis. To determine interobserver variability, the multi-rater Fleiss' kappa (κ) was calculated. Values were interpreted according to Landis and Koch: κ <0.00 (poor), κ=0.00–0.20 (slight), κ=0.21–0.40 (fair), κ=0.41–0.60 (moderate), κ=0.61–0.80 (substantial), and κ=0.81–1.00 (almost perfect) [13]. Accuracy was defined as the degree to which each given answer corresponded with the ground truth and expressed as a percentage from 0 to 100. If the accuracy was 0%, no cases were classified the same as the ground truth. If the accuracy was 100%, all cases were classified the same as the ground truth. To calculate accuracy, the accuracy per observer was determined and subsequently averaged across all participants. To compare residents versus attending surgeons, delta (Δ) κ was computed and depicted with a two-tailed p-value. Accuracy among residents and attending surgeons was compared with an independent samples t-test. Multi-rater Fleiss' κ as well as accuracy was displayed with a 95% confidence interval (CI).

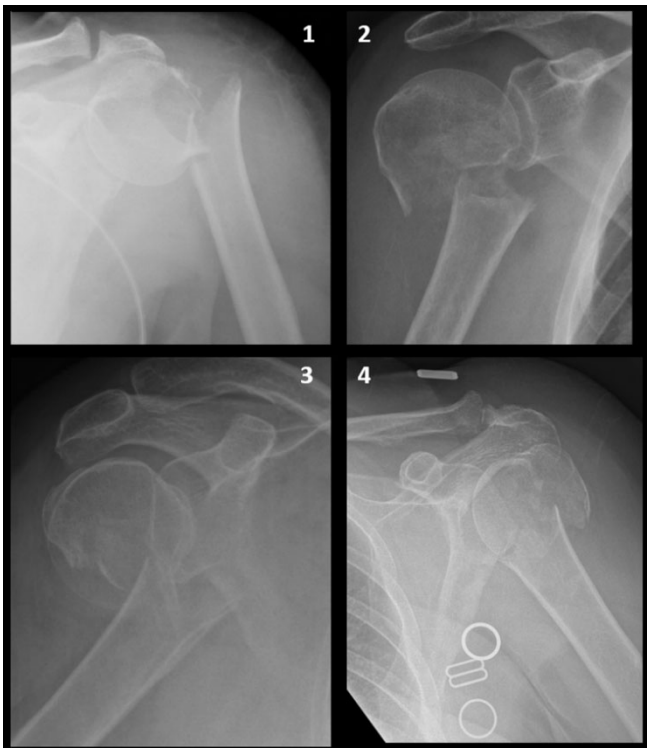

Fig. 2. Radiographs used for training, shown in order from 1 to 4, with 1=type C, 2=type A, 3=type B, and 4=non-classifiable. Although present on image 3 and 4, fracture dislocations and concomitant greater tuberosity fractures were not included in the actual assessment. This was explained to the observers accordingly.

RESULTS

Interobserver Variability and Accuracy

Interobserver agreement to classify fractures according to the modified Boileau criteria among all observers was fair (κ=0.37; 95% CI, 0.36–0.38) (Fig. 3). In type A and C fractures, concordance was moderate (κ=0.42; 95% CI, 0.40–0.44 and κ=0.58; 95% CI, 0.57–0.59, respectively). Observers disagreed the most on type B (κ=0.23; 95% CI, 0.21–0.25) and non-classifiable fractures (κ=0.18; 95% CI, 0.16–0.20). Accuracy amongst all participants was 62% (95% CI, 57%–66%) and the highest for type C fractures, 79% (95% CI, 74%–85%) (Table 1).

Residents vs. Attending Surgeons

Comparison of interobserver variability between residents and

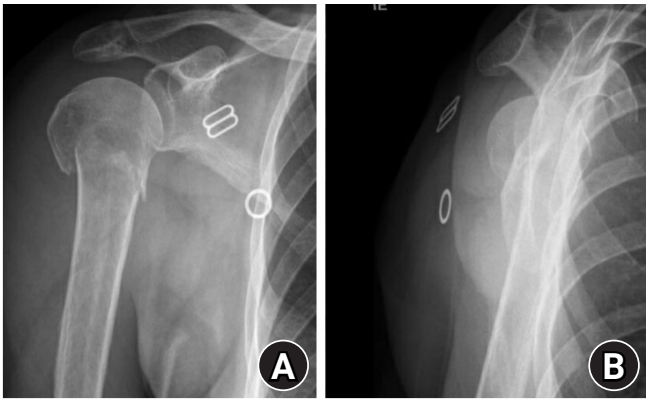

Fig. 3. Assessment of a radiograph with substantial variability amongst the observers: 53% classified this as type A (18 observers), 3% as type B (1 observer), 3% as type C (1 observer), and 41% as "non-classifiable" (14 observers). (A) Standard anterior-posterior view. (B) Lateral view.

Table 1. Agreement and accuracy among all observers

Category	Kappa (95% CI)	Agreement	Accuracy (95% CI), %
Overall	0.37 (0.36–0.38)	Fair	62 (57–66)
Type A	0.42 (0.40–0.44)	Moderate	64 (57–71)
Type B	0.23 (0.21–0.25)	Fair	69 (59–79)
Type C	0.58 (0.57–0.59)	Moderate	79 (74–85)
Non-classifiable	0.18 (0.16–0.20)	Slight	57 (49–65)

Type A: medial shaft translation with valgus humeral head tilt, Type B: entire medial (or ventral) shaft translation without humeral head tilt, Type C: lateral shaft displacement with varus angulation of the head, Non-classifiable: shaft translation and/or head angulation do not match with Boileau classification.
CI: confidence interval.

Table 2. Agreement and accuracy compared between 17 residents and 17 attending surgeons

Parameter	Kappa (95% CI)	Agreement	Accuracy (95% CI), %
Resident	0.34	Fair	60%
Surgeon	0.39	Fair	63%
Delta	0.05		3%
p-value	< 0.001		0.47

CI: confidence interval.

attending surgeons revealed a significant but intuitively clinically irrelevant difference in favor of attending surgeons (fair vs. fair, $\Delta\kappa = 0.05$; 95% CI, 0.02–0.07). Residents showed an accuracy of 60% (95% CI, 55–65) in correctly classifying the fractures, whereas attending surgeons revealed an accuracy of 63% (95% CI, 55%–72%). No statistically significant difference was found between both groups ($\Delta\kappa = 0.03$; 95% CI, –0.06 to 0.12) (Table 2).

DISCUSSION

Boileau classification is a recently introduced classification to enhance the humeral nail entry point in treatment for displaced surgical neck fractures. Its inter-surgeon reliability on plain radiographs is unclear, hence our aim was to assess the interobserver variability and accuracy. This study revealed an overall kappa of 0.37 with 62% accuracy for the modified Boileau classification on radiographs. The interobserver variability is a measure that represents the extent of variation between observers for the same radiographs expressed as the kappa coefficient and should be considered together with accuracy. A kappa value of 0.38 is relatively low and implies strong variability in classification, which can lead to misdiagnosis and a potential delay in best treatment. In other words, our study demonstrated that 62% of radiographs were classified correctly, but there was substantial disagreement in the misclassified radiographs.

The interobserver reliability of the general AO and full Neer classification systems has been studied intensively. However, many of these studies had a limited number of observers, which could result in overestimation of agreement, and the question remained unanswered as to the interobserver agreement for the subgroups of surgical neck fractures (Neer included three subgroups, and AO included two subgroups) [14,15]. Regarding the AO classification, the largest study included 46 observers and found a kappa of 0.18 [10]. Another study included 18 observers and investigated the agreement on two-, three-, and four-part fractures according to Neer. They revealed a kappa ranging from 0.03 to 0.07 for classifying two-part fractures [9]. Additionally, kappa values do not improve when fractures are assessed with CT scans [8,9,14,16]. Our study therefore demonstrated a better kappa (0.38); however, this is still inadequate for clinical use. Furthermore, the low interobserver agreement of Boileau classification has implications for surgical decision-making in clinical practice: it is unlikely that surgeons can solely rely on radiographs for surgical planning of humeral nailing.

Assessment of three- and four-part proximal humerus fractures is thought to be better among shoulder specialists compared to general orthopedic surgeons [9]. Additionally, some studies advocate that attending surgeons outperform residents [16]. In this study, we did not find a clinically relevant difference between assessments by residents compared to attending surgeons. As opposed to three- and four-part fractures, this study therefore suggests that two-part displaced surgical neck fractures do not require a certain level of expertise, potentially due to their less complex nature or due to the matter that nobody had any experience with this classification.

It has yet to be established whether or not Boileau classification has clinical implications aside from humeral nailing, and if it can determine prognosis. Nevertheless, one could argue that this classification may be useful for decision-making. For instance, in type B fractures, the entire shaft is translated, which, in our experience, may require surgical intervention. Moreover, type C fractures are likely to respond well to non-operative treatment due to traction of the pectoralis major muscle while wearing a collar and cuff. Decision-making in type A fractures could depend on the degree of valgus angulation, as patients with ≥160° may be better off with surgical fixation [17].

This work reconfirms the challenges clinicians are facing to improve interobserver agreement for proximal humerus fracture patterns. As the era of artificial intelligence is approaching, it is speculated that we should make a transition to data-driven care: potentially, an algorithm trained on fracture classification by the input of senior surgeons could neutralize current misconceptions

https://doi.org/10.5397/cise.2022.01025

and observation bias [17].

Several shortcomings should be considered: firstly, the quality of radiographs varied as not all radiographs were taken with similar radiographic imaging settings. In some, the patients' true anteroposterior radiographic views were not obtained, which may have changed the perception of humeral shaft translation as well as head angulation. Additionally, internal humeral head rotation makes it difficult to assess head deformity as the greater tuberosity is not well profiled. However, our aim was to evaluate the classification on radiographs, which would reflect the hospital setting well: in clinical practice, it is well known that radiographic quality can be low, and that patients retain their shoulders in internal rotation due to pain. As opposed to the original classification, CT scans were not used for this study. The rationale for assessing this classification was to assess whether it could be applied to all patients presenting at the emergency department, and as CTs are not routinely performed for these patients, this was not feasible. Hence, we coined it the modified Boileau classification: a fourth category (non-classifiable) was added to cover all displaced surgical neck fractures. One could argue that by mitigating these factors, interobserver variability could improve. Secondly, in clinical practice, radiographs are usually discussed between colleagues (e.g., between orthopedic residents and attending surgeons). This is a limitation for interobserver studies in general so it would be interesting to assess its impact on agreement. For instance, during the consensus meeting there was hardly any significant dispute on radiographs even though the attending surgeons classified 12 radiographs differently during initial assessment. This underscores the suggestion that group discussion might improve agreement. Thirdly, the intra-observer agreement was not evaluated.

One of the study strengths was the representativeness of the observer panel, which was a good reflection of potential users of this classification. Displaced surgical neck fractures are hard to classify on plain radiographs: the modified Boileau classification yields a poor interobserver agreement with an accuracy of 62% in a panel of orthopedic residents and attending surgeons with different levels of experience. This suggests that two-part displaced surgical neck fractures do not require a certain level of expertise, and that surgeons cannot rely solely on radiographs for surgical planning of humeral nailing.

ACKNOWLEDGMENTS

The traumaplatform 3D study collaborative:
Henrik Åberg, Anushka Abeywickrama, Michel P. J. van den Bekerom, Wael Chiri, Samantha Damude, Marion M. Deken, Ron L. Diercks, Derek F. P. van Deurzen, Job N. Doornberg, Nathan Eardley-Harris, Anne T. Fokkema, Tom J. Gieroba, H. S. Femke Hagenmaier, Sharon Hendriks, Tanneke I. Herklots, Genevieve S. Hernández, Lotje A. Hoogervorst, Frank F. A. IJpma, Ruurd L. Jaarsma, Bhavin Jadav, Paul C. Jutte, Bas Keizers, Simone F. Kleiss, Maarten C. Koper, Borg Leijtens, Hamid Lutfi, Shoumit Mukhopadhaya, Arthur van Noort, Pradeep M. Poonnoose, Tim Ramsey, Jai Rawat, Jack Richards, Mieke van Suijlichem, Hugo C. van der Veen, Klaus W. Wendt, Roy Zuidema.
Representative trauma platform study Collaborative: Job N. Doornberg.

ORCID

Reinier W. A. Spek https://orcid.org/0000-0002-7509-6508
Laura J. Kim https://orcid.org/0000-0003-1783-0679

REFERENCES

1. Yoon RS, Dziadosz D, Porter DA, Frank MA, Smith WR, Liporace FA. A comprehensive update on current fixation options for two-part proximal humerus fractures: a biomechanical investigation. Injury 2014;45:510-4.
2. Setaro N, Rotini M, Luciani P, Facco G, Gigante A. Surgical management of 2- or 3-part proximal humeral fractures: comparison of plate, nail and K-wires. Musculoskelet Surg 2022;106:163-7.
3. Court-Brown CM, Garg A, McQueen MM. The epidemiology of proximal humeral fractures. Acta Orthop Scand 2001;72:365-71.
4. Launonen AP, Sumrein BO, Reito A, et al. Operative versus non-operative treatment for 2-part proximal humerus fracture: a multicenter randomized controlled trial. PLoS Med 2019;16:e1002855.
5. Handoll HH, Brorson S. Interventions for treating proximal humeral fractures in adults. Cochrane Database Syst Rev 2015;(11):CD000434.
6. Neer CS 2nd. Displaced proximal humeral fractures. I. Classification and evaluation. J Bone Joint Surg Am 1970;52:1077-89.
7. Meinberg EG, Agel J, Roberts CS, Karam MD, Kellam JF. Fracture and Dislocation Classification Compendium-2018. J Orthop Trauma 2018;32 Suppl 1:S1-170.
8. Boileau P, d'Ollonne T, Bessière C, et al. Displaced humeral surgical neck fractures: classification and results of third-generation percutaneous intramedullary nailing. J Shoulder Elbow Surg 2019;28:276-87.
9. Foroohar A, Tosti R, Richmond JM, Gaughan JP, Ilyas AM.

Classification and treatment of proximal humerus fractures: inter-observer reliability and agreement across imaging modalities and experience. J Orthop Surg Res 2011;6:38.
10. Bruinsma WE, Guitton TG, Warner JJ, Ring D; Science of Variation Group. Interobserver reliability of classification and characterization of proximal humeral fractures: a comparison of two and three-dimensional CT. J Bone Joint Surg Am 2013;95:1600-4.
11. Harris PA, Taylor R, Minor BL, et al. The REDCap consortium: building an international community of software platform partners. J Biomed Inform 2019;95:103208.
12. Harris PA, Taylor R, Thielke R, Payne J, Gonzalez N, Conde JG. Research electronic data capture (REDCap): a metadata-driven methodology and workflow process for providing translational research informatics support. J Biomed Inform 2009;42:377-81.
13. Landis JR, Koch GG. The measurement of observer agreement for categorical data. Biometrics 1977;33:159-74.
14. Iordens GI, Mahabier KC, Buisman FE, Schep NW, Muradin GS, Beenen LF, et al. The reliability and reproducibility of the Hertel classification for comminuted proximal humeral fractures compared with the Neer classification. J Orthop Sci 2016;21:596-602.
15. Marongiu G, Leinardi L, Congia S, Frigau L, Mola F, Capone A. Reliability and reproducibility of the new AO/OTA 2018 classification system for proximal humeral fractures: a comparison of three different classification systems. J Orthop Traumatol 2020;21:4.
16. Bernstein J, Adler LM, Blank JE, Dalsey RM, Williams GR, Iannotti JP. Evaluation of the Neer system of classification of proximal humeral fractures with computerized tomographic scans and plain radiographs. J Bone Joint Surg Am 1996;78:1371-5.
17. Chung SW, Han SS, Lee JW, et al. Automated detection and classification of the proximal humerus fracture by using deep learning algorithm. Acta Orthop 2018;89:468-73.

https://doi.org/10.5397/cise.2022.01025

Original Article

Clin Shoulder Elbow 2022;25(4):311-320
https://doi.org/10.5397/cise.2022.01088

CiSE
Clinics in Shoulder and Elbow

eISSN 2288-8721

Prosthetic shoulder arthroplasty in patients 40 years or younger: outcomes stratified by diagnosis and surgery

Samer S. Hasan[1,2], Leslie E. Schwindel[3], Cassie M. Fleckenstein[1,2]

[1]*Mercy Health/Cincinnati SportsMedicine and Orthopaedic Center, Cincinnati, OH, USA*
[2]*Cincinnati Sports Medicine Research and Education Foundation, Cincinnati, OH, USA*
[3]*Lake Cumberland Regional Hospital, Somerset, KY, USA*

Background: The outcomes of patients 50–55 years old or younger undergoing prosthetic shoulder arthroplasty (PSA) may not generalize to younger patients. We report outcomes following PSA in a consecutive series of patients 40 years or younger. We hypothesize that total shoulder arthroplasty (TSA) provides better outcome and durability than resurfacing hemiarthroplasty (RHA).
Methods: Patients were stratified by diagnosis and surgical procedure performed, RHA or TSA. Active range of motion and self-assessed outcome were evaluated preoperatively and at final follow-up.
Results: Twenty-nine consecutive PSAs were identified in 26 patients, comprising 9 TSAs and 20 RHAs, with a minimum of 2-year follow-up. Twelve PSAs were performed for chondrolysis. Mean active forward elevation, abduction, external rotation, and internal rotation improved significantly ($p<0.001$ for all). Mean pain score improved from 6.3 to 2.1, Simple Shoulder Test from 4.0 to 9.0, and American Shoulder and Elbow Surgeons score from 38 to 75 ($p<0.001$ for all). Patients undergoing RHA and TSA had similar outcomes; but three RHAs required revision, two of these within 4 years of implantation. Four of five patients undergoing revision during the study period had an original diagnosis of chondrolysis.
Conclusions: PSA in young patients provides substantial improvement in active range of motion and patient reported outcomes irrespective of diagnosis and glenoid management. However, patients undergoing RHA, especially for chondrolysis, frequently require subsequent revision surgery, so that RHA should be considered with caution in young patients and only after shared decision-making and counsel on the risk of early revision to TSA.

Keywords: Arthroplasty, shoulder, replacement; Young; 40 Years; Resurfacing; Chondrolysis

INTRODUCTION

Prosthetic shoulder arthroplasty (PSA) provides excellent pain relief and restores function in patients with glenohumeral arthritis. PSA performance has increased significantly [1-4] because of greater patient expectations, proven clinical outcomes, and implant durability. Specifically, anatomic total shoulder arthroplasty (TSA) is preferred over hemiarthroplasty (HA), at least for patients with primary glenohumeral osteoarthritis, because of documented superior outcomes and durability [5,6].

In addition, the indications for PSA have expanded to new patient populations, including increasingly younger patients with

Received: July 2, 2022 Revised: November 1, 2022 Accepted: November 3, 2022
Correspondence to: Samer S. Hasan
Mercy Health/Cincinnati SportsMedicine and Orthopaedic Center, 4700 E. Galbraith Rd, 3rd Floor, Cincinnati, OH 45236, USA
Tel: +1-513-853-8886, E-mail: sshasan@zoomtown.com, ORCID: https://orcid.org/0000-0002-5344-9245

Financial support: None.
Conflict of interest: None.

specific types of glenohumeral arthritis, such as post-traumatic arthritis, chondrolysis, and capsulorrhaphy arthropathy. Particularly, post-arthroscopic chondrolysis is a rare but devastating condition characterized by rapid cartilage destruction with associated high pain level and stiffness. Chondrolysis has affected patients as young as 15 years [7] and has been associated with prominent suture anchors, excessive use of heat, and intra-articular infusion of local anesthetics [8].

Despite the benefits of PSA, concerns over long-term durability have limited its use in young patients [9]. These concerns have motivated the development of non-prosthetic alternatives, including arthroscopic and open reparative and biologic interventions. Specifically, osteoarticular autograft transfer or allograft surgery [10-12], as well as arthroscopic procedures including debridement, resection of osteophytes, microfracture, and capsular release, coupled with adjunctive procedures such as biceps tenodesis and subacromial decompression are being performed in young patients with glenohumeral arthritis [10,12-17]. Some have advocated arthroscopic intervention even for advanced disease [14,15], but long-term effectiveness remains unknown, and both short-term effectiveness and reproducibility have been questioned, especially in patients with bipolar joint disease [10,13,17,18]. Furthermore, some types of glenohumeral arthritis, such as chondrolysis, are refractory to nonoperative and arthroscopic interventions and frequently require PSA [19,20].

The precise definition of "young" patient, as pertaining to PSA, is also evolving. Most previous reports adopted thresholds of 50 or 55 years of age to characterize patients as young [9,21-26]. However, much younger patients also undergo PSA [19,20,27]. The generalizability of published results of PSA in patients approaching 50 years of age is unproven. Understanding the outcomes of PSA in young patients is important for several reasons. Young patients often have the highest expectations and greatest demands for both work and sport. Second, their life expectancy is longer, increasing the importance of identification of risk factors for early failure or revision. Third, the number of patients undergoing PSA, including young patients, is projected to continue to increase [3].

To our knowledge, there are no published data on the outcome of PSA in a cohort composed entirely of patients who are much younger than 50 years. The purpose of this study is to report on outcomes following PSA, stratified by surgery and by diagnosis, in patients who are 40 years or younger. There are several studies looking at patients younger than 50 including articles by Sperling et al. [24-26]. Our hypothesis is that TSA provides better clinical outcomes and implant durability compared with HA, including resurfacing hemiarthroplasty (RHA). Our secondary hypothesis is that patients with chondrolysis have inferior outcomes following PSA than do those with other diagnoses.

METHODS

This study was conducted in compliance with Good Clinical Practices. Data included in this study were prospectively collected as part of the senior author's standard of care. Internal review by our ethics committee was completed, but formal Institutional Review Board approval was not required. Informed consent was not required for this retrospective study because all data recorded, analyzed, and reported were obtained routinely as part of the senior author's clinical practice.

All primary PSAs performed by the senior author between January 2008 and December 2017 in patients 40 years and younger were identified. As stated, younger than 40 years excludes patients who are 40 years old, but we included these patients. The type and number of previous surgeries and underlying diagnoses were recorded for each patient. Surgeries were stratified as either RHA or TSA. The results from two patients undergoing stemmed HA with concentric glenoid reaming, often referred to as the ream-and-run procedure, were included in the TSA group. This classification was used because of the similar peri-glenoid soft tissue releases and glenoid surface preparation (other than glenoid component insertion) as well as indication of glenohumeral arthrosis with more severe glenoid wear. This differentiated these cases from RHAs, which were performed in patients with concentric and generally milder glenoid wear. All patients underwent preoperative standardized bi-planar radiographs and either magnetic resonance imaging or computed tomography scan.

All PSAs were performed through a deltopectoral interval with subscapularis peel. Anterior and inferior capsular release was carried out in all patients, but the labrum was preserved unless a glenoid implant was being inserted. Except in a few of the youngest patients treated early in the study period, the biceps tendon was tenodesed routinely. All humeral implants were inserted without cement, and all glenoid implants were composed of all-polyethylene cemented components. Subscapularis repair was performed using transosseous sutures for TSA and three to four double- or triple-loaded suture anchors for RHA. No patient 40 years or younger underwent reverse shoulder arthroplasty, stemless TSA, or glenoid resurfacing using a tissue patch during the study period.

Patients underwent standardized measurement of active range of motion including forward elevation, abduction, and external rotation at the side, all of which were expressed in degrees; and internal rotation to the back, expressed as the highest spinous

https://doi.org/10.5397/cise.2022.01088

process level attained with the thumb on the operative side. Internal rotation levels were transformed to a 10-point scale as for the Constant score [28]. Self-assessed outcomes were evaluated pre-operatively and at the most recent follow-up using the 10-point visual analog scale (VAS) for pain, the Simple Shoulder Test (SST), and the American Shoulder and Elbow Surgeons (ASES) score. True AP in external rotation (Grashey) and axillary-lateral plain radiograph views were obtained in all but two patients at most recent follow-up. In addition, intraoperative and postoperative complications and all repeat operations, including revision shoulder arthroplasty, were identified and reported.

Statistical Analysis

Preoperative active range of motion, SST, ASES, and VAS pain scores were compared to those at the most recent follow-up. Final range of motion and self-assessed outcome, as well as improvements in both, were also compared between RHA and TSA. Similarly, the results for chondrolysis were pooled and compared to those for the other diagnoses. Statistical analysis was performed on Excel (Microsoft Excel for Mac, Redmond, WA, USA) using the paired or unpaired t-test or Wilcoxon signed rank test, as appropriate.

RESULTS

Between January 2008 and December 2017, the senior author performed 1057 PSAs, including 511 anatomic TSAs, 400 reverse TSAs, 94 stemmed HAs, and 52 RHAs, including revisions. Forty-two of these (4.1%) were performed in patients 40 years or younger. Five patients younger than 40 years underwent revision shoulder arthroplasty, including two patients in this study, but their outcomes following revision shoulder arthroplasty are not included. Two additional patients were excluded because PSA was performed as part of salvage revision surgery for recurrent traumatic anterior shoulder instability with combined massive glenoid and humeral bone loss, and five patients (six shoulders) were lost to follow-up. The remaining 29 shoulders in 26 patients were available for clinical and self-assessment follow-up at a mean of 5.0 years (range, 24 months– 11 years) postoperatively.

Nine shoulders in eight patients underwent TSA, including three shoulders in two patients undergoing the ream-and-run procedure. Twenty shoulders in 18 patients underwent RHA (Figs. 1 and 2). Twelve shoulders underwent PSA for chondrolysis, seven shoulders for osteonecrosis, six for capsulorrhaphy arthropathy, two for primary osteoarthritis, and two for post-traumatic arthritis. Twenty-one of 29 shoulders (72.4%) underwent previous surgery (range, 1–3 surgeries), including 21 of 22 shoulders with a diagnosis other than osteonecrosis. Patient characteristics, including type of PSA, are shown in Table 1, stratified by diagnosis. Follow-up for PSA performed for chondrolysis was significantly longer than that for PSA performed for other diagnoses (7.2 ± 2.6 years vs. 3.7 ± 2.2 years, $p < 0.001$).

Nineteen PSAs were performed in 17 male patients and nine PSAs in nine female patients. Mean age at arthroplasty was 31.2

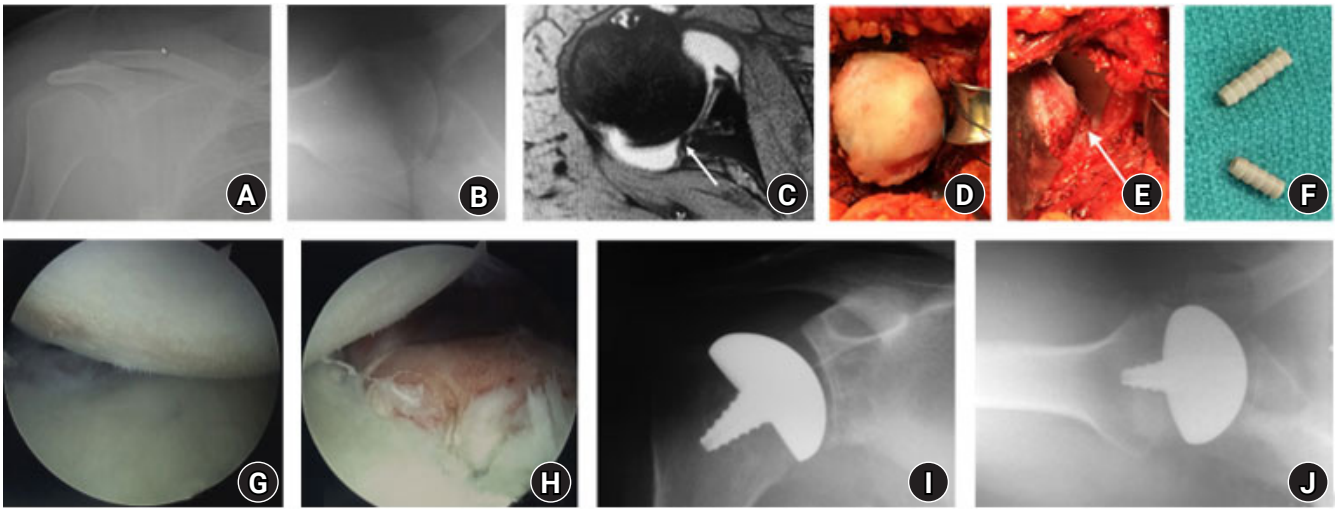

Fig. 1. Resurfacing hemiarthroplasty for glenohumeral chondrolysis secondary to prominent anchors on the articular face in a 19-year-old woman. (A, B) Preoperative radiographs. (C) Preoperative magnetic resonance imaging demonstrating a prominent anchor (arrow). (D, E) Intraoperative images: the arrow points to the site of two prominent anchors removed from the anteroinferior glenoid face. (F) Two anchors removed from the glenoid face. (G, H) Arthroscopic images from a "second-look" arthroscopy performed elsewhere prior to resurfacing demonstrating humeral chondral thinning and labrum repair. (I, J) Postoperative radiographs demonstrating resurfacing hemiarthroplasty.

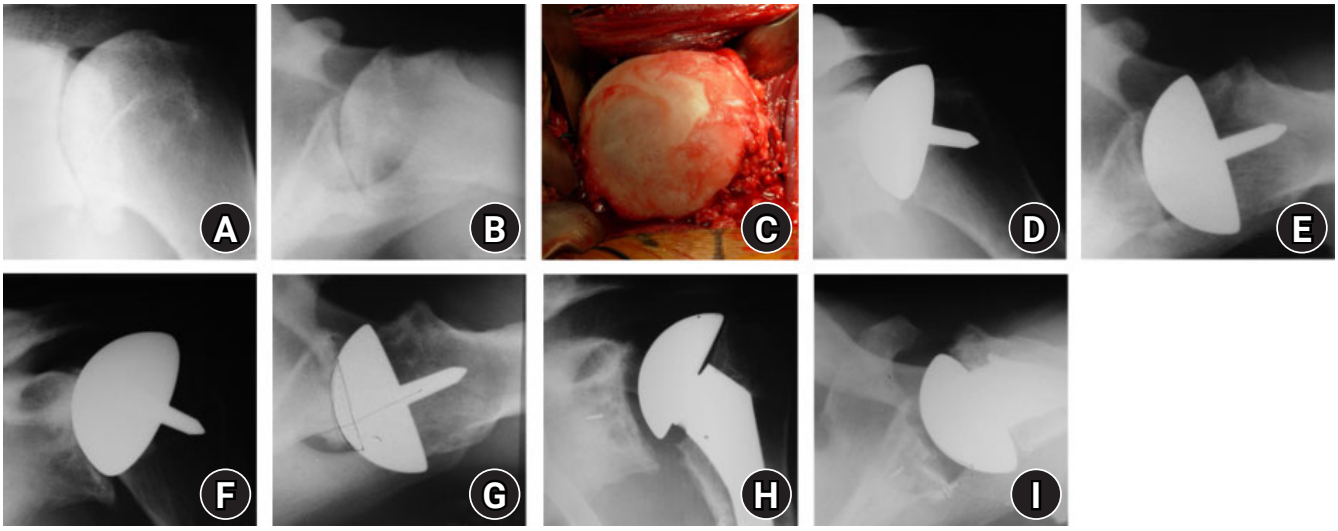

Fig. 2. A 24-year-old man with glenohumeral chondrolysis secondary to infusion of local anesthetics after instability repair. (A, B) Preoperative radiographs. (C) Intraoperative findings. (D, E) Early postoperative radiographs after resurfacing hemiarthroplasty. (F, G) Progressive glenoid erosion and humeral head subluxation at 24 months postoperative. (H, I) Recentered glenohumeral joint after revision to total shoulder arthroplasty with augmented glenoid component.

Table 1. Characteristics of the 29 shoulders, stratified by diagnosis

Demographic	Chondrolysis	Other
Number	12	17
Age (yr), mean ± SD	25.6 ± 8.3	35.1 ± 4.4
Sex (male:female)	6:6	13:4
Previous surgery	12	9
RHA:TSA (including ream-and-run)	8:4	12:5
Subsequent surgery (patient)	7 (6)	4 (2)
Revision	4	1

Values are presented as mean ± standard deviation or number (%).
SD: standard deviation, RHA: resurfacing hemiarthroplasty, TSA: total shoulder arthroplasty.

years (range, 17–40 years). With the numbers available, patients undergoing primary PSA for chondrolysis were significantly younger than patients undergoing PSA for other diagnoses (25.6 vs. 35.1, $p < 0.001$). Additionally, patients undergoing RHA were slightly younger (30.2 vs. 33.3 years, p = not significant) than those undergoing TSA.

For the entire cohort at the most recent follow-up, mean active forward elevation improved from 102° preoperatively to 141°, active abduction improved from 91° to 126°, active external rotation improved from 26° to 43° ($p < 0.001$ for all), and active internal rotation improved from L5 to T12 spinous process ($p < 0.005$). Mean VAS-pain score improved from 6.3 to 2.1 ($p < 0.001$), mean SST improved from 4.0 to 9.0 ($p < 0.001$), and mean ASES score improved from 38 to 75 ($p < 0.001$).

The outcomes stratified by diagnosis and by treatment are demonstrated in Tables 2 and 3, respectfully. Patients undergoing TSA had less preoperative external rotation than patients undergoing RHA (14° vs. 31°, $p < 0.05$). Otherwise, RHA and TSA patients had similar pre- and postoperative range of motion and outcomes scores. Patients undergoing PSA for chon-

Table 2. Active range of motion and patient reported outcomes, stratified by diagnosis

Measure	Preoperative	Postoperative	p-value
Chondrolysis (n = 12)			
FE (°)	110 ± 30	135 ± 23	0.06
AB (°)	95 ± 26	129 ± 32	< 0.05
ER (°)	26 ± 23	46 ± 12	< 0.01
IR*	6.3 ± 1.2	7.3 ± 1.2	NS
VAS-pain	6.9 ± 1.1	1.4 ± 1.1	< 0.001
SST	3.8 ± 2.7	8.9 ± 2.2	< 0.005
ASES score	35 ± 15	81 ± 10	< 0.005
Other (n = 17)			
FE (°)	97 ± 24	144 ± 19	< 0.001
AB (°)	88 ± 26	124 ± 33	< 0.001
ER (°)	26 ± 16	42 ± 12	< 0.001
IR*	6.2 ± 1.9	8.0 ± 1.4	< 0.005
VAS-pain	6.0 ± 2.1	2.6 ± 2.6	< 0.001
SST	4.1 ± 3.1	9.1 ± 2.7	< 0.001
ASES score	39 ± 15	76 ± 21	< 0.001

Values are presented as mean ± standard deviation.
FE: forward elevation, AB: abduction, ER: external rotation (at the side), IR: internal rotation (to the back), NS: not significant, VAS: visual analog scale, SST: Simple Shoulder Test, ASES: American Shoulder and Elbow Surgeons.
*IR levels were transformed to a 10-point scale as for the Constant score [28].

https://doi.org/10.5397/cise.2022.01088

Table 3. Active range of motion and patient reported outcomes, stratified by treatment

Measure	Preoperative	Postoperative	p-value
RHA (n = 20)			
FE (°)	98 ± 29	143 ± 21	< 0.001
AB (°)	90 ± 29	128 ± 29	< 0.005
ER (°)	31 ± 17	47 ± 11	< 0.001
IR*	6.4 ± 1.6	7.9 ± 1.3	< 0.05
VAS-pain	6.3 ± 2.0	1.9 ± 2.0	< 0.001
SST	3.8 ± 3.2	9.1 ± 2.4	< 0.001
ASES	38 ± 17	78 ± 19	< 0.001
TSA† (n = 9)			
FE (°)	112 ± 19	135 ± 22	< 0.05
AB (°)	93 ± 17	121 ± 39	NS
ER (°)	14 ± 17	37 ± 12	< 0.001
IR*	5.9 ± 1.8	7.2 ± 1.3	0.06
VAS-pain	6.4 ± 1.4	2.6 ± 2.7	< 0.05
SST	4.4 ± 2.2	8.8 ± 2.7	< 0.05
ASES	38 ± 12	71 ± 25	< 0.01

Values are presented as mean ± standard deviation.
RHA: resurfacing hemiarthroplasty, FE: forward elevation, AB: abduction, ER: external rotation (at the side), IR: internal rotation (to the back), VAS: visual analog scale, SST: Simple Shoulder Test, ASES: American Shoulder and Elbow Surgeons, TSA: total shoulder arthroplasty, NS: not significant.
*IR levels were transformed to a 10-point scale as for the Constant score [28]; †Including three shoulders that underwent ream-and-run procedures.

drolysis as well as those receiving PSA for other diagnoses had similar pre- and postoperative range of motion and outcomes scores ($p > 0.05$).

There were no intraoperative or immediate postoperative complications. Seven of 29 shoulders (24.1%) have undergone 11 reoperations, including five revision shoulder arthroplasties. Three RHAs underwent revision to TSA, including a revision performed elsewhere for progressive glenoid erosion at 8 years postoperatively. One patient underwent two-stage revision to reverse shoulder arthroplasty for glenoid implant loosening with uncontained glenoid defect requiring structural bone graft at age 47 years, 8 years postoperatively. One ream-and-run patient underwent single-stage reimplantation for prosthetic joint infection. Four of five shoulders undergoing revision surgery had an original diagnosis of chondrolysis.

Additionally, the ream-and-run patient underwent arthroscopic lysis of adhesions twice, before and after single-stage revision. The patient who was ultimately revised from RHA to TSA at 8 years postoperatively had previously undergone arthroscopic lysis of adhesions 18 months after RHA. One patient underwent arthroscopy-assisted open biceps tenodesis 3 months postoperatively, with a good clinical result maintained at 8 years postoperatively. Finally, one patient who underwent bilateral ream-and-run procedures underwent left suprascapular nerve release elsewhere, with substantial improvement in symptoms and good clinical result maintained at 4 years postoperatively.

DISCUSSION

PSA for glenohumeral arthritis in young patients is a challenging proposition because patients often expect, in addition to pain relief, the ability to return to physical work or sports [21,23]. For some patients, these expectations remain unmet after PSA; for others, return to strenuous activities places greater motion and loading demands on the PSA and might lead to accelerated wear or early loosening. Additionally, the underlying diagnosis in young patients is typically inflammatory arthritis or various types of secondary arthritis such as chondrolysis, capsulorrhaphy arthropathy, or osteonecrosis, rather than primary osteoarthritis. Therefore, these patients present with a unique set of complex pathologies and treatment challenges [29].

Not surprisingly, patient satisfaction in younger patients following PSA has historically been disappointing. Schoch et al. [24] and Sperling et al. [25,26] have reported on the results of HA and TSA in patients with glenohumeral arthritis who were younger than 50 years. Follow-up at 15 years confirmed long-term pain relief and improvement in shoulder motion after both procedures. Still, 60% of patients undergoing HA and 48% of patients undergoing TSA were dissatisfied with their result [26]. More recently, Wagner et al. [30] studied the role of age in the outcomes and complications of PSA in a large institutional database and found that the risk of revision surgery decreased linearly between ages 40 and 85, with each 1 year increase in age showing a 3% decrease in risk of revision. The authors [30] concluded that there is a strong association between young age and increased rates of revision surgery and reoperation because of mechanical failure after PSA.

Our study included patients undergoing RHA and TSA. In general, RHA was performed on patients younger than 30 years or when the glenoid was unaffected or concentrically eroded; otherwise, TSA was performed. An economic decision study employing a Markov chain decision tree model demonstrated an advantage of TSA over HA in patients between age 30 and 50 years [31]. Compared with HA, TSA required fewer revisions, greater cost savings, and greater quality adjusted life years gained. HA avoids the problems associated with glenoid implantation, including late loosening. However, painful glenoid erosion may hasten the need for revision surgery.

RHA aims to avoid humeral head resection and use of an in-

tramedullary stem and to preserve the native anatomy of the glenohumeral joint. Optimal positioning of the resurfacing implant should, in theory, preserve native humeral head inclination, offset, and version and facilitate late revision to an anatomic TSA when this becomes necessary [32]. Levy et al. [33] reported 81.6% survivorship and high patient satisfaction at a minimum of 10 years following RHA in a group of patients aged 50 years or younger, with a mean age of 39 years. Other studies have demonstrated good short- and mid-term clinical results and durability in younger patients [21,34-36], although at least one study has demonstrated poor durability and patient satisfaction [37].

Survivorship of TSA has typically exceeded that of HA. Schoch et al. [24] reported that survivorship of HA was 82% at 10 years and 75% at 20 years; and survivorship of TSA was 97% and 84% at 10 and 20 years, respectively . However, most of the patients in that study had post-traumatic or inflammatory arthritis, and none had chondrolysis [24,26]. In a related study employing the same institutional database, Bartelt et al. [22] studied the long-term outcomes of PSA specifically for osteoarthritis in patients younger than 55 years. Implant survivorship at 10 years was 92% for TSAs and 72% for HAs [22]. Substantial glenoid periprosthetic lucencies or a shift in component position was identified in 10 of 34 TSAs, and at least moderate severity glenoid erosion was identified in 6 of 13 HAs. However, the authors concluded that TSA offered advantages over HA in terms of pain relief, shoulder range of motion, and implant survival [22]. Eichinger et al. [23] evaluated patient satisfaction and implant durability rates following PSA. The authors reported 5-year survivorship of 89% for HA and 95% for TSA. However, corresponding rates of patient satisfaction at 5 years were 72% and 95%, respectively. The authors noted discordance between patient satisfaction and implant survival, especially for HA [23].

In the youngest and most active patients, the benefits of a polyethylene glenoid implant may need to be balanced against the risk of glenoid implant loosening. Concerns over glenoid implant loosening and progressive glenoid erosion have motivated the development of alternatives including biologic glenoid resurfacing and the ream-and-run procedure [12,38]. No patient in this series underwent biologic glenoid resurfacing using soft tissue interposition because of a preponderance of studies demonstrating poor outcomes and survivorship when using this procedure [39-43]. For example, Elhassan et al. [39] reported that 10 of 13 patients (77%) undergoing HA combined with biologic glenoid resurfacing required revision to TSA for persistent pain at a mean of 14 months follow-up. Radiographs demonstrated rapid and progressive joint space narrowing and glenoid erosion. Muh et al. [44] demonstrated initial improvements in pain and function following HA with biologic glenoid resurfacing in patients 55 years old or younger, but the revision rate was 44% at a mean 36 months follow-up. A recent systematic review of the results of biologic glenoid resurfacing combined with HA documented an overall complication rate of 36%, a revision surgery rate of 34%, and a clinical failure rate of 43% [45].

The ream-and-run procedure combines HA with concentric spherical glenoid reaming to correct glenoid articular surface incongruity in order to recenter the humeral head and create durable glenoid articulation without implant or graft [46-53]. The procedure provides an alternative to TSA using a conventional all-polyethylene glenoid implant. Its development was motivated by concerns over early glenoid implant loosening, especially in younger, more active patients, and the unpredictable results following either glenoid implant removal or revision implantation [49]. Recent studies have demonstrated higher rates of return to sports and strenuous work following ream-and-run compared with TSA [48,52]. In our series, one patient with severe bilateral posterior glenoid erosion and dysplasia underwent staged bilateral ream-and-run procedures at 20 and 24 years of age to partially correct glenoid version and create a smooth articulation. Another patient with capsulorrhaphy arthropathy underwent ream-and-run at age 32 years.

The mean age of patients undergoing PSA in this series was only 31.2 years, which is nearly a decade younger than in any previously published report. Additionally, the mean age of patients undergoing RHA was only 30.2 years; and RHA was performed in 8 of 10 shoulders performed at age 26 years or younger. We did not consider implanting a glenoid component in these patients for several reasons: to preserve glenoid bone stock for eventual revision, to avoid the glenoid exposure challenges that accompany humeral head preservation, and to avoid the risk of early glenoid implant failure.

Three of 20 RHA patients (15%) required revision to TSA, at 30, 42, and 91 months postoperatively. All three patients had chondrolysis and developed progressive glenoid erosion, and none had evidence of implant loosening or any intraoperative or postoperative signs of prosthetic joint infection. All three patients reported improvements in range of motion and outcome following their revisions.

Six all-polyethylene glenoid components were implanted in this series of patients 40 years or younger, comprising the nine in the TSA group less the three ream-and-run procedures. One patient underwent staged glenoid implant removal and bone graft of an uncontained glenoid defect at age 47 years and 95 months postoperatively, followed by revision to reverse shoulder arthroplasty 3 months later. The remaining five glenoid components

https://doi.org/10.5397/cise.2022.01088

have survived for a mean follow-up of 78 months.

The rate of revision surgery varied by underlying diagnosis. Twelve patients in this series were initially diagnosed with chondrolysis, accounting for nine of the 10 shoulders. The patients undergoing PSA were 26 years or younger. Four of the five PSAs that underwent revision, including that performed at a different care facility, were patients with chondrolysis. This includes three RHA patients who underwent early revision for glenoid arthrosis and a single TSA patient who underwent revision for glenoid loosening at approximately 8 years postoperatively. Overall, four of 12 (33.3%) shoulders with chondrolysis have undergone revision PSA, compared to only one shoulder with another diagnosis.

Chondrolysis patients demonstrated high revision rates, which may relate to the underlying diagnosis as well as the development of painful glenoid arthrosis following RHA. However, these high rates may also relate to their young age and substantially longer duration of follow-up than patients undergoing PSA for other diagnoses (7.2 vs. 3.7 years). In a large retrospective review of a single health care system database, Dillon et al. [54] reported that patients younger than 59 years had a two-fold higher risk of early revision than patients older than 59 years following PSA. A recent multicenter study evaluating the results of treatment for osteoarthritis and capsulorrhaphy arthropathy in patients 50 years or younger found that complication and revision rates were substantially higher following HA than TSA [55]. Another study recently demonstrated that prior non-arthroplasty surgery was associated with inferior patient reported outcomes and higher revision rates after TSA [56]. Collectively, these studies raise concerns over the influence of diagnosis, prior surgeries, and high functional demands experienced by young patients on implant durability and the need for revision surgery.

Several studies have noted the relatively modest functional gains and high pain levels following PSA for chondrolysis [19,20,27]. We previously reported on the short-term results of PSA for glenohumeral chondrolysis that included patients older than age 40 and found that mean active forward elevation improved 47° to 140°, mean active abduction improved 50° to 131°, and mean active external rotation improved 27° to 49°; these were all statistically significant improvements [19]. In addition, mean VAS-pain scores improved significantly to 3.4; and mean ASES scores and SST improved significantly, from 37 to 66 and from 4 to 8, respectively.

Levy et al. [27] reported on 11 patients with a mean age of 39, ranging from 16 to 64 years and including two patients, aged 16 and 18 years, who underwent total shoulder replacement for chondrolysis. The authors [27] found statistically significant improvements in range of motion, including gains of 34° in active abduction and 22° in active external rotation; but the 16° improvement in active forward elevation was not statistically significant due to limited sample size. In addition, ASES scores improved significantly from 30 to 77 and SST from 3 to 8 [27]. The ASES pain score improved to 36.4, equivalent to a VAS-pain score of 2.9.

Schoch et al. [20] reported on 26 patients undergoing PSA for chondrolysis after shoulder arthroscopy including patients 21 to 58 years old with a mean age of 40 years. Twenty-three of 26 patients were followed for a minimum of 2 years or until reoperation, with a mean follow-up of 4 years, comparable to the follow-up in the present series. The authors [20] found that pain scores improved from 4.7 to 2.6, but only 14 of 23 patients decreased to mild or no pain. Five of 23 patients (21.7%) required reoperation, including two for glenoid loosening and one each for infection, instability, and stiffness [20]. Mean ASES score was 64, and eight patients (35%) rated their shoulder as the same or worse [20]. The authors concluded that, although PSA for chondrolysis improves pain and mobility, patient satisfaction is variable, and the reoperation rate is unexpectedly high. Therefore, patients undergoing PSA for chondrolysis should be counseled about postoperative expectations [20].

Collectively, the results of previous studies and those presented here indicate challenges in treating relatively young patients with end-stage glenohumeral arthritis. These patients often have residual shoulder pain following PSA, which dampens their self-assessed outcomes. This is especially true of patients with chondrolysis, who often present with high pain levels and marked joint stiffness and who respond less predictably to PSA. In addition, although avoidance of a glenoid implant may be desirable, the rate of revision from RHA to TSA reported here is concerning, especially given the young patient ages. No fewer than five of the 29 shoulders in this series have undergone multiple subscapularis tenotomy for surgical exposure during PSA, causing concerns over the potential for subscapularis muscle atrophy and tendon attenuation and a negative clinical impact over time.

Study limitations include a relatively short follow-up of a small cohort of patients with heterogeneous diagnoses and treatments. However, the varied diagnoses underscore the reality that young patients today develop end-stage glenohumeral arthrosis, rather than primary osteoarthritis or inflammatory arthritis, from prior surgery or other treatments. Longer follow-up will be needed to evaluate the overall survival of both RHA and TSA cohorts. However, this study represents an initial report on the outcomes of relatively young patients following PSA.

This study demonstrates that PSA in young patients provides

substantial improvement in active range of motion and patient reported outcomes in most patients, irrespective of diagnosis and glenoid management. However, one-third of chondrolysis patients underwent revision surgery during the study period, including three RHAs revised to TSAs due to glenoid wear. Therefore, we cannot recommend RHA in chondrolysis cases. Additionally, RHA should be considered with caution in young patients and performed only after shared decision-making and counsel about the risk of early revision to TSA.

ORCID

Samer S. Hasan	https://orcid.org/0000-0002-5344-9245
Leslie E. Schwindel	https://orcid.org/0000-0002-7210-3557
Cassie M. Fleckenstein	https://orcid.org/0000-0002-3172-4349

REFERENCES

1. Khatib O, Onyekwelu I, Yu S, Zuckerman JD. Shoulder arthroplasty in New York State, 1991 to 2010: changing patterns of utilization. J Shoulder Elbow Surg 2015;24:e286-91.
2. Kim SH, Wise BL, Zhang Y, Szabo RM. Increasing incidence of shoulder arthroplasty in the United States. J Bone Joint Surg Am 2011;93:2249-54.
3. Padegimas EM, Maltenfort M, Lazarus MD, Ramsey ML, Williams GR, Namdari S. Future patient demand for shoulder arthroplasty by younger patients: national projections. Clin Orthop Relat Res 2015;473:1860-7.
4. Trofa D, Rajaee SS, Smith EL. Nationwide trends in total shoulder arthroplasty and hemiarthroplasty for osteoarthritis. Am J Orthop (Belle Mead NJ) 2014;43:166-72.
5. Bryant D, Litchfield R, Sandow M, Gartsman GM, Guyatt G, Kirkley A. A comparison of pain, strength, range of motion, and functional outcomes after hemiarthroplasty and total shoulder arthroplasty in patients with osteoarthritis of the shoulder: a systematic review and meta-analysis. J Bone Joint Surg Am 2005;87:1947-56.
6. Gartsman GM, Roddey TS, Hammerman SM. Shoulder arthroplasty with or without resurfacing of the glenoid in patients who have osteoarthritis. J Bone Joint Surg Am 2000;82:26-34.
7. Hasan SS, Fleckenstein CM. Glenohumeral chondrolysis: part I: clinical presentation and predictors of disease progression. Arthroscopy 2013;29:1135-41.
8. Matsen FA, Papadonikolakis A. Published evidence demonstrating the causation of glenohumeral chondrolysis by postoperative infusion of local anesthetic via a pain pump. J Bone Joint Surg Am 2013;95:1126-34.
9. Johnson MH, Paxton ES, Green A. Shoulder arthroplasty options in young (< 50 years old) patients: review of current concepts. J Shoulder Elbow Surg 2015;24:317-25.
10. Bhatia S, Hsu A, Lin EC, et al. Surgical treatment options for the young and active middle-aged patient with glenohumeral arthritis. Adv Orthop 2012;2012:846843.
11. McCarty LP, Cole BJ. Nonarthroplasty treatment of glenohumeral cartilage lesions. Arthroscopy 2005;21:1131-42.
12. Saltzman BM, Leroux TS, Verma NN, Romeo AA. Glenohumeral osteoarthritis in the young patient. J Am Acad Orthop Surg 2018;26:e361-70.
13. Cameron BD, Galatz LM, Ramsey ML, Williams GR, Iannotti JP. Non-prosthetic management of grade IV osteochondral lesions of the glenohumeral joint. J Shoulder Elbow Surg 2002;11:25-32.
14. Millett PJ, Gaskill TR. Arthroscopic management of glenohumeral arthrosis: humeral osteoplasty, capsular release, and arthroscopic axillary nerve release as a joint-preserving approach. Arthroscopy 2011;27:1296-303.
15. Millett PJ, Horan MP, Pennock AT, Rios D. Comprehensive arthroscopic management (CAM) procedure: clinical results of a joint-preserving arthroscopic treatment for young, active patients with advanced shoulder osteoarthritis. Arthroscopy 2013;29:440-8.
16. Van Thiel GS, Sheehan S, Frank RM, et al. Retrospective analysis of arthroscopic management of glenohumeral degenerative disease. Arthroscopy 2010;26:1451-5.
17. Weinstein DM, Bucchieri JS, Pollock RG, Flatow EL, Bigliani LU. Arthroscopic debridement of the shoulder for osteoarthritis. Arthroscopy 2000;16:471-6.
18. Sayegh ET, Mascarenhas R, Chalmers PN, Cole BJ, Romeo AA, Verma NN. Surgical treatment options for glenohumeral arthritis in young patients: a systematic review and meta-analysis. Arthroscopy 2015;31:1156-66.e8.
19. Hasan SS, Fleckenstein CM. Glenohumeral chondrolysis: part II: results of treatment. Arthroscopy 2013;29:1142-8.
20. Schoch B, Werthel JD, Cofield R, Sanchez-Sotelo J, Sperling JW. Shoulder arthroplasty for chondrolysis. J Shoulder Elbow Surg 2016;25:1470-6.
21. Bailie DS, Llinas PJ, Ellenbecker TS. Cementless humeral resurfacing arthroplasty in active patients less than fifty-five years of age. J Bone Joint Surg Am 2008;90:110-7.
22. Bartelt R, Sperling JW, Schleck CD, Cofield RH. Shoulder arthroplasty in patients aged fifty-five years or younger with osteoarthritis. J Shoulder Elbow Surg 2011;20:123-30.
23. Eichinger JK, Miller LR, Hartshorn T, Li X, Warner JJ, Higgins LD. Evaluation of satisfaction and durability after hemiarthro-

https://doi.org/10.5397/cise.2022.01088

plasty and total shoulder arthroplasty in a cohort of patients aged 50 years or younger: an analysis of discordance of patient satisfaction and implant survival. J Shoulder Elbow Surg 2016;25:772-80.
24. Schoch B, Schleck C, Cofield RH, Sperling JW. Shoulder arthroplasty in patients younger than 50 years: minimum 20-year follow-up. J Shoulder Elbow Surg 2015;24:705-10.
25. Sperling JW, Cofield RH, Rowland CM. Neer hemiarthroplasty and Neer total shoulder arthroplasty in patients fifty years old or less: long-term results. J Bone Joint Surg Am 1998;80:464-73.
26. Sperling JW, Cofield RH, Rowland CM. Minimum fifteen-year follow-up of Neer hemiarthroplasty and total shoulder arthroplasty in patients aged fifty years or younger. J Shoulder Elbow Surg 2004;13:604-13.
27. Levy JC, Virani NA, Frankle MA, Cuff D, Pupello DR, Hamelin JA. Young patients with shoulder chondrolysis following arthroscopic shoulder surgery treated with total shoulder arthroplasty. J Shoulder Elbow Surg 2008;17:380-8.
28. Rill BK, Fleckenstein CM, Levy MS, Nagesh V, Hasan SS. Predictors of outcome after nonoperative and operative treatment of adhesive capsulitis. Am J Sports Med 2011;39:567-74.
29. Saltzman MD, Mercer DM, Warme WJ, Bertelsen AL, Matsen FA. Comparison of patients undergoing primary shoulder arthroplasty before and after the age of fifty. J Bone Joint Surg Am 2010;92:42-7.
30. Wagner ER, Houdek MT, Schleck CD, et al. The role age plays in the outcomes and complications of shoulder arthroplasty. J Shoulder Elbow Surg 2017;26:1573-80.
31. Bhat SB, Lazarus M, Getz C, Williams GR, Namdari S. Economic decision model suggests total shoulder arthroplasty is superior to hemiarthroplasty in young patients with end-stage shoulder arthritis. Clin Orthop Relat Res 2016;474:2482-92.
32. Jensen KL. Humeral resurfacing arthroplasty: rationale, indications, technique, and results. Am J Orthop (Belle Mead NJ) 2007;36(12 Suppl 1):4-8.
33. Levy O, Tsvieli O, Merchant J, et al. Surface replacement arthroplasty for glenohumeral arthropathy in patients aged younger than fifty years: results after a minimum ten-year follow-up. J Shoulder Elbow Surg 2015;24:1049-60.
34. Iagulli ND, Field LD, Hobgood ER, et al. Surface replacement arthroplasty of the humeral head in young, active patients: mid-term results. Orthop J Sports Med 2014;2:2325967113519407.
35. Merolla G, Bianchi P, Lollino N, Rossi R, Paladini P, Porcellini G. Clinical and radiographic mid-term outcomes after shoulder resurfacing in patients aged 50 years old or younger. Musculoskelet Surg 2013;97 Suppl 1:23-9.
36. Raiss P, Pape G, Becker S, Rickert M, Loew M. Cementless humeral surface replacement arthroplasty in patients less than 55 years of age. Orthopade 2010;39:201-8.
37. Rispoli DM, Sperling JW, Athwal GS, Schleck CD, Cofield RH. Humeral head replacement for the treatment of osteoarthritis. J Bone Joint Surg Am 2006;88:2637-44.
38. Brolin TJ, Thakar OV, Abboud JA. Outcomes after shoulder replacement surgery in the young patient: how do they do and how long can we expect them to last. Clin Sports Med 2018;37:593-607.
39. Elhassan B, Ozbaydar M, Diller D, Higgins LD, Warner JJ. Soft-tissue resurfacing of the glenoid in the treatment of glenohumeral arthritis in active patients less than fifty years old. J Bone Joint Surg Am 2009;91:419-24.
40. Hammond LC, Lin EC, Harwood DP, et al. Clinical outcomes of hemiarthroplasty and biological resurfacing in patients aged younger than 50 years. J Shoulder Elbow Surg 2013;22:1345-51.
41. Lee KT, Bell S, Salmon J. Cementless surface replacement arthroplasty of the shoulder with biologic resurfacing of the glenoid. J Shoulder Elbow Surg 2009;18:915-9.
42. Lollino N, Pellegrini A, Paladini P, Campi F, Porcellini G. Gleno-Humeral arthritis in young patients: clinical and radiographic analysis of humerus resurfacing prosthesis and meniscus interposition. Musculoskelet Surg 2011;95 Suppl 1:S59-63.
43. Puskas GJ, Meyer DC, Lebschi JA, Gerber C. Unacceptable failure of hemiarthroplasty combined with biological glenoid resurfacing in the treatment of glenohumeral arthritis in the young. J Shoulder Elbow Surg 2015;24:1900-7.
44. Muh SJ, Streit JJ, Shishani Y, Dubrow S, Nowinski RJ, Gobezie R. Biologic resurfacing of the glenoid with humeral head resurfacing for glenohumeral arthritis in the young patient. J Shoulder Elbow Surg 2014;23:e185-90.
45. Meaike JJ, Patterson DC, Anthony SG, Parsons BO, Cagle PJ. Soft tissue resurfacing for glenohumeral arthritis: a systematic review. Shoulder Elbow 2020;12:3-11.
46. Clinton J, Franta AK, Lenters TR, Mounce D, Matsen FA. Nonprosthetic glenoid arthroplasty with humeral hemiarthroplasty and total shoulder arthroplasty yield similar self-assessed outcomes in the management of comparable patients with glenohumeral arthritis. J Shoulder Elbow Surg 2007;16:534-8.
47. Gilmer BB, Comstock BA, Jette JL, Warme WJ, Jackins SE, Matsen FA. The prognosis for improvement in comfort and function after the ream-and-run arthroplasty for glenohumeral arthritis: an analysis of 176 consecutive cases. J Bone Joint Surg Am 2012;94:e102.
48. Gowd AK, Garcia GH, Liu JN, Malaret MR, Cabarcas BC, Romeo AA. Comparative analysis of work-related outcomes in hemiarthroplasty with concentric glenoid reaming and total

shoulder arthroplasty. J Shoulder Elbow Surg 2019;28:244-51.
49. Hasan SS. Revisiting the socket: commentary on an article by Jeremy S. Somerson, MD, et al.: "Clinical and radiographic outcomes of the ream-and-run procedure for primary glenohumeral arthritis". J Bone Joint Surg Am 2017;99:e85.
50. Matsen FA. The ream and run: not for every patient, every surgeon or every problem. Int Orthop 2015;39:255-61.
51. Somerson JS, Neradilek MB, Service BC, Hsu JE, Russ SM, Matsen FA. Clinical and radiographic outcomes of the ream-and-run procedure for primary glenohumeral arthritis. J Bone Joint Surg Am 2017;99:1291-304.
52. Virk MS, Thorsness RJ, Griffin JW, et al. Short-term clinical outcomes of hemiarthroplasty with concentric glenoid reaming: the ream and run procedure. Orthopedics 2018;41:e854-60.
53. Matsen FA, Carofino BC, Green A, et al. Shoulder hemiarthroplasty with nonprosthetic glenoid arthroplasty: the ream-and-run procedure. JBJS Rev 2021;9:e20.00243.
54. Dillon MT, Inacio MC, Burke MF, Navarro RA, Yian EH. Shoulder arthroplasty in patients 59 years of age and younger. J Shoulder Elbow Surg 2013;22:1338-44.
55. Kany J, Benkalfate T, Favard L, et al. Osteoarthritis of the shoulder in under-50 year-olds: a multicenter retrospective study of 273 shoulders by the French Society for Shoulder and Elbow (SOFEC). Orthop Traumatol Surg Res 2021;107:102756.
56. Schiffman CJ, Hannay WM, Whitson AJ, Neradilek MB, Matsen FA, Hsu JE. Impact of previous non-arthroplasty surgery on clinical outcomes after primary anatomic shoulder arthroplasty. J Shoulder Elbow Surg 2020;29:2056-64.

https://doi.org/10.5397/cise.2022.01088

Original Article

Clin Shoulder Elbow 2022;25(4):321-327
https://doi.org/10.5397/cise.2022.01109

CiSE
Clinics in Shoulder and Elbow

eISSN 2288-8721

Reliability of the scapular dyskinesis test yes-no classification in asymptomatic individuals between students and expert physical therapists

Lawrence S. Ramiscal[1,#], Lori A. Bolgla[1], Chad E. Cook[2], John S. Magel[3], Stephen A. Parada[4], Raymond Chong[5]

[1]*Department of Physical Therapy, Augusta University, Augusta, GA, USA*
[2]*Division of Physical Therapy, Duke University, Durham, NC, USA*
[3]*Department of Physical Therapy and Athletic Training, University of Utah, Salt Lake City, UT, USA*
[4]*Department of Orthopedic Surgery, Augusta University, Augusta, GA, USA*
[5]*Department of Interdisciplinary Health Sciences, Augusta University, Augusta, GA, USA*

Background: Scapular dyskinesis is considered a risk factor for the shoulder pain that may warrant screening for prevention. Clinicians of all experience screen scapular dyskinesis using the scapular dyskinesis test yes-no classification (Y-N), yet its reliability in asymptomatic individuals is unknown. We aimed to establish Y-N's intra- and inter-reliability between students and expert physical therapists.
Methods: We utilized a cross-sectional design using consecutive asymptomatic subjects. Six students and two experts rated 100 subjects using the Y-N. Cohen's kappa (κ) and Krippendorff's alpha (K-α) were calculated to determine intra- and inter-rater reliability.
Results: Intra- and inter-rater values for experts were κ=0.92 (95% confidence interval [CI], 0.91–0.93) and 0.85 (95% CI, 0.84–0.87) respectively; students were κ=0.77 (95% CI, 0.75–0.78) and K-α=0.63 (95% CI, 0.58–0.67).
Conclusions: The Y-N is reliable in detecting scapular dyskinesis in asymptomatic individuals regardless of experience.

Keywords: Dyskinesias; Musculoskeletal system; Physical therapy specialty; Shoulder; Students

INTRODUCTION

Optimal shoulder function requires proper positioning and movement of the scapula on the thorax [1]. Abnormal scapular position or movement patterns during functional activities are defined as scapular dyskinesis [2,3]. Although it is typically associated with shoulder pain [4-6], dyskinesis also can be present in asymptomatic individuals [7-9]. More recent evidence suggests that scapular dyskinesis is a risk factor for shoulder pain [10] that may warrant screening as a preventative measure.

Physical therapists screen for scapular dyskinesis by visually comparing scapular movement asymmetries in overhead reach using the Scapular Dyskinesis Test [3]. The patient performs repeated shoulder elevation and lowering with weights on both

Received: July 6, 2022 Revised: October 9, 2022 Accepted: October 9, 2022
Correspondence to: Lawrence S. Ramiscal
Department of Physical Therapy, Augusta University, Augusta, GA, USA
[#]Current affiliation: Lincoln Memorial University Doctor of Physical Therapy Program, 9731 Cogdill Rd. Rm. 238 Knoxville, TN 37932, USA
Tel: +1-865-338-5778, Fax: +1-865-338-5778, E-mail: lawrence.ramiscal@lmunet.edu, ORCID: https://orcid.org/0000-0002-0230-277X

Financial support: None.
Conflict of interest: None.

hands while the therapist observes scapular motion. The therapist identifies and labels scapular dyskinesis as type 1 when there is an excessive prominence of the inferior angle, as type 2 when there is excess prominence of the medial border or dysrhythmia, or as type 3 with excessive or premature movement of the scapula observed on a single plane of motion. The large numbers of possible abnormal movement patterns and combinations can make it difficult for therapists to agree on a final label. A variant of the test known as the Yes-No classification (Y-N) simply identifies the presence or absence of asymmetry between the shoulders and is more inclusive without need for the therapist to observe multiple separate planes, increasing the reliability [11]. The improved accuracy of the Y-N may be due to its simplicity and dichotomous decision [12]. Novice clinicians, such as physical therapy students, can quickly learn the Y-N as part of their training (e.g., clinical rotations). However, the Y-N involves subjectivity in that it relies heavily on clinician experience and is an observational method [13]. As novices, physical therapy students lack the experience needed for reliable and accurate measurement based on academic and clinical standards, especially in shoulder assessment tools [14,15]. Many studies have compared the reliability between novices and experienced clinicians using other assessment tools (primarily in balance) in physical therapy [16,17]. These studies also found evidence of rater discrepancy due to lack of experience. The Y-N has shown reliability among experienced clinicians [11,18,19]. However, its reliability across varied clinical experiences in the asymptomatic population is unknown.

Therefore, we aimed to determine the intra- and inter-rater reliability of the Y-N in detecting scapular dyskinesis in asymptomatic individuals between students and expert physical therapists. We hypothesized that the Y-N is a reliable tool in detecting scapular dyskinesis among asymptomatic individuals when used by experts but not by students due to lack of experience.

METHODS

Approval was obtained from the Institutional Review Board of Augusta University, and all subjects read and signed a consent form before participating in our study. Especially, the authors obtained consent from the participant whose body was exposed in the figure.

Study Design

A cross-sectional intra- and inter-rater reliability design was utilized.

Subjects

Participants were conveniently sampled from students on the Health Sciences campus of Augusta University. Asymptomatic adults 18–35 years old were recruited using word of mouth and referrals. Table 1 summarizes the exclusion criteria. A screening tool for eligibility included existing medical problems, medications, and pain ratings. The first consecutive 100 healthy asymptomatic subjects that met the criteria were included in the study and underwent evaluation via the Y-N (see Procedures and Instrumentation). Table 2 summarizes the demographic characteristics of the subjects.

Raters

There were eight raters: two experts and six students. The expert raters were licensed and certified orthopedic physical therapy specialists, one with 25 years of clinical experience, considered

Table 2. Demographic characteristics of the subjects

Variable	Value (n = 100)
Age (yr)	24 ± 3
Women	63 (63)
Handedness (right)	89 (89)
History of repeated overhead movement	71 (71)

Values are presented as mean ± standard deviation or number (%).

Table 1. Exclusion criteria

Any of the following
Shoulder pain with activity of 2/10 or greater on the numeric pain rating scale
History of shoulder pain within the past year
Adhesive capsulitis, defined as loss of greater than 50% of passive shoulder range of motion in shoulder external rotation and one other plane of motion
Previous shoulder surgery within the past year
History of shoulder fracture
Systemic musculoskeletal disease (rheumatoid arthritis, fibromyalgia, etc.)
Shoulder pain that was reproduced with active/passive cervical spine motion

https://doi.org/10.5397/cise.2022.01109

the expert gold standard, and the other with 21 years of clinical experience. The student raters were second-year PT students. All raters were blinded to other's data during the study period. Table 3 summarizes the demographic characteristics of the raters.

Procedures and Instrumentation

Scapular dyskinesis test yes-no classification

The Y-N was performed on the 100 subjects and video recorded for later evaluation of presence or absence of scapular dyskinesis (Fig. 1). Male participants were asked to remove their shirts, while women wore sports bras to expose both scapulae. Using a metronome at a rate of 60 beats per minute, participants performed five consecutive non-stop repetitions of bilateral, active, and weighted 120° shoulder flexion using dumbbells based on body weight: 1.4kg (3lb) for those weighing <68.1 kg (150 lb) and 2.3 kg (5 lb) for those >68.1 kg (150 lb) according to the scapular dyskinesis test protocol by McClure at al. [18].

An eight-foot PVC pipe on a wooden base was placed in front of the subjects (two feet from their toes) to standardize shoulder flexion and assure accuracy among the five repetitions. A spring clamp with handles wrapped with bright neon orange tape was clamped to the pole for easy visibility. Subjects' shoulders were passively elevated to align with a goniometer (fixed at 120°) and were held in that position. The clamp was moved roughly at the level of the subjects' middle fingers or a level they would remember to raise their arms during the test. To establish reliability be-

Table 3. Demographic characteristics of reliability study raters

Variable	Expert (n=2)	Student (n=6)
Year of experience	23±3	0
PT education	DPT	2nd year DPT
OCS	2 (100)	0

Values are presented as mean±standard deviation or number (%).
PT: physical therapy, DPT: doctor of physical therapy, OCS: licensed and certified orthopedic physical therapy specialist.



Fig. 1. Scapular dyskinesis test yes-no classification and video recording set-up.

tween repetitions, after determining the clamp's ideal height on the pole, subjects were asked to put their arms to their sides, raise them again to the clamp level, and hold. The fixed goniometer was placed at the shoulders one at a time to verify alignment. This process was repeated until elevation of both arms aligned with the goniometer.

To record the movement, a high-definition digital camera on a tripod equipped with lighting was set up one meter behind the participant at the level of the seventh thoracic spinous process (between the inferior angles of the scapulae). Each video was saved in an MP4 format and labeled with an unidentified subject number assigned during the consent process. All videos were stored in a secure Box folder (server) provided by the Institutional Review Board. After watching the videos independently, raters used the Y-N to label the presence or absence of scapular dyskinesis for each subject they evaluated.

Definitions of operational terms

Yes: Scapular dyskinesis is present (asymmetrical shoulders). Either or both of the following motion abnormalities may be present on either shoulder: (1) dysrhythmia: the scapula demonstrates premature or excessive elevation or protraction, nonsmooth or stuttering motion during arm elevation or lowering, or rapid downward rotation during arm lowering or (2) winging: the medial border or inferior angle of the scapula is posteriorly displaced from the posterior thorax.

No: Scapular dyskinesis is not present (symmetrical shoulders). Both scapulae are stable with minimal motion during the initial 30° to 60° of shoulder elevation. Smooth and continuous scapular rotation upward during elevation and downward during humeral lowering. No evidence of winging.

Student training

Students underwent a two-part standardized training provided by the expert gold standard (Fig. 2). The first part was a didactic format to educate the students on use of the Y-N. The second part was a practical application format where all student raters independently rated sample videos of subjects performing the Y-N to achieve a baseline minimum of substantial agreement (Krippendorff's alpha or K-α = 0.61–0.80) [20] before the study proper.

Rating process

After reaching the required baseline level of agreement (substantial) among the six student raters, the 100 study videos were released to all raters at a rate of 10 per week over the next 10 weeks

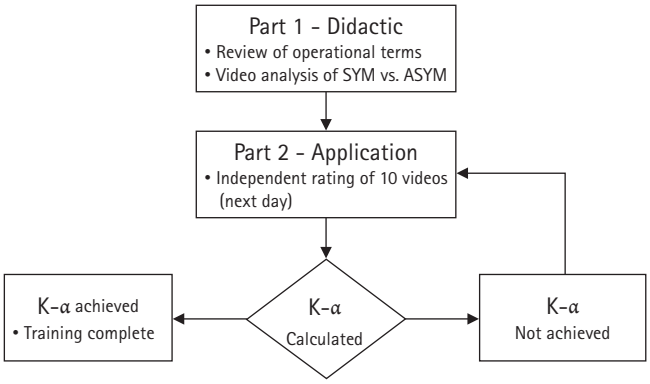

Fig. 2. Student rater training. SYM: symmetrical, ASYM: asymmetrical, K-α: Krippendorff's alpha.

for independent rating. The ratings in this part were used to calculate inter-rater reliability. Access to the videos was closed and the ratings were due at the end of the week. At the end of the 10th week, videos from the first week were re-released for the second round of ratings. Ratings in this part were used to calculate intra-rater reliability.

Sample Size Estimation

A priori power analysis using Real Statistics Resource Pack software, release 7.2, was used to establish reliability. Based on the previously determined inter-reliability Cohen's kappa (κ) value of 0.64 [21] with a significance level of 0.05 and power of 90%, the minimum sample size required to test the null hypothesis κ = 0.3 versus the alternative hypothesis κ = 0.6 was 72.

Statistical Methods

To determine the intra-rater reliability in student and expert raters, κ [22] and its 95% confidence interval (CI) for each rater were calculated between the first and second ratings of the videos from the first week (10 weeks apart) and then averaged. To determine the inter-rater reliability between student raters only, K-α [23] with its 95% CI was calculated. To determine the inter-rater reliability between expert raters only, the κ was calculated. Bootstrapping using the nonparametric (resampling) method, with a sample size of 1,000 that yielded 1,500 pairs, was performed to improve the accuracy of distribution of the alphas and Kappas [20,24]. Without bootstrapping, the CIs were wider (Table 4). The suggested interpretation of both K-α and κ is as follows: < 0.0, poor agreement; 0.0–0.2, slight; 0.21–0.4, fair; 0.41–0.6, moderate; 0.61–0.8, substantial; and 0.81–1, near-perfect [22]. Statistical significance was set at α = 0.05. Statistical tests were performed with IBM SPSS ver. 27 (IBM Corp., Armonk, NY, USA).

https://doi.org/10.5397/cise.2022.01109

Table 4. Summary of rater reliability

Variable	Intra-rater		Inter-rater	
Expert	κ	95% CI	κ	95% CI
	0.92	0.91–0.93	0.85	0.84–0.87
		0.85–0.99*		0.75–0.96*
Student	κ	95% CI	K-α	95% CI
	0.77	0.75–0.78	0.63	0.58–0.67
		0.59–0.95*		0.47–0.79*

κ: Cohen's kappa, CI: confidence interval, K-α: Krippendorff's alpha.
*CIs were calculated without bootstrapping.

RESULTS

Experts and students were reliable in using Y-N to detect scapular dyskinesis in asymptomatic individuals. Table 4 summarizes the reliability results of experts and students. The intra-rater reliability of the experts was near perfect (κ = 0.92), while that of students was substantial (κ = 0.77). The inter-rater reliability of the experts also was nearly perfect (κ = 0.85), and that of the students remained substantial (K-α = 0.63). The prevalence rate of scapular dyskinesis in our sample of 100 subjects as identified by the experts was 59%.

DISCUSSION

The results showed that the Y-N was reliable when used by students or experts in subjects without shoulder pain. Although student reliability was substantial, there was a 20-point difference from experts with near-perfect reliability. This was consistent with similar studies that investigated student reliability compared to that of experts using other clinical tests [16,17,25]. This finding was not surprising as experience may be the most obvious explanation for such a discrepancy. All authors of these studies concluded that experience was the most significant factor that explained the difference.

Our study found that reliability among students was consistently substantial when the Y-N was applied to asymptomatic subjects. This was consistent with the findings of a similar study by Møller, with student κ scores in the range of 0.70–0.90 [12]. Although their research also used PT students as raters, their reliability scores were higher than those of our study. This could be because they used PT students in their final year instead of PT students in their second year. This difference emphasizes the importance of clinical experience.

Our study found that expert reliability was consistently near perfect when the Y-N was applied to asymptomatic subjects. In a previous study by Uhl et al. [11] utilized the Y-N for measuring reliability, the kappa score was only moderate between experts (κ = 0.41). Interestingly, the definition of "expert" in the Uhl et al.'s study [11] was limited to "experienced clinicians." In contrast, we defined experts as those board certified in orthopedic physical therapy and with at least two decades of clinical experience. This indicates that experience remains the most significant defining factor for higher reliability, even among experts. This was the same as the conclusion of Lluch et al. [26] in their comparison of inter-rater reliability among licensed physical therapists with different levels of experience.

Our study prevalence rate of scapular dyskinesis among asymptomatic individuals was 59%. It has been reported that about 60%–70% of individuals suffering shoulder pain have scapular dyskinesis [7-9]. However, many of those studies reported a similar proportion of patients with scapular dyskinesis even among healthy asymptomatic individuals reflective of our study's prevalence result.

The Y-N is very subjective, and there is possibility of an expectation bias because of an expected outcome. This may have influenced the scapular dyskinesis labeling because raters "see what they want to see;" in this case, the presence of scapular dyskinesis.

Most of the experiments took place during the severe acute respiratory syndrome coronavirus 2 (SARS-CoV-2) pandemic [27]. The rating period stretched over 10 weeks at the pandemic height, which may have introduced history and timing biases from subject recruitment to rater performance.

Use of convenience sampling and its associated sampling bias may contribute to the weak generalizability of the results. It is possible that the sample was not representative of the general population due to the nature of volunteer subject enrollment and its associated response bias.

In conclusion, the Y-N is reliable in detecting scapular dyskinesis regardless of experience level when used in an asymptomatic population for screening.

ORCID

Lawrence S. Ramiscal https://orcid.org/0000-0002-0230-277X
Lori A. Bolgla https://orcid.org/0000-0002-4298-4779
Chad E. Cook https://orcid.org/0000-0001-8622-8361
John S. Magel https://orcid.org/0000-0001-9087-4753
Stephen A. Parada https://orcid.org/0000-0002-6304-3038
Raymond Chong https://orcid.org/0000-0002-2706-1300

REFERENCES

1. Neumann DA. Kinesiology of the musculoskeletal system: foundations for rehabilitation. St. Louis, MO: Mosby; 2016.
2. Burkhart SS, Morgan CD, Kibler WB. The disabled throwing shoulder: spectrum of pathology Part III: the SICK scapula, scapular dyskinesis, the kinetic chain, and rehabilitation. Arthroscopy 2003;19:641-61.
3. Kibler WB, Ludewig PM, McClure PW, Michener LA, Bak K, Sciascia AD. Clinical implications of scapular dyskinesis in shoulder injury: the 2013 consensus statement from the 'Scapular Summit'. Br J Sports Med 2013;47:877-85.
4. Roche SJ, Funk L, Sciascia A, Kibler WB. Scapular dyskinesis: the surgeon's perspective. Shoulder Elbow 2015;7:289-97.
5. Timmons MK, Thigpen CA, Seitz AL, Karduna AR, Arnold BL, Michener LA. Scapular kinematics and subacromial-impingement syndrome: a meta-analysis. J Sport Rehabil 2012;21:354-70.
6. Struyf F, Cagnie B, Cools A, et al. Scapulothoracic muscle activity and recruitment timing in patients with shoulder impingement symptoms and glenohumeral instability. J Electromyogr Kinesiol 2014;24:277-84.
7. Burn MB, McCulloch PC, Lintner DM, Liberman SR, Harris JD. Prevalence of scapular dyskinesis in overhead and nonoverhead athletes: a systematic review. Orthop J Sports Med 2016;4:2325967115627608.
8. Plummer HA, Sum JC, Pozzi F, Varghese R, Michener LA. Observational scapular dyskinesis: known-groups validity in patients with and without shoulder pain. J Orthop Sports Phys Ther 2017;47:530-7.
9. Ramiscal L, Bolgla L, Chong R. Scapular muscle activity and pectoralis minor muscle length of asymptomatic scapular dyskinesis: a pilot study [abstract]. J Orthop Sports Phys Ther 2019;50:CSM81-177. Abstract no. OPO184.
10. Hickey D, Solvig V, Cavalheri V, Harrold M, Mckenna L. Scapular dyskinesis increases the risk of future shoulder pain by 43% in asymptomatic athletes: a systematic review and meta-analysis. Br J Sports Med 2018;52:102-10.
11. Uhl TL, Kibler WB, Gecewich B, Tripp BL. Evaluation of clinical assessment methods for scapular dyskinesis. Arthroscopy 2009;25:1240-8.
12. Møller M, Attermann J, Myklebust G, et al. The inter- and intra-rater reliability and agreement for field-based assessment of scapular control, shoulder range of motion, and shoulder isometric strength in elite adolescent athletes. Phys Ther Sport 2018;32:212-20.
13. Lange T, Struyf F, Schmitt J, Lützner J, Kopkow C. The reliability of physical examination tests for the clinical assessment of scapular dyskinesis in subjects with shoulder complaints: a systematic review. Phys Ther Sport 2017;26:64-89.
14. Christiansen DH, Møller AD, Vestergaard JM, Mose S, Maribo T. The scapular dyskinesis test: reliability, agreement, and predictive value in patients with subacromial impingement syndrome. J Hand Ther 2017;30:208-13.
15. Rajasekar S, Bangera RK, Sekaran P. Inter-rater and intra-rater reliability of a movement control test in shoulder. J Bodyw Mov Ther 2017;21:739-42.
16. Maqueda CE, Patel R. Novice versus experienced rater reliability of the Mini Balance Evaluation Systems Test (Mini-BESTest) in patients with acquired brain injury (ABI). J Stud Phys Ther Res 2015;8:92-109.
17. Gulgin H, Hoogenboom B. The functional movement screening (fms)™: an inter-rater reliability study between raters of varied experience. Int J Sports Phys Ther 2014;9:14-20.
18. McClure P, Tate AR, Kareha S, Irwin D, Zlupko E. A clinical method for identifying scapular dyskinesis, part 1: reliability. J Athl Train 2009;44:160-4.
19. Rossi DM, Pedroni CR, Martins J, de Oliveira AS. Intrarater and interrater reliability of three classifications for scapular dyskinesis in athletes. PLoS One 2017;12:e0181518.
20. Hayes AF, Krippendorff K. Answering the call for a standard reliability measure for coding data. Commun Methods Mea 2007;1:77-89.
21. Ramiscal L. Reliability of the scapular dyskinesis test between student and expert physical therapists in asymptomatic scapular dyskinesis: a pilot study [abstract]. J Orthop Sports Phys Ther 2020;51:CSM57-165. Abstract no. CSM166.
22. Cohen J. Statistical power analysis for the behavioral sciences. 2nd ed. London: Routledge; 2013.
23. Krippendorff K. Computing Krippendorff's alpha-reliability [Internet]. Philadelphia, PA: University of Pennsylvania, Annenberg School of Communication; 2011 [cited 2022 Nov 7]. Available from: https://repository.upenn.edu/asc_papers/43.
24. Krippendorff K. Bootstrapping distributions for Krippendorff's alpha [Internet]. Philadelphia, PA: University of Pennsylvania, Annenberg School of Communication; 2016 [cited 2022 Nov 7]. Available from: https://www.asc.upenn.edu/sites/default/files/2021-03/Algorithm%20for%20Bootstrapping%20a%20Distribution%20of%20Alpha.pdf.
25. Kuo KT, Hunter BC, Obayashi M, et al. Novice vs expert inter-rater reliability of the balance error scoring system in children between the ages of 5 and 14. Gait Posture 2021;86:13-6.
26. Lluch E, Benítez J, Dueñas L, et al. The shoulder medial rotation test: an intertester and intratester reliability study in overhead

https://doi.org/10.5397/cise.2022.01109

athletes with chronic shoulder pain. J Manipulative Physiol Ther 2014;37:198-205.

27. World Health Organization. Naming the coronavirus disease (COVID-19) and the virus that causes it [Internet]. Geneva: World Health Organization; 2020 [cited 2021 Mar 15]. Available from: https://www.who.int/emergencies/diseases/novel-coronavirus-2019/technical-guidance/naming-the-coronavirus-disease-(covid-2019)-and-the-virus-that-causes-it#:~:text=Official%20names%20have%20been%20announced,%2DCoV%2D2).

Technical Note

Clin Shoulder Elbow 2022;25(4):328-333
https://doi.org/10.5397/cise.2022.01081

CiSE
Clinics in Shoulder and Elbow

eISSN 2288-8721

Arthroscopic supraspinatus advancement for retracted rotator cuff tears: a technical note

Chris Hyunchul Jo*, Pei Wei Wang*

Department of Orthopedic Surgery, SMG-SNU Boramae Medical Center, Seoul National University College of Medicine, Seoul, Korea

Irreparable rotator cuffs with retracted torn ends remain a significant challenge for most shoulder surgeons. Since repairs are preferable to reconstruction or replacement whenever possible, studies for anatomical reductions with minimal tension and secure fixation are important. In this study, the authors introduce an arthroscopic supraspinatus advancement (ASSA) procedure for retracted rotator cuff tears that could not be adequately reduced to the original footprint. Using modified long, narrow, curved Cobb elevators, procedures can be performed through lateral portals without any additional skin incision. Following meticulous stepwise three-compartment elevation procedures based on the supraspinatus insertion anatomy, the supraspinatus muscle could be safely elevated from the fossa and sufficiently advanced laterally. The authors suggest that ASSA could be a useful procedure for management of challenging retracted rotator cuff tears by maximizing lateral excursions that could convert irreparable tears to reparable tears in select patients.

Keywords: Arthroscopic supraspinatus advancement; Muscle advancement; Irreparable massive rotator cuff; Retracted rotator cuff; Arthroscopy

The surgical goal for rotator cuff repair is to restore the anatomical footprint of the rotator cuff tendon with minimal tension and to maximize the contact area and pressure at the tendon to bone interface [1]. Both quantitative (area and height) and qualitative (presence of the fibrocartilage) regeneration of the tendon to bone interface could produce good long-term clinical results by maintaining the structural integrity of the repaired tendon [2,3]. In order to achieve this, sufficient lateral excursion of the torn rotator cuff is a prerequisite. However, surgeons frequently encounter insufficient excursions in many large to massive tears or in some retracted medium tears. A variety of surgical techniques can be utilized to improve tendon excursion, including articular and bursal side release, margin convergence, anterior and posterior interval slide, and medialization of the greater tuberosity. For irreparable tears with non-reducible torn ends, joint sparing salvage procedures including partial repair, repair with various grafts, superior capsular reconstruction, and tendon transfers or shoulder arthroplasty could be performed. Nevertheless, repair of rotator cuff tendons using the remaining tendon, if possible, should yield better results than reconstructive surgery [4].

Supraspinatus advancement was first reported by Debeyre et al. [5] in which the supraspinatus muscles were elevated from the

Received: July 1, 2022 Revised: August 2, 2022 Accepted: September 18, 2022
Correspondence to: Chris Hyunchul Jo
Department of Orthopedic Surgery, SMG-SNU Boramae Medical Center, Seoul National University College of Medicine, 20 Boramae-ro 5-gil, Dongjak-gu, Seoul 07061, Korea
Tel: +82-2-840-2453, Fax: +82-2-870-3864, E-mail: chrisjo@snu.ac.kr, ORCID: https://orcid.org/0000-0002-6161-5442
*These authors contributed equally to this work.

Financial support: None.
Conflict of interest: None.

supraspinatus fossa and advanced laterally to obtain sufficient excursion of the torn end. Since then, some surgeons have improved the surgical procedure and reported successful clinical and structural outcomes with supraspinatus advancement [4,6-8]. However, there is no report of all-arthroscopic procedures for supraspinatus advancement without any additional skin incision. Therefore, we present our arthroscopic supraspinatus advancement (ASSA) technique for rotator cuff tears with inadequate excursion. A single orthopedic surgeon (CHJ) performed all procedures.

TECHNIQUES

This study was approved by the Institutional Review Board of SMG-SNU Boramae Medical Center (No. 16-2014-5) and the requirement for informed consent was waived due to retrospective nature of this study.

Patient Positioning and Diagnostic Arthroscopy

All arthroscopic surgeries are performed with patients in the lateral decubitus position under general anesthesia as previously described [9]. Briefly, systematic examination of the glenohumeral joint with standard posterior and anteroinferior portals is followed by that of the subacromial space with lateral and posterolateral portals (Fig. 1A and B).

Glenohumeral Joint Release: Superior Capsulotomy and Coracohumeral Ligament Release

Superior capsulotomy is performed from the 10 to 2 o'clock position (Fig. 1C), and articular-sided coracohumeral ligament release occurs from the base of the coracoid process (Fig. 1D). Superior or three-sided release for the subscapularis tendon is performed if necessary. Care is taken not to involve instrumentation more than 2 cm medial to the superior glenoid margin, especially in the 10 or 2 o'clock position to avoid injury of the suprascapular nerve.

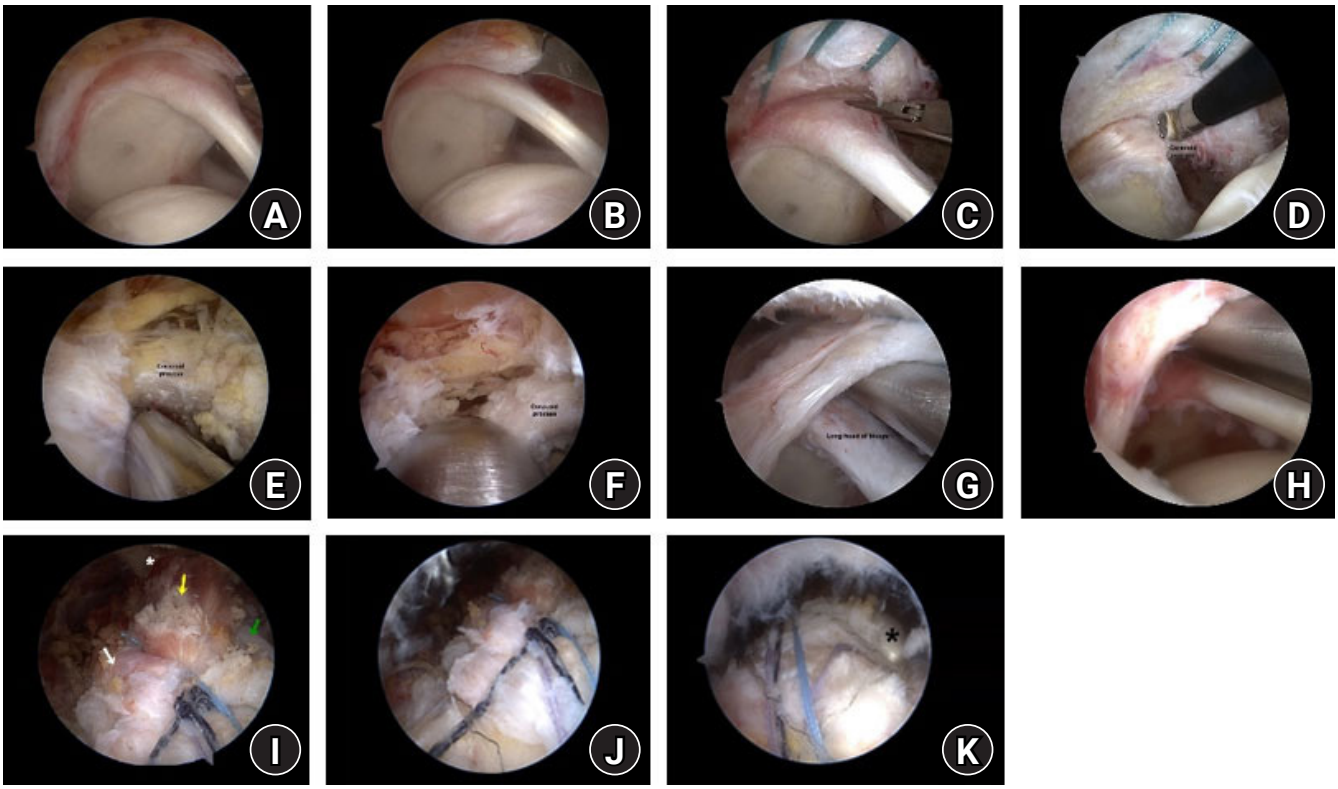

Fig. 1. Procedures of arthroscopic supraspinatus advancement. (A) A massive retracted rotator cuff with a torn end at the glenoid level. (B) Insufficient lateral excursion of the torn end. (C) Superior capsulotomy is performed from the 10 to 2 o'clock position using straight arthroscopic scissors. (D) Articular-sided coracohumeral ligament release using the electrical ablator. (E) Bursal-sided coracohumeral ligament release using the shaver. (F) Using the base of the coracoid process as a jig, the Cobb elevator is introduced for anterior compartment elevation. (G) Using the superior glenoid margin as a jig, the Cobb elevator is introduced for middle compartment elevation. (H) The Cobb elevator is directed more posteriorly for posterior compartment elevation. (I) The arthroscopic view of the repaired rotator cuff tendon with arthroscopic supraspinatus advancement from the lateral portal. The tear gap was nearly invisible. Asterisk: scapular spine, yellow arrow: supraspinatus, white arrow: infraspinatus, green arrow: biceps long head tendon. (J) The posterior aspect of the repaired tendon. (K) The anterior aspect of the repaired tendon. Asterisk: biceps long head tendon secured by *in situ* tenodesis.

Subacromial Space Release: Superior Release and Coracohumeral Ligament Release in Continuity

Bursal tissues and adhesions overlying the supraspinatus or infraspinatus and those around the coracoid process and scapular spine are removed (Fig. 1E). Identification and release of the suprascapular artery and nerve around the suprascapular notch are performed if necessary. After release, lateral excursion of the torn end is re-evaluated to determine the need for ASSA.

Anterior Compartment Elevation of the Supraspinatus in the Supraspinatus Fossa

Three sutures are threaded into the torn end for traction. The insertion anatomy of the supraspinatus muscle consists of larger anterior (A) and smaller posterior parts (P), each of which is further subdivided into superficial (S), middle (M), and deep parts (D) [10]. For meticulous elevation of each muscle origin, we developed the three-compartment elevation procedure with anterior, middle, and posterior sections. For anterior compartment elevation, the traction sutures are pulled out through the posterior portal to secure clear vision around the base of the coracoid process and the suprascapular notch. Using the base of the coracoid process as a jig (Fig. 2A), a specially modified, long, narrow, and right-curved Cobb elevator for the right shoulder is inserted through the lateral portal and placed at the entrance of the supraspinatus fossa located just medial to the supraspinatus notch (Fig. 1F).

The Cobb elevator is then slid medially along the fossa to elevate the anterior portion of the AM attached to the medial two-thirds and the AD attached to the lateral one-third of the supraspinous fossa and along the anteromedial border of the fossa for elevation of AS. The Cobb elevator must be moved slowly and carefully around the suprascapular notch so as not to injure the suprascapular nerve. Using the surgeon's other hand, one can estimate the location of the Cobb elevator tip along the medial border of the scapula. Complete elevation from the fossa is required to achieve larger excursions, especially from the medial border of the scapula.

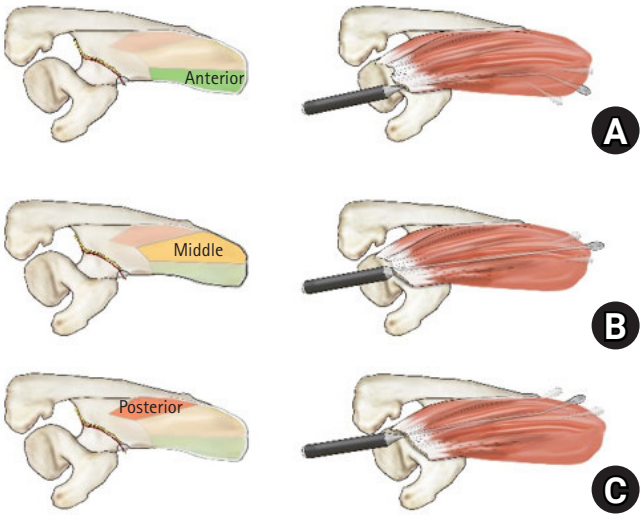

Fig. 2. Schematic illustration of the supraspinatus insertion anatomy and the three-compartment elevation. (A) Anterior compartment elevation. The anterior compartment consists of (1) the anterior portion of the anterior middle part (AM) attached to the medial two-thirds of the supraspinous fossa, (2) the anterior-deep (AD) attached to the lateral one-third of the supraspinous fossa, and (3) the anterior-superficial (AS) along the anteromedial border of the fossa. A modified, long, narrow, right-curved Cobb elevator for the right shoulder would be useful for anterior elevation. (B) Middle compartment elevation. The middle compartment consists of (1) the entire supraspinatus fossa for the elevation of the middle portion of the AM attached to the medial two-thirds and (2) the AD attached to the lateral one-third and posterior-deep attached to the base of the supraspinatus fossa. A modified, long, narrow, downward curved Cobb elevator would be useful for middle compartment elevation. (C) Posterior compartment elevation. The posterior compartment consists of (1) the posterior portion of the AS that is attached to the medial one-third of the superior border of the scapular spine and (2) the posterior-superficial and posterior-middle that are both attached to the posterior wall of the supraspinatus. A modified, long, narrow, left-curved Cobb elevator for the right shoulder would be useful for posterior compartment elevation.

Middle Compartment Elevation of the Supraspinatus in the Supraspinatus Fossa

The traction sutures are pulled out through the accessory lateral portal just lateral to the acromion. A modified, long, narrow, downward curved Cobb elevator is introduced through the lateral portal and passed between the torn tendon and superior labrum. Using the superior glenoid margin as a jig (Fig. 2B), it is placed on the entrance of the supraspinatus fossa (Fig. 1G). The Cobb elevator is then slid medially along the entire supraspinatus fossa to elevate the middle portion of the AM attached to the medial two-thirds, the AD attached to the lateral one-third, and the PD attached to the base of the supraspinatus fossa.

Posterior Compartment Elevation of the Supraspinatus in the Supraspinatus Fossa

A modified, long, narrow, left-curved Cobb elevator for the right shoulder is introduced through the lateral portal between the tendon and the labrum but more posteriorly directed compared to middle elevation (Fig. 2C). Posterior compartment elevation involves the posterior portion of the AS that is attached to the medial one-third of the superior border of the scapular spine, as well as the PS and PM that are both attached to the posterior wall of the supraspinatus (Fig. 1H). Lateral excursion is verified after each elevation procedure and repeated as needed. A lateral ex-

https://doi.org/10.5397/cise.2022.01081

cursion of approximately 4 to 5 cm should be obtained using the three-compartment elevation procedure.

Footprint Preparation and Rotator Cuff Repair

The footprint of the greater tuberosity is debrided, and only a minimal layer of calcified fibrocartilage is removed. Multiple channeling for enhancement of healing is performed if indicated [11]. Rotator cuff repair is performed to maximally cover the original footprint (Fig. 1I-K).

Postoperative Protocol and Exercises

The patients are instructed to undergo postoperative magnetic resonance imaging within 3 days following surgery (Fig. 3). The shoulder is immobilized for 6 weeks using an abduction brace. Shrugging, protraction, and retraction of the shoulder girdles; intermittent exercises of the elbow, wrist, and hand; and external rotation of the arm to neutral with the brace are encouraged as tolerated, typically starting immediately after surgery. Further passive range of motion (ROM) and active assisted ROM exercises are allowed after the patient is gradually weaned off the abduction brace 6 weeks after surgery. Patients begin strengthening exercises after 3 months. Light sports activities, such as jogging, are allowed after 3 months, and a full return to sports is allowed after 6 to 9 months based on individual recovery.

DISCUSSION

Debeyre et al. [5] first proposed that the supraspinatus can be advanced laterally by elevating the entire muscle from its fossa. However, this procedure required a large skin incision, acromion osteotomy, and a deltoid split, all of which may result in significant complications. The surgical procedure has been modified to avoid acromion osteotomy [12], to maintain the deep fasciae between the levator scapulae and the supraspinatus and between the rhomboids and the infraspinatus [6], and to convert the procedure from open to arthroscopic-assisted surgery with 4 cm [7] and 2 cm incisions around the medial scapular spine [8]. However, all of these surgeries require an additional skin incision or portal around the medial scapular border, with need for wider and fastidious skin preparation. Furthermore, with a small 2 cm portal, it would be difficult to pass through the trapezius without additional damage to this thin muscle and to precisely locate the supraspinatus and infraspinatus for elevation. Therefore, we introduce ASSA as the first all-arthroscopic procedure for rotator cuff muscle advancement. Using modified, long, narrow, curved Cobb elevators, all of the muscle elevation procedures can be performed through lateral portals without any additional incisions. Through the stepwise three-compartment elevation procedure based on supraspinatus anatomy, surgeons could safely elevate the supraspinatus muscle from the fossa and sufficiently advance it laterally as necessary. With ASSA, we consistently gained 4 to 5 cm of additional lateral excursion. We believe that ASSA could ensure maximal restoration of the anatomical footprint of the rotator cuff tendon while maintaining minimal tension to optimize the healing process and result in robust structural integrity. In addition, arthroscopic infraspinatus advancement (AISA) or arthroscopic subscapularis advancement (ASCA) can also be achieved using the surgical procedures and instruments used in ASSA. Since torn infraspinatus tendons are much more mobile than torn supraspinatus tendons, they can typically be re-

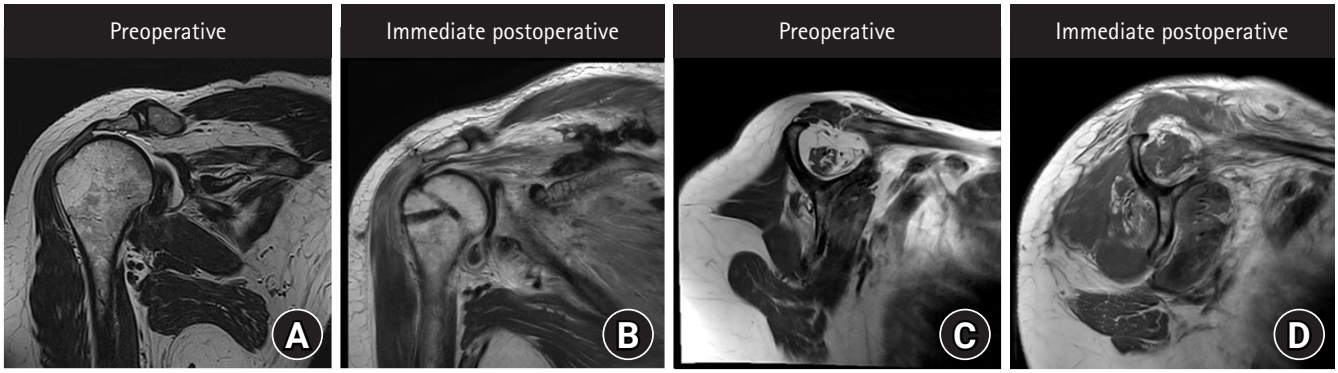

Fig. 3. Preoperative and immediate postoperative magnetic resonance imaging of a massive rotator cuff tear repaired with arthroscopic supraspinatus advancement. (A) Preoperative T2-weighted coronal image showing a massive rotator cuff tear retracted at the glenoid level. (B) Postoperative T2-weighted coronal image showing the repaired tendon restored to the anatomical footprint. (C) Severe fatty infiltration and muscle atrophy are observed in the T1-weighted sagittal image. The Goutallier grade was 4 for the supraspinatus, 4 for the infraspinatus, and 2 for the subscapularis. The tangent sign was positive, and the occupational ratio was grade 3 (28%). (D) Improved fatty infiltration and muscle atrophy due to lateral excursion of the supraspinatus and infraspinatus muscles. The Goutallier grades were 2, 2, and 2, respectively. The tangent sign was negative, and the occupational ratio was grade 1 (72%).

placed more easily. Nevertheless, AISA is performed when further advancement of the infraspinatus is required. During the AISA procedure, the lateral portal serves as the viewing portal, while the Cobb elevator is inserted through the posterolateral portal. An additional accessory portal can be created posterior to the posterolateral portal in order to accommodate the Cobb elevator. Using the scapular spine as a reference for dividing the supraspinatus and infraspinatus muscle bellies, the Cobb elevator is advanced under the infraspinatus muscle to create detachment from the bone. During the ASCA procedure, the lateral portal serves as the viewing portal, while the Cobb elevator is inserted through the additional anterosuperolateral portal. The Cobb elevator is advanced under the subscapularis muscle to create detachment from the bone.

Originally, supraspinatus muscle advancement included fascial detachment from the medial scapular border and spine [5,12]. Later, Kurokawa and Hirasawa [6] introduced a modified procedure that maintained the fascial connection between the rotator cuff muscles and the rhomboids. Currently, some surgeons retain the fascial connection [7], while some other surgeons do not [4]. However, the clinical importance of maintenance of the fascial connection remains unclear as both groups report satisfactory clinical and structural outcomes. Practically, it would be difficult to maintain the fascial connection as elevators are only introduced through lateral portals, and the tense fascial connection due to arm traction would be more prone to splitting than detachment from the medial border of the scapula. Meanwhile, lateral excursion will increase in the absence of any soft tissue restraints to the supraspinatus muscle. In our experience, division of the fascial connection and complete elevation of the supraspinatus increased lateral excursion by at least an additional 1 or 2 cm. Therefore, dividing fascial connections and completely elevating the supraspinatus in ASSA would be viable options in some cases.

As opposed to open supraspinatus muscle advancement that was performed without suprascapular nerve release [5,12], most arthroscopic-assisted surgeries were reported to be performed with release [4,7,8]. Several studies described concerns of suprascapular nerve injury in massive rotator cuff tears [13] and in repair surgeries with large lateral advancements [14]. However, there have been no reported cases of suprascapular nerve injuries in supraspinatus muscle advancements with or without nerve release. In our experiences with ASSA, we also have not experienced nerve injury regardless of release. Therefore, we do not believe that suprascapular nerve release is obligatory for ASSA.

Repairs are always preferable to reconstruction or replacement when possible since the former is more anatomic, biologic, and enduring [4]. In that sense, we suggest ASSA as a useful surgical technique for managing challenging retracted rotator cuff tears with inadequate lateral excursion to aim to convert irreparable tears to reparable tears in selected patients.

ORCID

Chris Hyunchul Jo https://orcid.org/0000-0002-6161-5442
Pei Wei Wang https://orcid.org/0000-0003-4723-4368

REFERENCES

1. Park MC, ElAttrache NS, Tibone JE, Ahmad CS, Jun BJ, Lee TQ. Part I: footprint contact characteristics for a transosseous-equivalent rotator cuff repair technique compared with a double-row repair technique. J Shoulder Elbow Surg 2007;16:461-8.
2. Apreleva M, Ozbaydar M, Fitzgibbons PG, Warner JJ. Rotator cuff tears: the effect of the reconstruction method on three-dimensional repair site area. Arthroscopy 2002;18:519-26.
3. Vastamäki M, Lohman M, Borgmästars N. Rotator cuff integrity correlates with clinical and functional results at a minimum 16 years after open repair. Clin Orthop Relat Res 2013;471:554-61.
4. Yokoya S, Nakamura Y, Harada Y, Ochi M, Adachi N. Outcomes of arthroscopic rotator cuff repair with muscle advancement for massive rotator cuff tears. J Shoulder Elbow Surg 2019;28:445-52.
5. Debeyre J, Patie D, Elmelik E. Repair of ruptures of the rotator cuff of the shoulder. J Bone Joint Surg Br 1965;47:36-42.
6. Kurokawa M, Hirasawa Y. Clinical study of modified Debeyre's operation for massive tear of rotator cuff. J Shoulder Elbow Surg 1995;4 Suppl 1:S69.
7. Morihara T, Kida Y, Furukawa R, et al. Therapeutic outcomes of muscular advancement by an arthroscopic-assisted modified Debeyre-Patte procedure for irreparable large and massive rotator cuff tears. J Orthop Sci 2018;23:495-503.
8. Gupta A, Ker AM, Maharaj JC, Veen EJ, Cutbush K. All-arthroscopic muscle slide and advancement technique to repair massive retracted posterosuperior rotator cuff tears. Arthrosc Tech 2021;10:e1439-46.
9. Jo CH, Shin JS, Shin WH, Lee SY, Yoon KS, Shin S. Platelet-rich plasma for arthroscopic repair of medium to large rotator cuff tears: a randomized controlled trial. Am J Sports Med 2015;43:2102-10.
10. Kim SY, Boynton EL, Ravichandiran K, Fung LY, Bleakney R,

 https://doi.org/10.5397/cise.2022.01081

Agur AM. Three-dimensional study of the musculotendinous architecture of supraspinatus and its functional correlations. Clin Anat 2007;20:648-55.
11. Jo CH, Shin JS, Park IW, Kim H, Lee SY. Multiple channeling improves the structural integrity of rotator cuff repair. Am J Sports Med 2013;41:2650-7.
12. Ha'Eri GB, Wiley AM. "Supraspinatus slide" for rotator cuff repair. Int Orthop 1980;4:231-4.
13. Warner JP, Krushell RJ, Masquelet A, Gerber C. Anatomy and relationships of the suprascapular nerve: anatomical constraints to mobilization of the supraspinatus and infraspinatus muscles in the management of massive rotator-cuff tears. J Bone Joint Surg Am 1992;74:36-45.
14. Greiner A, Golser K, Wambacher M, Kralinger F, Sperner G. The course of the suprascapular nerve in the supraspinatus fossa and its vulnerability in muscle advancement. J Shoulder Elbow Surg 2003;12:256-9.

Case Report

Clin Shoulder Elbow 2022;25(4):334-338
https://doi.org/10.5397/cise.2021.00514

CiSE
Clinics in Shoulder and Elbow

eISSN 2288-8721

Delayed surgical repair of the deltoid following acromioplasty: a case report

Zohaib Sherwani[1], Chase Kelley[2], Hassan Farooq[3], Nickolas G. Garbis[3]

[1]*Stritch School of Medicine, Loyola University, Maywood, IL, USA*
[2]*Midwestern University Chicago College of Osteopathic Medicine, Downers Grove, IL, USA*
[3]*Department of Orthopaedic Surgery and Rehabilitation, Loyola University Health System, Maywood, IL, USA*

Currently, the literature contains few studies that describe any potential complications following arthroscopic acromioplasty. Because part of the anterior deltoid originates from the anterior acromion, there is a risk for violation and subsequent iatrogenic rupture or avulsion during this procedure. This type of injury can be a devastating problem for patients that may lead to poor function and debilitating pain. We present a patient with deltoid insufficiency following arthroscopic acromioplasty who elected to proceed with operative management with a planned arthroscopic evaluation of the shoulder followed by an open deltoid repair. At the final follow-up visit 2.5 years postoperatively, the patient reported improved pain from baseline and no residual disability and was able to perform most activities of daily living without difficulty. This case serves as an example of a surgical repair for a deltoid avulsion following arthroscopic acromioplasty. As there is still a lack of standard guidelines, our suture repair technique can be considered one method of treatment for this type of injury.

Keywords: Deltoid muscle; Arthroscopy; Postoperative complications; Reoperation

The deltoid muscle is divided into anterior, middle, and posterior components. While the loss of strength generated by the posterior deltoid may be compensated by other muscles (such as the latissimus dorsi), the loss of the anterior deltoid can be debilitating for patients as it is responsible for approximately 50% of the strength involved in elevating the arm within the scapular plane [1].

Subacromial impingement or rotator cuff tendinopathy is a common cause of shoulder pain and accounts for 44%–65% of shoulder pathology [2]. Patients often report pronounced pain that is exacerbated by motions commonly utilized for many activities of daily living (ADL). In 1972, Neer [3] first described the open anterior acromioplasty technique for patients with shoulder impingement; this procedure was later extended by Rockwood and Lyons [4], who recommended further resection beyond the anterior edge of the clavicle to account for any residual anterior impingement. Importantly, both studies highlighted the significance of restoring the integrity of the deltoid muscle to the acromion, especially in regards to the anterior component [3,4].

The rates of acromioplasties being performed are increasing yearly. One study reviewed the number of acromioplasties that took place over a 10-year-period from 1996 to 2006 and observed a three-fold increase with only a 75% increase in all other orthopedic procedures [5]. There is limited orthopedic literature that

Received: September 24, 2021 Revised: February 11, 2022 Accepted: February 21, 2022
Correspondence to: Hassan Farooq
Department of Orthopedic Surgery and Rehabilitation, Loyola University Health System, 2160 S 1st Ave, Maywood, IL 60153, USA
Tel: +1-708-216-3876, Fax: +1-708-216-5858, E-mail: hassan.farooq@luhs.org

Financial support: None.
Conflict of interest: None.

currently describes the potential complications that can arise following acromioplasty. With 25% of the anterior deltoid originating from the anterior acromion, there is a potential risk for violation of the anterior deltoid and subsequent iatrogenic rupture or avulsion [6-8]. This injury can be a devastating problem for patients and may lead to pain and decreased function. We present a patient found to have deltoid insufficiency following acromioplasty who was treated with open surgical repair and clinically followed-up over 2.5 years postoperatively.

CASE REPORT

Initial Evaluation

The patient was a 38-year-old, right-hand-dominant male who reported 1 year of persistent left shoulder pain. He was referred for further management following arthroscopic debridement, biceps tenotomy, and acromioplasty 6 months ago. His prior management included a single cortisone injection. The patient's initial history revealed progressive shoulder pain rated as an eight out of 10 that "wakes the patient from sleep." Furthermore, the patient reported pain, loss of strength, and notable weakness with abduction. This patient's initial American Shoulder and Elbow Surgeons (ASES) shoulder score was 5.

Upon initial physical examination, pertinent positive findings included tenderness to palpation of the left anterior acromion with obvious soft tissue deficiency around the deltoid. The range of motion was notable for active elevation to 130° and active external rotation to 40° on the left, compared to active elevation of 160° and active external rotation to 70° on the right. Anterior deltoid and rotator cuff strength were noted to be 4/5 with painful impingement maneuvers and restricted motion with true abduction. The patient's strength was 5/5 and was without limitation for the contralateral upper extremity. All other available imaging, including plain radiographs (Fig. 1) and magnetic resonance imaging (Fig. 2), was reviewed and was consistent with a resected acromion, avulsion of parts of the anterior and middle head of the deltoid, and subacromial bursal fluid.

Operative Management: Arthroscopic

Treatment options were discussed with the patient, and he elected to proceed with operative management with a planned arthroscopic evaluation of the shoulder followed by open deltoid repair. An interscalene block was utilized for regional analgesia, and the patient was brought into a beach chair position after the induction of general anesthesia. An initial diagnostic evaluation of the glenohumeral joint was completed through a conventional posterior portal (Fig. 3) to rule out any potential rotator cuff pathology and arthrofibrosis intraarticularly that would not be as easily assessable through an open approach. The glenohumeral surfaces were noted to be intact with minimal chondromalacia,

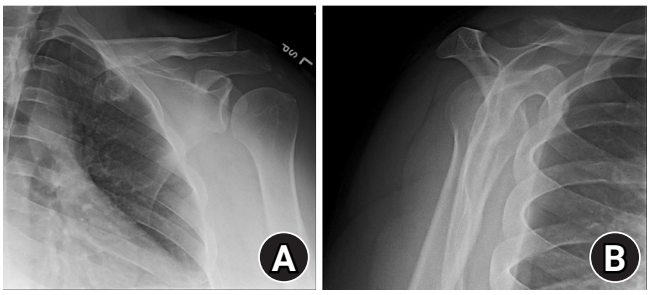

Fig. 1. Grashey view (A) and scapular Y view (B) depicting the left shoulder following arthroscopic acromioplasty at the patient's initial presentation for treatment.

Fig. 2. (A-C) Magnetic resonance imaging of different sections depicting avulsed anterior and middle heads of the deltoid muscle following arthroscopic acromioplasty.

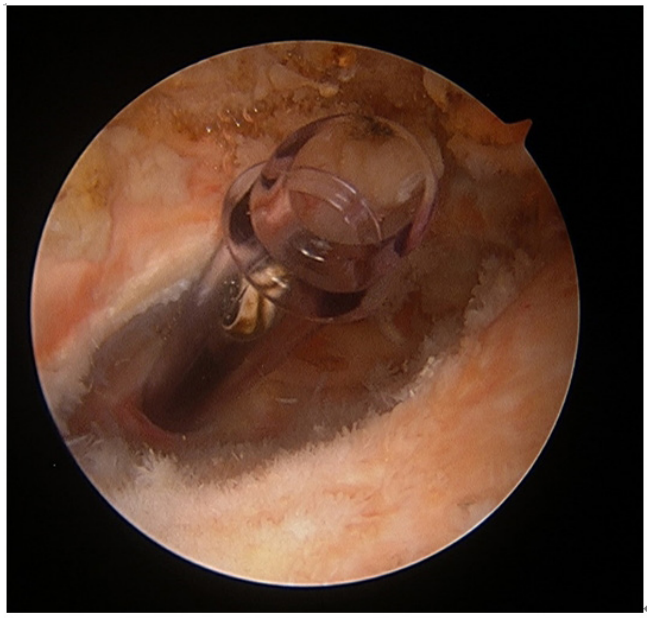

Fig. 3. An arthroscopic view of the glenohumeral space upon access via a conventional posterior portal.

Fig. 4. Repair sutures were passed through in a modified Mason-Allen fashion.

Fig. 5. An appropriate approximation of the deltoid to the bony surface was achieved.

some evidence of labral fraying, and a surgically absent biceps tendon. An anterior portal was used to debride the synovium and frayed superior labrum. The articular surfaces of the supraspinatus, infraspinatus, and subscapularis were intact. Next, the subacromial space was evaluated, and significant debris was debrided. There was fraying of the rotator cuff, but no focal areas necessitated repair. A 4.5-cm deltoid defect was identified arthroscopically. An ablation device was used to clear the undersurface of the acromion, allowing for identification of the anterior edge. At this juncture, the arthroscopic debridement was completed, and then attention was turned to the open repair.

Operative Management: Open

An incision was made over the area of the deltoid defect. The skin and subcutaneous tissue were divided to the level of the deltoid fascia. All fibrous tissue that did not appear normal was resected, exposing the deltoid defect at the anterior portion of the previously resected acromion and at the medial portion of the clavicle. The end of the clavicle and the remainder of the acromion were decorticated. Eight drill holes were made through the acromion and clavicle, and #2 Ethibond sutures (Ethicon, Cincinnati, OH, USA) were passed through these holes. The anterior deltoid was mobilized, and the sutures were passed through in a modified Mason-Allen fashion (Fig. 4). The sutures provided good approximation of the deltoid to the bony surfaces (Fig. 5). Fig. 6 shows a step-by-step schematic drawing that is provided for visual representation of this repair technique. We used 0 Vicryl (Ethicon) to further secure the deltoid trapezial fascia. The wound was thoroughly irrigated, and the skin was closed with 2-0 Vicryl and 4-0 Monocryl (Ethicon).

Hospital Course and Follow-up

In the immediate postoperative period, the patient was instructed to avoid all active range of motion activities, maintain the use of an abduction brace, and perform pendulum exercises. Postoperatively, the patient began formal physical therapy at 4 weeks and was granted an unrestricted active range of motion at 6 weeks.

The treating fellowship-trained shoulder and elbow surgeon assessed the patient's pain level through the visual analog scale as well as his functional and strength status using the ASES shoul-

https://doi.org/10.5397/cise.2021.00514

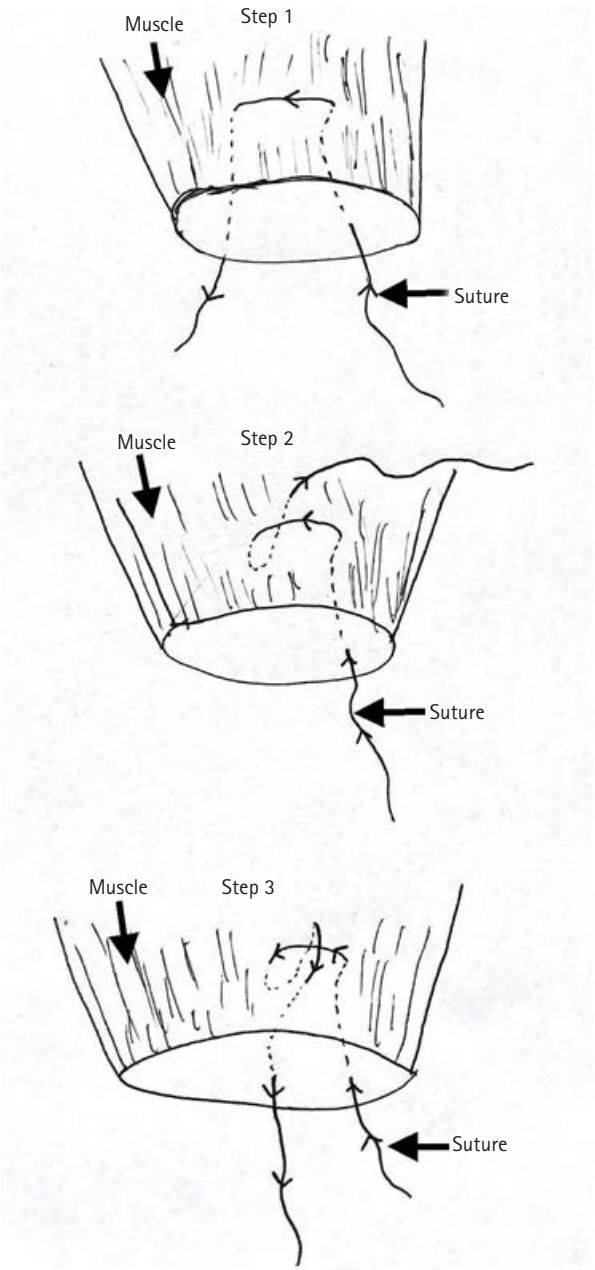

Fig. 6. A schematic drawing of the steps involved in an open deltoid repair.

der score at routine postoperative clinic visits. In addition, a thorough history and physical exam were conducted at each postoperative follow-up visit. At 3 months postoperatively, the patient's range of motion was measured to an active elevation and external rotation of 176° (△ +46°) and 75° (△ +35°), respectively. However, the patient's strength remained unchanged from the initial preoperative assessment. At the final follow-up appointment 2.5 years postoperatively, the patient reported minimal to no pain at baseline and exacerbated 6/10 pain with certain activities, such as sleeping on the affected side. Further, he reported minimal to no restriction in his range of motion and had experienced significant improvement from baseline in his strength and ability to perform necessary ADLs. The final ASES shoulder score was 61 (△ +56).

DISCUSSION

The deltoid muscle plays an important role in motion that occurs near the glenohumeral joint. Although it shares its origins with the clavicle, acromion, and scapular spine, the superior surface of the acromion is the primary origin for the anterolateral or middle head of the deltoid. Deltoid rupture can lead to progressive pain and loss of function in patients' ADLs. Frequently, patients will fail non-operative management, which can include nonsteroidal anti-inflammatories, narcotic medications, and aggressive physical therapy. In such a case, there is a strong indication for operative intervention [1].

We have presented the case of a patient who reported a restricted range of motion and progressive shoulder pain for the past 1 year. Advanced imaging revealed an avulsed middle head of the deltoid 6 months status post-arthroscopic acromioplasty. Our review of the literature yielded multiple cases that described deltoid repairs following open procedures. For example, Gumina et al. [7] reported deltoid repairs in two patients following open rotator cuff repair, with each occurring within 1 month of the diagnosis of deltoid rupture.

Although several reports in the literature have recognized the risk of deltoid avulsion following open acromioplasty, the data associated with an arthroscopic approach have been limited due to this condition's infrequent occurrence [4,9]. Bonsell [10] reported one case of deltoid rupture following arthroscopic subacromial decompression. Rupture was hypothesized to have occurred secondary to over-resection of the acromion, which weakened the origin of the deltoid. Another association with rupture of the deltoid was noted by Yamaguchi et al. [8], who cited the frequent use of steroid injections as a contributing factor for spontaneous deltoid rupture. Factors that likely contributed to deltoid rupture in this case included our patient's previous cortisone injection along with his history of aggressive acromial resection.

The patient in this study was found to have a significant deltoid defect upon arthroscopic evaluation. The size of the defect was postulated to have a direct effect on the level of pain and the functional deficits that were observed at this patient's initial evaluation. The repair of our patient's deltoid was uncomplicated and was performed with primary suture anchors to the acromion and clavicle. With an extensive physical therapy protocol, our patient

experienced improvement in active elevation and also in active external rotation. After 2.5 years, the patient reported minimal to no pain with most of his ADLs and significant improvement from his baseline pain score (8/10). Despite still reporting periodic pain during sleep, the patient was overtly satisfied with his surgical outcome.

Our study was limited in that the index arthroscopic acromioplasty was done at an outside institution and by a different surgeon than the one who treated the patient's deltoid insufficiency. Consequently, there was limited access to this patient's prior surgical information, including the technique used for acromioplasty, the initial treating surgeon's level of expertise, and any existing concomitant pathologies that may have been located near the anterior acromion.

This case is an example of a successful surgical repair of deltoid avulsion following arthroscopic acromioplasty. Extensive research demonstrates the importance of the deltoid and the necessity for its repair following detachment. The insufficient number of reported cases explain the current lack of standard guidelines for this type of injury. Furthermore, unlike in open acromioplasty, where there can be visual confirmation regarding the integrity of the deltoid, the arthroscopic approach has a higher chance of undetected deltoid insufficiency. In these cases, our suture repair technique should be considered to treat iatrogenic deltoid rupture.

REFERENCES

1. Elzanie A, Varacallo M. Anatomy, shoulder and upper limb, deltoid muscle. Treasure Island, FL: StatPearls Publishing; 2022.
2. Harrison AK, Flatow EL. Subacromial impingement syndrome. J Am Acad Orthop Surg 2011;19:701-8.
3. Neer CS 2nd. Anterior acromioplasty for the chronic impingement syndrome in the shoulder: a preliminary report. J Bone Joint Surg Am 1972;54:41-50.
4. Rockwood CA, Lyons FR. Shoulder impingement syndrome: diagnosis, radiographic evaluation, and treatment with a modified Neer acromioplasty. J Bone Joint Surg Am 1993;75:409-24.
5. Vitale MA, Arons RR, Hurwitz S, Ahmad CS, Levine WN. The rising incidence of acromioplasty. J Bone Joint Surg Am 2010; 92:1842-50.
6. Cho NS, Cha SW, Rhee YG. Alterations of the deltoid muscle after open versus arthroscopic rotator cuff repair. Am J Sports Med 2015;43:2927-34.
7. Gumina S, Di Giorgio G, Perugia D, Postacchini F. Deltoid detachment consequent to open surgical repair of massive rotator cuff tears. Int Orthop 2008;32:81-4.
8. Yamaguchi K, Ito N, Eto M, Iwasaki K, Akeshima N. Rupture of the deltoid muscle belly with tear of the rotator cuff: a case report. Orthop Traumatol 1993;42:1663-6.
9. Gartsman GM. Arthroscopic acromioplasty for lesions of the rotator cuff. J Bone Joint Surg Am 1990;72:169-80.
10. Bonsell S. Detached deltoid during arthroscopic subacromial decompression. Arthroscopy 2000;16:745-8.

https://doi.org/10.5397/cise.2021.00514

Concise Review

Clin Shoulder Elbow 2022;25(4):339-346
https://doi.org/10.5397/cise.2022.01263

CiSE
Clinics in Shoulder and Elbow

eISSN 2288-8721

Regional nerve blocks for relieving postoperative pain in arthroscopic rotator cuff repair

Tae-Yeong Kim[1], Jung-Taek Hwang[2]

[1]*Department of Orthopedic Surgery, Korea University Anam Hospital, Korea University College of Medicine, Seoul, Korea*
[2]*Department of Orthopedic Surgery, Chuncheon Sacred Heart Hospital, Hallym University Medical College, Chuncheon, Korea*

Rotator cuff tear is the most common cause of shoulder pain in middle-age and older people. Arthroscopic rotator cuff repair (ARCR) is the most common treatment method for rotator cuff tear. Early postoperative pain after ARCR is the primary concern for surgeons and patients and can affect postoperative rehabilitation, satisfaction, recovery, and hospital day. There are numerous methods for controlling postoperative pain including patient-controlled analgesia, opioid, interscalene block, and local anesthesia. Regional blocks including interscalene nerve block, suprascapular nerve block, and axillary nerve block have been successfully and commonly used. There is no difference between interscalene brachial plexus block (ISB) and suprascapular nerve block (SSNB) in pain control and opioid consumption. However, SSNB has fewer complications and can be more easily applied than ISB. Combination of axillary nerve block with SSNB has a stronger analgesic effect than SSNB alone. These regional blocks can be helpful for postoperative pain control within 48 hours after ARCR surgery.

Keywords: Arthroscopic rotator cuff repair; Interscalene nerve block; Suprascapular nerve block; Axillary nerve block; Regional block

INTRODUCTION

Patients with shoulder problems are commonly encountered in the medical field. Among them, rotator cuff tear is the most common cause in patients of middle age and older. [1]. A rotator cuff tear causes significant pain and dysfunction of the shoulder and should be treated properly [2]. In the United States, over 250,000 rotator cuff repairs are performed annually, and arthroscopic repairs have increased in frequency [3]. Arthroscopic rotator cuff repair (ARCR) can be performed in inpatient or outpatient settings, but there is concern about postoperative pain in the early period [4]. Generally, an arthroscopic procedure induces less postoperative pain than an open procedure. Warrender et al. [5] found that arthroscopic repair resulted in significantly decreased postoperative pain and better functional outcomes. Stiglitz et al. [6] showed that postoperative pain after arthroscopy peaked at postoperative day 1. Early postoperative pain after arthroscopic shoulder surgery is a major source of concern for patients and surgeons [7]. Some studies reported that severe postoperative pain was observed in the first 48 hours after rotator cuff repair [8]. Early proper management of postoperative pain is important for better outcomes and can reduce costs and the hospitalization period as well as aid in recovery, including rehabilitation and nourishment [4].

Postoperative pain can be the result of not only direct destruction of tissue, including skin, synovium, capsule, and bone, but

Received: September 25, 2022 Accepted: October 27, 2022
Correspondence to: Jung-Taek Hwang
Department of Orthopedic Surgery, Chuncheon Sacred Heart Hospital, Hallym University Medical College, 77 Sakju-ro, Chuncheon 24253, Korea
Tel: +82-33-240-5197, Fax: +82-33-252-0177, E-mail: drakehjt@hanmail.net, ORCID: https://orcid.org/0000-0003-4189-084X

Financial support: None.
Conflict of interest: None.

also stimulation of pain receptors. During an operation, tissue trauma with direct peripheral nerve injury can induce inflammation. This inflammation can result in over-sensitization of pain receptors, increasing the importance of early postoperative pain relief [9]. There are many methods for controlling postoperative pain, including patient-controlled analgesia (PCA), opioids, interscalene block, and peripheral nerve block [10]. PCA and opioids have a systemic effect and might not control pain adequately because of side effects like nausea, vomiting, and sedation. The interscalene block is commonly used and effective for shoulder arthroscopy [11]. This type of block has a strong effect on analgesia, but there are side effects like rebound pain in 5%–10% of cases [12]. As the interscalene block also can affect the phrenic nerve, it can lead to pulmonary problems like respiratory distress or diaphragmatic paresis [13]. Recently, the peripheral nerve block, like the suprascapular nerve block (SSNB) and axillary nerve block (ANB), has been utilized and has worked relatively well at controlling pain. There have also been studies that analyzed the effects of regional blocks (Table 1). Among these studies, randomized controlled trials are described in Table 2 [14-24]. In this review, we analyzed the effect of interscalene brachial plexus block (ISB), SSNB, and ANB.

ANATOMY OF SHOULDER SENSORY NERVE

The posterior cord for the brachial plexus innervates the glenohumeral joint, and there are three peripheral nerves that innervate the capsule: the suprascapular nerve, axillary nerve, and lateral pectoral nerve [25]. Some studies have shown that these nerves have articular branches [26,27].

REGIONAL BLOCKS

Interscalene Brachial Plexus Block

The ISB has been increasing in shoulder arthroscopic surgery because it effectively reduces postoperative pain and use of opioids [5]. The ISB can be applied as a single bolus blockade or a continuous infusion using an indwelling catheter [28]. A single bolus ISB can provide 8 hours of analgesic effect after an operation, and a continuous infusion reduces pain for up to 2 days postoperative [29,30]. The ISB induces less oxidative stress during surgery and can be helpful for perioperative hemodynamic stability [31]. Salviz et al. [20] compared outpatient ARCR patients given a single bolus ISB, a continuous infusion ISB, or general anesthesia. Patients with continuous infusion ISB had less pain and used fewer narcotics than others. Abdallah et al. [29] analyzed 23 randomized controlled trials including 1,090 patients and concluded that single-bolus ISB could provide effective analgesia 8 hours after shoulder surgery. However, after 24 hours, some patients reported rebound pain and showed no difference in pain compared to patients who did not receive the ISB. Kim et al. [32] analyzed 117 patients who underwent ARCR and divided them into three groups (single bolus, continuous infusion, and general anesthesia). They demonstrated that, in the single bolus group, the mean visual analog scale (VAS) score changed from 0.85 to 4.93 between 1 and 12 hours after ARCR, and the use of narcotics in that group showed no difference compared with the other groups. They also reported that the ISB provided immediate pain control until 6 hours after surgery, with a significant rebound effect at 12 hours postoperative. Malik et al. [24] reported that continuous infusion was useful, but about 30% of patients experienced catheter failure, and the risk of phrenic nerve palsy and permanent neuropathy was higher than for a single bolus.

Yun et al. [33] reported that continuous-infusion ISB was more effective than a single bolus of ISB with intravenous PCA. Another study found that the failure rate of ISB was 13%, and one-third of the patients required intravenous pain medication [34]. However, Singh et al. [35] reported that ultrasound-assisted ISB was ultimately successful in almost all cases (99.6% of 1,319 patients), and 99.06% of patients responded that they were satisfied.

Table 1. Studies that analyzed the effects of regional blocks in arthroscopic rotator cuff repair

Variable	Level of evidence				
	I	II	III	IV	V
ISB	10	9	5	0	0
ISB+SSNB	6	1	1	1	0
SSNB	1	2	0	0	0
SSNB+ANB	2	3	0	0	0

We searched "regional block arthroscopic rotator cuff repair" in PubMed from January 2008 to August 2022.
ISB: interscalene nerve block, SSNB: suprascapular nerve block, ANB: axillary nerve block.

Suprascapular Nerve Block and Axillary Nerve Block

Recently, SSNB and ANB have been suggested to reduce postoperative pain after ARCR. These blocks can provide safe and effective intra- and postoperative analgesia during arthroscopy. Nam et al. [36] studied the anatomical location of the suprascapular nerve and axillary nerve in a cadaver. The suprascapular nerve is located in the middle of the anterior tip of the acromion and the superior angle of the scapula and at two-fifths of the way from the anterior tip of the acromion to the medial border of the spine. The depth of the suprascapular nerve is 3.2 cm from the skin. The axillary nerve is located three-fifths of the way from the ac-

https://doi.org/10.5397/cise.2022.01263

Table 2. Randomized control trials that analyzed the effects of regional blocks in arthroscopic rotator cuff repair

Study	Group (n)	Regimen	Acromioplasty	Pain	Satisfaction	Opioid consumption	Rebound pain	Complication	Conclusion	Level of evidence
Ikemoto et al. (2015) [14]	(1) SSNB (15) (2) ISB (15) (3) G/A only (15)	2/3 of 2 mg/kg 0.5% ropivacaine	+	+	–	+	–	–	SSNB had a similar efficacy to ISB.	Level 2
Lee et al. (2014) [15]	(1) SSNB+ANB (21) (2) SSNB only (21)	10 mL of 0.75% ropivacaine	+	+	+	–	+	–	SSNB combined with ANB was more effective than SSNB alone in controlling pain, satisfaction, and rebound pain.	Level 1
Lee et al. (2017) [16]	(1) SSNB+ISB (24) (2) ISB (24)	10 mL of 0.75% ropivacaine	+	+	+	–	+	–	The combined blocks (SSNB+ISB) relieved postoperative pain more effectively than ISB within 48 hours after arthroscopic cuff repair.	Level 1
Kim et al. (2021) [17]	(1) SSNB (31) (2) ISB (31) (3) Control (31)	(1) 20-mL bolus (mixed solution with 10 mL of 0.75% ropivacaine and 10 mL of lidocaine HCL and continuous infusion HCL injection (100 mL), 0.75% ropivacaine (100 mL), and normal saline (50 mL) (a total of 250 mL) (2) 15 mL of 2% lidocaine and 15 mL of 2% levobupivacaine 3. 30 ml of saline	+	+	–	–	+	–	The mean VAS scores were lowest in the SSNB group. Severity and recurring frequency of pain were lower in the SSNB group than in the ISB group.	Level 1
Desroches et al. (2016) [18]	(1) SSNB (28) (2) ISB (25)	(1) 10 mL of 0.75% ropivacaine (2) 20 mL bolus of 0.75% ropivacaine	NA	+	–	+	+	+	ISB was more effective in controlling pain in the recovery room, and SSB was as effective as ISB for mean pain control within the first 24 hours.	Level 1
Ko et al. (2017) [19]	(1) Blinded SSNB and ANB and then arthroscopy-guided SSNB (2) Blinded SSNB	10 mL of 0.25% ropivacaine	–	+	+	–	–	–	Arthroscopy-guided SSNB and blinded ANB provided greater improvement in VAS for pain and greater patient satisfaction than blinded SSNB.	Level 1

(Continued to the next page)

Table 2. Continued

Study	Group (n)	Regimen	Acromioplasty	Pain	Satisfaction	Opioid consumption	Rebound pain	Complication	Conclusion	Level of evidence
Salviz et al. (2013) [20]	(1) Single bolus ISB (23) (2) Continuous ISB (20) (3) G/A only (20)	(1) 20 mL of 0.5% ropivacaine (2) 20 mL of 0.5% ropivacaine + infusion of 0.2% ropivacaine at 5 mL/hr	+	+	−	+	+	−	The analgesic benefits of CISB found in the PACU and immediately after discharge extended through the intermediate recovery period ending on postoperative day 7.	Level 2
Lee et al. (2015) [21]	(1) SSNB (15) (2) Control (15)	(1) 10 mL of 0.50% ropivacaine (2) Saline	+	+	−	−	−	+	SSNB did not significantly reduce postoperative pain but reduced opioid consumption postoperatively.	Level 1
Hwang et al. (2020) [22]	(1) ISB with DEX (25) (2) ISB without DEX (25)	(1) 1 mL (100 μg) of DEX and 8 mL of 0.75% ropivacaine (2) 1 mL of normal saline and 8 mL of 0.75% ropivacaine	+	+	+	−	+	−	Ultrasound-guided ISB with DEX in arthroscopic rotator cuff repair led to a significantly lower mean VAS score and a significantly higher mean SAT score within 48 hours postoperatively.	Level 1
Lee et al. (2021) [23]	(1) SSNB and ANB with DEX (20) (2) SSNB and ANB without DEX (20)	(1) 0.5 mL (50 μg) of DEX and 9.5 mL of 0.75% ropivacaine (2) 0.5 mL of normal saline and 9.5 mL of 0.75% ropivacaine	+	+	+	−	+	−	Ultrasound-guided SSNA and ANB with DEX during arthroscopic rotator cuff repair resulted in a significantly lower mean VAS score and a significantly higher mean SAT score within 48 hours after the operation.	Level 1
Malik et al. (2016) [24]	(1) Continuous ISB (43) (2) Single bolus ISB (42)	(1) 0.125% bupivacaine at 5 mL/hr (2) 2.5 mg/kg of 0.5% bupivacaine up to 25 mL	−	+	−	+	−	+	A 3-day continuous interscalene brachial plexus block provided better analgesia than a single bolus block.	Level 1

SSNB: suprascapular nerve block, ISB: interscalene nerve block, G/A: general anesthesia, ANB: axillary nerve block, HCL: hydrochloride, VAS: visual analog scale, NA: not applicable, CISB: continuous ISB, PACU: post-anesthesia care unit, DEX: dexmedetomidine, SAT: satisfaction.

https://doi.org/10.5397/cise.2022.01263

romial angle to the inferior insertion of the teres major muscle. The depth of the axillary nerve is 2.1 cm from the skin. Lee et al. [15] showed that ultrasound-guided ANB combined with SSNB in ARCR had better outcomes in mean VAS in the first 24 hours after ARCR than with SSNB alone. Zhao et al. [37] also reported that SSNB and ANB had a better analgesic effect and greater patient satisfaction than SSNB alone. George et al. found that SSNB and ANB reduced opioid consumption after ARCR [38]. Barber [39] showed that SSNB could allow a patient to be discharged earlier from the hospital. Kim et al. [17] reported that arthroscopy-assisted SSNB is not inferior to ultrasound-guided continuous ISB for postoperative pain control and has few neurologic complications. Hussain et al. [40] conducted meta-analysis of SSNB versus ISB. They showed that there was no difference between SSNB and ISB in postoperative opioid consumption and, in the immediate postoperative recovery room, ISB reduced pain better than SSNB. However, at other times, there was no difference. Also, SSNB had fewer side effects [40]. Another meta-analysis showed that SSNB had a higher mean VAS than ISB at rest and while moving. Also, SSNB had a lower rate of complications such as Horner syndrome, numbness, dyspnea, and hoarseness. The suprascapular nerve is anatomically far from the phrenic nerve, but the axillary nerve is close to the phrenic nerve [41]. The ANB may affect the phrenic nerve, which could bring about diaphragmatic palsy and respiratory problems. Hand numbness and weakness, which are side effects of ISB, are less common with SSNB [42]. SSNB and ANB can be performed blind, arthroscopy-assisted, or ultrasound-assisted. Taskaynatan et al. [43] found that the success (including semi-success) rate of ultrasound-assisted SSNB assessed with neurostimulation was 21 of 27 (5 were successful, 16 were semi-successful). Ultrasonography is a radiation-free and real-time tool for verifying the location of the needle tip around the suprascapular notch for the suprascapular nerve and the posterior circumflex humeral artery for the axillary nerve. Ultrasound-assisted block is more effective than a blinded block [44,45]. Lee et al. [21] and Ko et al. [19] found that arthroscopy-assisted block was highly effective in controlling postoperative pain. Furthermore, Lee et al. [16] reported that arthroscopy-guided SSNB combined with ISB resulted in lower mean VAS and higher patient satisfaction scores than ISB alone. In their study, the authors found that the difference in duration between the two blocks might have led to a "fade away effect," a delay in mean timing of the rebound pain, decreasing the number of patients who experienced rebound pain in the group treated with SSNB combined with ISB compared to the group who received ISB alone.

Combined Use of α2-Agonist

Dexmedetomidine (DEX), a selective agonist of α2-adrenergic receptors, can be an effective adjuvant to local anesthetics for peripheral nerve blocks [22,23]. Preclinical and clinical studies have described a prolonged duration of analgesia when DEX was added to ropivacaine for regional nerve blocks [22,23]. One clinical trial found that ultrasound-guided ISB with DEX in ARCR led to a significantly lower mean VAS score and a significantly higher mean patient satisfaction score within 48 hours postoperatively, showing lower mean interleukin (IL)-6 and IL-8 levels than ISB alone with delayed rebound pain [22]. Another clinical trial reported that SSNB and ANB with DEX led to a similar effect as ISB with DEX. Additionally, SSNB and ANB with DEX resulted in later mean timing of rebound pain accompanied by significant changes in IL-8, IL-1β, and serotonin levels within 48 hours after the operation [23].

DISCUSSION

The most important finding of this review was that SSNB and ANB are not superior to ISB in reducing postoperative pain after ARCR. In addition, there was no difference in postoperative opioid consumption. Also, SSNB and ANB had fewer side effects than ISB. Pain control after ARCR is an issue of constant interest. The ARCR is considered one of the most painful arthroscopic shoulder surgeries, so postoperative pain control is important for early rehabilitation and recovery. There are many methods used for pain control, including PCA, opioids, and regional blocks. Regional blocks such as ISB and SSNB have recently been approved for pain control after shoulder arthroscopy. Koga et al. [46] showed no significant differences between SSNB and ISB regarding the use of additional analgesia, such as intravenous PCA and diclofenac. Sun et al. [47] reviewed a meta-analysis of randomized controlled trials and reported that the SSNB group experienced less pain control in the post-anesthesia care unit than the ISB group but experienced the same or higher pain control at later times. And SSNB with ANB could provide better pain control than SSNB alone [37]. This could be explained that the suprascapular nerve has a few cutaneous innervations so SSNB cannot influence skin incision and the suprascapular nerve innervates only 70% of joint capsule [48] and the axillary nerve innervates 25% of the joint capsule [26]. However, SSNB with ANB is not superior to ISB [40]. Opioids are commonly used for pain control after shoulder surgery, but they have side effects such as vomiting, nausea, respiratory depression, and low blood pressure [49]. All three block types can reduce opioid consumption [20,38]. but there are no differences in opioid use between ISB

and SSNB [17,47]. The rebound effect, which manifests as increased pain after a period of time, is found for both SSNB and ISB, especially 10 hours postoperatively [50]. However, another study reported that SSNB with ANB decreased the rebound effect compared to SSNB alone [15]. In this study, the difference in duration between the two blocks might lead to a "soft landing effect," which could decrease rebound pain with ANB combined with SSNB compared to SSNB alone. As we mentioned, there can be block-related complications after ISB, such as diaphragmatic hemiparesis, pneumothorax, or respiratory distress [51]. Some studies found that SSNB brought about lower incidence of those complications. Although ISB provides higher pain control in the immediate postoperative period, patients at risk of pulmonary problems should receive only ISB. The SSNB can be a safer choice in patients with chronic obstructive pulmonary disease [52], obstructive sleep apnea [53], and obesity [54]. The SSNB is relatively easier and faster to apply and is also safer with lower complication rates [46].

CONCLUSION

The ISB, SSNB, and ANB are commonly used for relieving perioperative pain from ARCR. There is no difference between ISB and SSNB in pain control or opioid consumption. The SSNB has a lower complication rate and can be more easily applied than ISB. Combined regional blocks might have a synergistic effect in relieving rebound pain, and DEX tends to improve the effect of regional blocks with an alteration of pain-related cytokines. While SSNB and ANB are easily performed by experienced orthopedic surgeons, ISB and DEX should be performed with cooperation of an anesthesiologist, considering the possible complications. Adequate regional blocks can be helpful for postoperative pain control of ARCR within 48 hours after surgery.

ORCID

Tae-Yeong Kim https://orcid.org/0000-0001-6384-1438
Jung-Taek Hwang https://orcid.org/0000-0003-4189-084X

REFERENCES

1. Wani Z, Abdulla M, Habeebullah A, Kalogriantis S. Rotator cuff tears: review of epidemiology, clinical assessment and operative treatment. Trauma 2016;18:190-204.
2. Hurley ET, Maye AB, Mullett H. Arthroscopic rotator cuff repair: a systematic review of overlapping meta-analyses. JBJS Rev 2019;7:e1.
3. Jain NB, Higgins LD, Losina E, Collins J, Blazar PE, Katz JN. Epidemiology of musculoskeletal upper extremity ambulatory surgery in the United States. BMC Musculoskelet Disord 2014;15:4.
4. Patel MS, Abboud JA, Sethi PM. Perioperative pain management for shoulder surgery: evolving techniques. J Shoulder Elbow Surg 2020;29:e416-33.
5. Warrender WJ, Syed UA, Hammoud S, et al. Pain management after outpatient shoulder arthroscopy: a systematic review of randomized controlled trials. Am J Sports Med 2017;45:1676-86.
6. Stiglitz Y, Gosselin O, Sedaghatian J, Sirveaux F, Molé D. Pain after shoulder arthroscopy: a prospective study on 231 cases. Orthop Traumatol Surg Res 2011;97:260-6.
7. Borgeat A, Ekatodramis G. Anaesthesia for shoulder surgery. Best Pract Res Clin Anaesthesiol 2002;16:211-25.
8. Boss AP, Maurer T, Seiler S, Aeschbach A, Hintermann B, Strebel S. Continuous subacromial bupivacaine infusion for postoperative analgesia after open acromioplasty and rotator cuff repair: preliminary results. J Shoulder Elbow Surg 2004;13:630-4.
9. Kelly DJ, Ahmad M, Brull SJ. Preemptive analgesia I: physiological pathways and pharmacological modalities. Can J Anaesth 2001;48:1000-10.
10. Teratani T. Effect of cocktail therapy after arthroscopic rotator cuff repair: a randomized, double-blind trial. J Shoulder Elbow Surg 2020;29:1310-5.
11. Al-Kaisy A, McGuire G, Chan VW, et al. Analgesic effect of interscalene block using low-dose bupivacaine for outpatient arthroscopic shoulder surgery. Reg Anesth Pain Med 1998;23:469-73.
12. Wurm WH, Concepcion M, Sternlicht A, et al. Preoperative interscalene block for elective shoulder surgery: loss of benefit over early postoperative block after patient discharge to home. Anesth Analg 2003;97:1620-6.
13. Urmey WF, McDonald M. Hemidiaphragmatic paresis during interscalene brachial plexus block: effects on pulmonary function and chest wall mechanics. Anesth Analg 1992;74:352-7.
14. Ikemoto RY, Murachovsky J, Prata Nascimento LG, et al. Prospective randomized study comparing two anesthetic methods for shoulder surgery. Rev Bras Ortop 2015;45:395-9.
15. Lee JJ, Kim DY, Hwang JT, et al. Effect of ultrasonographically guided axillary nerve block combined with suprascapular nerve block in arthroscopic rotator cuff repair: a randomized controlled trial. Arthroscopy 2014;30:906-14.
16. Lee JJ, Hwang JT, Kim DY, et al. Effects of arthroscopy-guided suprascapular nerve block combined with ultrasound-guided

interscalene brachial plexus block for arthroscopic rotator cuff repair: a randomized controlled trial. Knee Surg Sports Traumatol Arthrosc 2017;25:2121-8.
17. Kim H, Kim HJ, Lee ES, et al. Postoperative pain control after arthroscopic rotator cuff repair: arthroscopy-guided continuous suprascapular nerve block versus ultrasound-guided continuous interscalene block. Arthroscopy 2021;37:3229-37.
18. Desroches A, Klouche S, Schlur C, Bauer T, Waitzenegger T, Hardy P. Suprascapular nerve block versus interscalene block as analgesia after arthroscopic rotator cuff repair: a randomized controlled noninferiority trial. Arthroscopy 2016;32:2203-9.
19. Ko SH, Cho SD, Lee CC, et al. Comparison of arthroscopically guided suprascapular nerve block and blinded axillary nerve block vs. blinded suprascapular nerve block in arthroscopic rotator cuff repair: a randomized controlled trial. Clin Orthop Surg 2017;9:340-7.
20. Salviz EA, Xu D, Frulla A, et al. Continuous interscalene block in patients having outpatient rotator cuff repair surgery: a prospective randomized trial. Anesth Analg 2013;117:1485-92.
21. Lee JJ, Yoo YS, Hwang JT, et al. Efficacy of direct arthroscopy-guided suprascapular nerve block after arthroscopic rotator cuff repair: a prospective randomized study. Knee Surg Sports Traumatol Arthrosc 2015;23:562-6.
22. Hwang JT, Jang JS, Lee JJ, et al. Dexmedetomidine combined with interscalene brachial plexus block has a synergistic effect on relieving postoperative pain after arthroscopic rotator cuff repair. Knee Surg Sports Traumatol Arthrosc 2020;28:2343-53.
23. Lee JJ, Kim DY, Hwang JT, et al. Dexmedetomidine combined with suprascapular nerve block and axillary nerve block has a synergistic effect on relieving postoperative pain after arthroscopic rotator cuff repair. Knee Surg Sports Traumatol Arthrosc 2021;29:4022-31.
24. Malik T, Mass D, Cohn S. Postoperative analgesia in a prolonged continuous interscalene block versus single-shot block in outpatient arthroscopic rotator cuff repair: a prospective randomized study. Arthroscopy 2016;32:1544-50. e1.
25. Standring S. Shoulder girdle and arm. In: Standring S, ed. Gray's anatomy. 42nd ed. New York, NY: Elsevier: 2021. p. 892-929.
26. Vorster W, Lange CP, Briet RJ, et al. The sensory branch distribution of the suprascapular nerve: an anatomic study. J Shoulder Elbow Surg 2008;17:500-2.
27. Uz A, Apaydin N, Bozkurt M, Elhan A. The anatomic branch pattern of the axillary nerve. J Shoulder Elbow Surg 2007;16:240-4.
28. Borgeat A, Schappi B, Biasca N, Gerber C. Patient-controlled analgesia after major shoulder surgery: patient-controlled interscalene analgesia versus patient-controlled analgesia. Anesthesiology 1997;87:1343-7.
29. Abdallah FW, Halpern SH, Aoyama K, Brull R. Will the real benefits of single-shot interscalene block please stand up? A systematic review and meta-analysis. Anesth Analg 2015;120:1114-29.
30. Fredrickson MJ, Ball CM, Dalgleish AJ. Analgesic effectiveness of a continuous versus single-injection interscalene block for minor arthroscopic shoulder surgery. Reg Anesth Pain Med 2010;35:28-33.
31. Oksuz M, Abitagaoglu S, Kaciroglu A, et al. Effects of general anaesthesia and ultrasonography-guided interscalene block on pain and oxidative stress in shoulder arthroscopy: a randomised trial. Int J Clin Pract 2021;75:e14948.
32. Kim JH, Koh HJ, Kim DK, et al. Interscalene brachial plexus bolus block versus patient-controlled interscalene indwelling catheter analgesia for the first 48 hours after arthroscopic rotator cuff repair. J Shoulder Elbow Surg 2018;27:1243-50.
33. Yun S, Jo Y, Sim S, et al. Comparison of continuous and single interscalene block for quality of recovery score following arthroscopic rotator cuff repair. J Orthop Surg (Hong Kong) 2021;29:23094990211000142.
34. Weber SC, Jain R. Scalene regional anesthesia for shoulder surgery in a community setting: an assessment of risk. J Bone Joint Surg Am 2002;84:775-9.
35. Singh A, Kelly C, O'Brien T, Wilson J, Warner JJ. Ultrasound-guided interscalene block anesthesia for shoulder arthroscopy: a prospective study of 1319 patients. J Bone Joint Surg Am 2012;94:2040-6.
36. Nam YS, Jeong JJ, Han SH, et al. An anatomic and clinical study of the suprascapular and axillary nerve blocks for shoulder arthroscopy. J Shoulder Elbow Surg 2011;20:1061-8.
37. Zhao J, Xu N, Li J, et al. Efficacy and safety of suprascapular nerve block combined with axillary nerve block for arthroscopic shoulder surgery: a systematic review and meta-analysis of randomized controlled trials. Int J Surg 2021;94:106111.
38. Caldwell GL, Selepec MA. Surgeon-administered nerve block during rotator cuff repair can promote recovery with little or no post-operative opioid use. HSS J 2020;16(Suppl 2):349-57.
39. Barber FA. Suprascapular nerve block for shoulder arthroscopy. Arthroscopy 2005;21:1015.
40. Hussain N, Goldar G, Ragina N, Banfield L, Laffey JG, Abdallah FW. Suprascapular and interscalene nerve block for shoulder surgery: a systematic review and meta-analysis. Anesthesiology 2017;127:998-1013.
41. Park JY, Bang JY, Oh KS. Blind suprascapular and axillary nerve block for post-operative pain in arthroscopic rotator cuff surgery. Knee Surg Sports Traumatol Arthrosc 2016;24:3877-83.

42. Auyong DB, Hanson NA, Joseph RS, Schmidt BE, Slee AE, Yuan SC. Comparison of anterior suprascapular, supraclavicular, and interscalene nerve block approaches for major outpatient arthroscopic shoulder surgery: a randomized, double-blind, noninferiority trial. Anesthesiology 2018;129:47-57.
43. Taskaynatan MA, Ozgul A, Aydemir K, Koroglu OO, Tan AK. Accuracy of ultrasound-guided suprascapular nerve block measured with neurostimulation. Rheumatol Int 2012;32:2125-8.
44. Gorthi V, Moon YL, Kang JH. The effectiveness of ultrasonography-guided suprascapular nerve block for perishoulder pain. Orthopedics 2010;33:1-4.
45. Rothe C, Lund J, Jenstrup MT, Lundstrøm LH, Lange KH. Ultrasound-guided block of the axillary nerve: a case series of potential clinical applications. Acta Anaesthesiol Scand 2012;56:926-30.
46. Koga R, Funakoshi T, Yamamoto Y, Kusano H. Suprascapular nerve block versus interscalene block for analgesia after arthroscopic rotator cuff repair. J Orthop 2019;19:28-30.
47. Sun C, Ji X, Zhang X, et al. Suprascapular nerve block is a clinically attractive alternative to interscalene nerve block during arthroscopic shoulder surgery: a meta-analysis of randomized controlled trials. J Orthop Surg Res 2021;16:376.
48. Chan CW, Peng PW. Suprascapular nerve block: a narrative review. Reg Anesth Pain Med 2011;36:358-73.
49. Manchikanti L, Fellows B, Ailinani H, Pampati V. Therapeutic use, abuse, and nonmedical use of opioids: a ten-year perspective. Pain Physician 2010;13:401-35.
50. Oh JH, Kim WS, Kim JY, Gong HS, Rhee KY. Continuous intralesional infusion combined with interscalene block was effective for postoperative analgesia after arthroscopic shoulder surgery. J Shoulder Elbow Surg 2007;16:295-9.
51. Lenters TR, Davies J, Matsen FA. The types and severity of complications associated with interscalene brachial plexus block anesthesia: local and national evidence. J Shoulder Elbow Surg 2007;16:379-87.
52. Urmey WF, Talts KH, Sharrock NE. One hundred percent incidence of hemidiaphragmatic paresis associated with interscalene brachial plexus anesthesia as diagnosed by ultrasonography. Anesth Analg 1991;72:498-503.
53. D'Apuzzo MR, Browne JA. Obstructive sleep apnea as a risk factor for postoperative complications after revision joint arthroplasty. J Arthroplasty 2012;27(8 Suppl):95-8.
54. Griffin JW, Novicoff WM, Browne JA, Brockmeier SF. Morbid obesity in total shoulder arthroplasty: risk, outcomes, and cost analysis. J Shoulder Elbow Surg 2014;23:1444-8.

https://doi.org/10.5397/cise.2022.01263

CiSE
Clinics in Shoulder and Elbow

Instructions to authors

Enacted from June 1, 2009
Revised on December 31, 2010
June 1, 2013
March 1, 2014
May 13, 2014
September 1, 2017
March 1, 2019
December 1, 2019

1. AIMS AND SCOPE

CiSE is an international, peer-reviewed journal and the official journal of Korean Shoulder and Elbow Society. It was first launched in 1998. It is published quarterly in the first day of March, June, September, and December, with articles in English, and has been published as an online-only journal since 2019.

The purpose of CiSE are: first to contribute in the management and education of shoulder and elbow topics; second, to share latest scientific informations among international societies; and finally to promote communications on shoulder/elbow problems and patient care. It can cover all fields of clinical and basic researches in shoulder and elbow.

Manuscripts submitted to CiSE should be prepared according to the following instructions. CiSE follows the Recommendations for the Conduct, Reporting, Editing, and Publication of Scholarly Work in Medical Journals (http://www.icmje.org/icmje-recommendations.pdf) from the International Committee of Medical Journal Editors (ICMJE).

2. RESEARCH AND PUBLICATION ETHICS

The journal adheres to the guidelines and best practices published by professional organizations, including ICMJE Recommendations and the Principles of Transparency and Best Practice in Scholarly Publishing (joint statement by the Committee on Publication Ethics [COPE], Directory of Open Access Journals [DOAJ], World Association of Medical Editors [WAME], and Open Access Scholarly Publishers Association [OASPA]; https://doaj.org/bestpractice). Further, all processes of handling research and publication misconduct shall follow the applicable COPE flowchart (https://publicationethics.org/resources/flowcharts).

Statement of Human and Animal Rights

Clinical research should be conducted in accordance with the World Medical Association's Declaration of Helsinki (https://www.wma.net/what-we-do/medical-ethics/declaration-of-helsinki/). Clinical studies that do not meet the Helsinki Declaration will not be considered for publication. For human subjects, identifiable information, such as patients' names, initials, hospital numbers, dates of birth, and other protected health care information, should not be disclosed. For animal subjects, research should be performed based on the National or Institutional Guide for the Care and Use of Laboratory Animals. The ethical treatment of all experimental animals should be maintained.

Statement of Informed Consent and Institutional Approval

Copies of written informed consent should be kept for studies on human subjects. Clinical studies with human subjects should provide a certificate, an agreement, or the approval by the Institutional Review Board (IRB) of the author's affiliated institution. For research with animal subjects, studies should be approved by an Institutional Animal Care and Use Committee (IACUC). If necessary, the editor or reviewers may request copies of these documents to resolve questions regarding IRB/IACUC approval and study conduct.

Conflict of Interest Statement

The author is responsible for disclosing any financial support or benefit that might affect the content of the manuscript or might cause a conflict of interest. When submitting the manuscript, the author must attach the letter of conflict of interest statement (http://cisejournal.org/authors/copyright_transfer_agreement.php). Examples of potential conflicts of interest are financial support from or connections to companies, political pressure from interest groups, and academically related issues. In particular, all sources of funding applicable to the study should be explicitly stated.

Originality, Plagiarism, and Duplicate Publication

Redundant or duplicate publication refers to the publication of a paper that overlaps substantially with one already published. Upon receipt, submitted manuscripts are screened for possible

plagiarism or duplicate publication using Crossref Similarity Check. If a paper that might be regarded as duplicate or redundant had already been published in another journal or submitted for publication, the author should notify the fact in advance at the time of submission. Under these conditions, any such work should be referred to and referenced in the new paper. The new manuscript should be submitted together with copies of the duplicate or redundant material to the editorial committee. If redundant or duplicate publication is attempted or occurs without such notification, the submitted manuscript will be rejected immediately. If the editor was not aware of the violations and of the fact that the article had already been published, the editor will announce in the journal that the submitted manuscript had already been published in a duplicate or redundant manner, without seeking the author's explanation or approval.

Secondary Publication

It is possible to republish manuscripts if the manuscripts satisfy the conditions for secondary publication of the ICMJE Recommendations.

Authorship and Author's Responsibility

Authorship credit should be based on (1) substantial contributions to conception and design, acquisition of data, and analysis and interpretation of data; (2) drafting the article or revising it critically for important intellectual content; (3) final approval of the version to be published; and (4) agreement to be accountable for all aspects of the work in ensuring that questions related to the accuracy or integrity of any part of the work are appropriately investigated and resolved. Authors should meet these four conditions.

- The contributions of all authors must be described. CiSE has adopted the CRediT Taxonomy (https://www.casrai.org/credit.html) to describe each author's individual contributions to the work. The role of each author and ORCID number should be addressed in the title page.
- Correction of authorship: Any requests for such changes in authorship (adding author(s), removing author(s), or re-arranging the order of authors) after the initial manuscript submission and before publication should be explained in writing to the editor in a letter or e-mail from all authors. This letter must be signed by all authors of the paper. A copyright assignment must be completed by every author.
- Role of corresponding author: The corresponding author takes primary responsibility for communication with the journal during the manuscript submission, peer review, and publication process. The corresponding author typically ensures that all of the journal's administrative requirements, such as providing the details of authorship, ethics committee approval, clinical trial registration documentation, and conflict of interest forms and statements, are properly completed, although these duties may be delegated to one or more coauthors. The corresponding author should be available throughout the submission and peer review process to respond to editorial queries in a timely manner, and after publication, should be available to respond to critiques of the work and cooperate with any requests from the journal for data or additional information or questions about the article.
- Contributors: Any researcher who does not meet all four ICMJE criteria for authorship discussed above but contribute substantively to the study in terms of idea development, manuscript writing, conducting research, data analysis, and financial support should have their contributions listed in the Acknowledgments section of the article.

Process for Managing Research and Publication Misconduct

When the journal faces suspected cases of research and publication misconduct, such as redundant (duplicate) publication, plagiarism, fraudulent or fabricated data, changes in authorship, undisclosed conflict of interest, ethical problems with a submitted manuscript, appropriation by a reviewer of an author's idea or data, and complaints against editors, the resolution process will follow the flowchart provided by COPE (http://publicationethics.org/resources/flowcharts). The discussion and decision on the suspected cases are carried out by the Editorial Board.

Editorial Responsibilities

The Editorial Board will continuously work to monitor and safeguard publication ethics: guidelines for retracting articles; maintenance of the integrity of academic records; preclusion of business needs from compromising intellectual and ethical standards; publishing corrections, clarifications, retractions, and apologies when needed; and excluding plagiarized and fraudulent data. The editors maintain the following responsibilities: responsibility and authority to reject and accept articles; avoid any conflict of interest with respect to articles they reject or accept; promote the publication of corrections or retractions when errors are found; and preserve the anonymity of reviewers.

3. EDITORIAL POLICY

Copyright

Copyright in all published material is owned by the Korean Shoulder and Elbow Society. Authors must agree to transfer copyright (http://cisejournal.org/authors/copyright_transfer_agreement.

php) during the submission process. The corresponding author is responsible for submitting the copyright transfer agreement to the publisher.

Open Access Policy

CiSE is an open-access journal. Articles are distributed under the terms of the Creative Commons Attribution License (http://creativecommons.org/licenses/by-nc/4.0/), which permits unrestricted non-commercial use, distribution, and reproduction in any medium, provided the original work is properly cited. Author(s) do not need to permission to use tables or figures published in CiSE in other journals, books, or media for scholarly and educational purposes. This policy is in accordance with the Budapest Open Access Initiative definition of open access.

Registration of Clinical Trial Research

It is recommended that any research that deals with a clinical trial be registered with a clinical trial registration site, such as http://cris.nih.go.kr, http://www.who.int/ictrp/en, and http://clinicaltrials.gov.

Data Sharing

ICiSE encourages data sharing wherever possible, unless this is prevented by ethical, privacy, or confidentiality matters. Authors wishing to do so may deposit their data in a publicly accessible repository and include a link to the DOI within the text of the manuscript.

- Clinical Trials: CiSE accepts the ICMJE Recommendations for data sharing statement policy. Authors may refer to the editorial, "Data Sharing statements for Clinical Trials: A Requirement of the International Committee of Medical Journal Editors," in the Journal of Korean Medical Science (https://dx.doi.org/10.3346/jkms.2017.32.7.1051).

Archiving Policy

CiSE provides electronic archiving and preservation of access to the journal content in the event the journal is no longer published, by archiving in the National Library of Korea. According to the deposit policy (self-archiving policy) of Sherpa/Romeo (http://www.sherpa.ac.uk/), authors cannot archive pre-print (i.e., pre-refereeing) but they can archive post-print (i.e., final draft post-refereeing). Authors can archive the publisher's version/PDF.

4. SUBMISSION AND PEER-REVIEW PROCESS

Submission

All manuscripts should be submitted online via the journal's website (https://submit.cisejournal.org/) by the corresponding author. Once you have logged into your account, the online system will lead you through the submission process in a stepwise orderly process. Submission instructions are available at the website. All articles submitted to the journal must comply with these instructions. Failure to do so will result in the return of the manuscript and possible delay in publication.

Peer Review Process

All papers, including those invited by the Editor, are subject to peer review. Manuscripts will be peer-reviewed by two accredited experts in the shoulder and elbow with one additional review by prominent member from our editorial board. CiSE's average turnaround time from submission to decision is 4 weeks. The editor is responsible for the final decision whether the manuscript is accepted or rejected.

- The journal uses a double-blind peer review process: the reviewers do not know the identity of the authors, and vice versa.
- Decision letter will be sent to corresponding author via registered e-mail. Reviewers can request authors to revise the content. The corresponding author must indicate the modifications made in their item-by-item response to the reviewers' comments. Failure to resubmit the revised manuscript within 4 weeks of the editorial decision is regarded as a withdrawal.
- The editorial committee has the right to revise the manuscript without the authors' consent, unless the revision substantially affects the original content.
- After review, the editorial board determines whether the manuscript is accepted for publication or not. Once rejected, the manuscript does not undergo another round of review.

Appeals of Decisions

Any appeal against an editorial decision must be made within 2 weeks of the date of the decision letter. Authors who wish to appeal a decision should contact the Editor-in-Chief, explaining in detail the reasons for the appeal. All appeals will be discussed with at least one other associate editor. If consensus cannot be reached thereby, an appeal will be discussed at a full editorial meeting. The process of handling complaints and appeals follows the guidelines of COPE available from (https://publicationethics.org/appeals). CiSE does not consider second appeals.

5. MANUSCRIPT PREPARATION

Authors are required to submit their manuscripts after reading the following instructions. Any manuscript that does not conform to the following requirements will be considered inappropriate and may be returned.

General Requirements

- All manuscripts should be written in English.
- The manuscript must be written using Microsoft Word and saved as ".doc" or ".docx" file format. The font size must be 12 points. The body text must be left aligned, double spaced, and presented in one column. The left, right, and bottom margins must be 3 cm, but the top margin must be 3.5 cm.
- The page numbers must be indicated in Arabic numerals in the middle of the bottom margin, starting from the abstract page.
- Neither the authors' names nor their affiliations should appear on the manuscript pages.
- Only standard abbreviations should be used. Abbreviations should be avoided in the title of the manuscript. Abbreviations should be spelled out when first used in the text and the use of abbreviations should be kept to a minimum.
- The names and locations (city, state, and country only) of manufacturers of equipment and non-generic drugs should be given.
- Authors should express all measurements in conventional units using International System (SI) units.
- P-value from statistical testing is expressed as capital P.

Reporting Guidelines for Specific Study Designs

For specific study designs, such as randomized control studies, studies of diagnostic accuracy, meta-analyses, observational studies, and non-randomized studies, authors are encouraged to consult the reporting guidelines relevant to their specific research design. A good source of reporting guidelines is the EQUATOR Network (https://www.equator-network.org/) and NLM (https://www.nlm.nih.gov/services/research_report_guide.html).

Composition of Manuscripts

- The manuscript types are divided into Original Article, Review Article, Case Report, and other types. There is no limit to the length of each manuscript; however, if unnecessarily long, the author may be penalized during the review process.
- Original Articles should be written in the following order: title page, abstract, keywords, main body (introduction, methods, results, discussion), acknowledgments (if necessary), references, tables, figure legends, and figures. The number of references is limited to 30.
- Review Articles should focus on a specific topic. Format of a review article is not limited. Publication of these articles will be decided upon by the Editorial Board.
- Case Reports should be written in the following order: title page, abstract, keywords, main body (introduction, case report, discussion), acknowledgments (if necessary), references, tables, figure legends, and figures. The number of references is limited to 10.

The Aabstract should not exceed 200 words, and must be written as one unstructured paragraph. Authors are warned that these have a high rejection rate.

- Technical Notes should not exceed 1,500 words. The abstract should be an unstructured summary not exceeding 150 words. The body of these manuscripts should consist of introduction, technique, discussion, references, and figure legends and tables (if applicable). References should not exceed 10. A maximum of 3 figures and 1 table are allowed.
- Current Concepts deal with most current trends and controversies of a single topic in shoulder and elbow. Authors are recommended to update all the knowledge to most recent studies and researches.
- Systematic Review examines published material on a clearly described subject in a systematic way. There must be a description of how the evidence on this topic was tracked down, from what sources and with what inclusion and exclusion criteria.
- Meta-analysis: A systematic overview of studies that pools results of two or more studies to obtain an overall answer to a question or interest. Summarizes quantitatively the evidence regarding a treatment, procedure, or association.
- Letters to the Editor: The journal welcomes readers' comments on articles published recently in the journal or orthopedic topics of interest.
- Editorial is invited by the editors and should be commentaries on articles published recently in the journal. Editorial topics could include active areas of research, fresh insights, and debates in the field of orthopedic surgery. Editorials should not exceed 1,000 words, excluding references, tables, and figures.
- Concise Review is short version of systemic review requested to submit in the journal by the Editorial board. Usually, previous papers regarding such topic were published by the main author(s).
- Special Reports/Expert Opinions (Level V studies) of various topics in shoulder and elbow can be submitted. They are limited to 2,700 words excluding references, tables, and figures.

Title Page

- The title page must include a title, the authors' names and academic degrees (include ORCID*), affiliations, and corresponding authors' names and contact information. In addition, a running title must be written in English within up to 50 characters including spaces. The corresponding authors' contact information must include a name, addresses, e-mails, telephone numbers, and fax numbers.
- **ORCID:** We recommend that the open researcher and contributor ID (ORCID) of all authors be provided. To have an ORCID,

authors should register in the ORCID website: http://orcid.org/. Registration is free to every researcher in the world.

- If there are more than two authors, a comma must be placed between their names (with academic titles). Authors' academic titles must be indicated after their names.
- The contributions of all authors must be described using the CRediT (https://www.casrai.org/credit.html) Taxonomy of author roles. All persons who have made substantial contributions, but who have not met the criteria for authorship, are acknowledged here.
- All sources of funding applicable to the study should be stated here explicitly.

Abstract and Keywords

Each paper should start with an abstract not exceeding 250 words. The abstract should state the background, methods, results, and conclusions in each paragraph in a brief and coherent manner. Relevant numerical data should be included. Under the abstract, keywords should be inserted (maximum 5 words). Authors are recommended to use the MeSH database to find Medical Subject Heading Terms at http://www.nlm.nih.gov/mesh/meshhome.html. The abstract should be structured into the following sections.

- Background: The rationale, importance, or objective of the study should be described briefly and concisely in one to two sentences. The objective should be consistent with that stated in the Introduction.
- Methods: The procedures conducted to achieve the study objective should be described in detail, together with relevant details concerning how data were obtained and analyzed and how research bias was adjusted.
- Results: The most important study results and analysis should be presented in a logical manner with specific experimental data.
- Conclusions: The conclusions derived from the results should be described in one to two sentences, and must match the study objective.

A Structured Abstract consisting of 5 paragraphs, totaling no more than 325 words, with the headings: Background (stating the primary research question), Methods, Results, Conclusions, and Level of Evidence (for Clinical Research articles) or Clinical Relevance (for Basic-Science Research articles). The Level of Evidence should be assigned according to the definitions in the Level of Evidence table.

Guidelines for the Main Body

- All articles using clinical samples or data and those involving animals must include information on the IRB/IACUC approval or waiver and informed consent. An example is shown below. "We conducted this study in compliance with the principles of the Declaration of Helsinki. The study's protocol was reviewed and approved by the Institutional Review Board of OO (IRB no. OO). Written informed consent was obtained / Informed consent was waived."
- Description of participants: Ensure the correct use of the terms "sex" (when reporting biological factors) and "gender" (identity, psychosocial, or cultural factors), and, unless inappropriate, report the sex and/or gender of study participants, the sex of animals or cells, and describe the methods used to determine sex and gender. If the study was done involving an exclusive population, for example, in only one sex, authors should justify why, except in obvious cases (e.g., ovarian cancer). Authors should define how they determined race or ethnicity and justify their relevance.
- Introduction: State the background or problem that led to the initiation of the study. Introduction is not a book review, rather it is best when the authors bring out controversies which create interest. Lead systematically to the hypothesis of the study, and finally, to a restatement of the study objective, which should match that in the Abstract. Do not include conclusions in the Introduction.
- Methods: Describe the study design (prospective or retrospective, inclusion and exclusion criteria, duration of the study) and the study population (demographics, length of follow-up). Explanations of the experimental methods should be concise, but yet enable replication by a qualified investigator.
- Results: This section should include detailed reports on the data obtained during the study. All data in the text must be presented in a consistent manner throughout the manuscript. All issues which the authors brought up in the method section need to be in result section. Also it is preferred that data to be in figures or table rather than long list of numbers. Instead, numbers should be in tables or figures with key comment on the findings.
- Discussion: The first paragraph of the discussion should deal with the key point in this study. Do not start by article review or general comment on the study topic. In the Discussion, data should be interpreted to demonstrate whether they affirm or refute the original hypothesis. Discuss elements related to the purpose of the study and present the rationales that support the conclusion drawn by referring to relevant literature. Discussion needs some comparison of similar papers published previously, and discuss why your study is different or similar from those papers. Care should be taken to avoid information obtained from books, historical facts, and irrelevant information. A dis-

cussion of study weaknesses and limitations should be included in the last paragraph of the discussion. Lastly you must briefly state your new (or verified) view of the problem you outlined in the Introduction.

- References must be numbered with superscripts according to their quotation order. When more than two quotations of the same authors are indicated in the main body, a comma must be placed between a discontinuous set of numbers, whereas a dash must be placed between the first and last numerals of a continuous set of numbers: "Kim et al. [2,8,9] insisted…" and "However, Park et al. [11–14] showed opposing research results."
- Figures and tables used in the main body must be indicated as "Fig." and "Table." For example, "Magnetic resonance imaging of the brain revealed… (Figs. 1–3).

Figures and Figure Legends

Figures should be cited in the text and are numbered using Arabic numbers in the order of their citation (e.g., Fig. 1). Figures are not embedded within the text. Each figure should be submitted as an individual file. Location of figure legends begins at the next page after last table. Every figure has its own legend. Abbreviation and additional information for any clarification should be described within each figure legend. Figure files are submitted in EPS, TIFF, or PDF formats. Requirement for minimum resolutions are dependent on figure types. For line drawings, 1,200 dpi are required. For grey color works (i.e., picture of gel or blots), 600 dpi are required. For color or half-tone artworks, 300 dpi are required. The files are named by the figure number.

- Staining techniques used should be described. Photomicrographs with no inset scale should have the magnification of the print in the legend.
- Papers containing unclear photographic prints may be rejected.
- Remove any writing that could identify a patient.
- Any illustrations previously published should be accompanied by the written consent of the copyright holder.

Tables

- Tables should be numbered sequentially with Arabic numerals in the order in which they are mentioned in the text.
- If an abbreviation is used in a table, it should be defined in a footnote below the table.
- Additional information for any clarification is designated for citation using alphabetical superscripts ([a], [b]…) or asterisks (*). Explanation for superscript citation should be done as following examples: [a]Not tested. *$P < 0.05$, **$P < 0.01$, ***$P < 0.001$.
- Tables should be understandable and self-explanatory, without references to the text.

References

- The number of references is recommended to 30 for original article and 10 for case report and technical note.
- All references must be cited in the text. The number assigned to the reference citation is according to the first appearance in the manuscript. References in tables or figures are also numbered according to the appearance order. Reference number in the text, tables, and figures should in a bracket ([ ]).
- List names of all authors when six or fewer. When seven or more, list only the first three names and add et al.
- Authors should be listed by surname followed by initials.
- The journals should be abbreviated according to the style used in the list of journals indexed in the NLM Journal Catalog (http://www.ncbi.nlm.nih.gov/nlmcatalog/journals).
- The overlapped numerals between the first page and the last page must be omitted (e.g., 2025-6).
- References to unpublished material, such as personal communications and unpublished data, should be noted within the text and not cited in the References. Personal communications and unpublished data must include the individual's name, location, and date of communication.
- Other types of references not described below should follow ICMJE Recommendations (https://www.nlm.nih.gov/bsd/uniform_requirements.html).
- Examples of references are as follows:

Journal article

1. Kim IB, Kim EY, Lim KP, Heo KS, Does the use of injectable atelocollagen during arthroscopic rotator cuff repair improve clinical and structural outcomes? Clin Shoulder Elbow 2019;22:183-9.
2. Kovacevic D, Fox AJ, Bedi A, et al. Calcium-phosphate matrix with or without TGF-β3 improves tendon-bone healing after rotator cuff repair. Am J Sports Med 2011;39:811-9.
3. Nord KD, Masterson JP, Mauck BM. Superior labrum anterior posterior (SLAP) repair using the Neviaser portal. Arthroscopy 2004;20 Suppl 2:129-33.
4. Rohner E, Jacob B, Bohle S, et al. Sodium hypochlorite is more effective than chlorhexidine for eradication of bacterial biofilm of staphylococci and Pseudomonas aeruginosa. Knee Surg Sports Traumatol Arthrosc 2020 Feb 7 [Epub]. https://doi.org/10.1007/s00167-020-05887-9

Book & book chapter

5. Iannotti JP, Williams Jr GR. Disorders of the shoulder: diagnosis & management. 2nd ed. Philadelphia, PA: Lippincott Williams & Wilkins; 2007. p. 66-80
6. Provencher MP, LeClere LE, Van Thiel GS, et al. Posterior instability of the shoulder. In: Angelo RL, Esch JC, Ryu RK, eds. AANA advanced arthroscopy the shoulder. Philadelphia, PA: Saunders; 2010. p. 115-23.

Website

7. American Cancer Society. Cancer facts & figures 2020 [Internet]. Atlanta, GA: American Cancer Society; c2020 [cited 2020 Feb 5]. Available from: https://www.cancer.org/research/cancer-facts-statistics/all-cancer-facts-figures/cancer-facts-figures-2020.html.

6. FINAL PREPARATION FOR PUBLICATION

Final Version

After the paper has been accepted for publication, the author(s) should submit the final version of the manuscript. The names and affiliations of the authors should be double-checked, and if the originally submitted image files were of poor resolution, higher resolution image files should be submitted at this time. Symbols (e.g., circles, triangles, squares), letters (e.g., words, abbreviations), and numbers should be large enough to be legible on reduction to the journal's column widths. All symbols must be defined in the figure caption. If references, tables, or figures are moved, added, or deleted during the revision process, renumber them to reflect such changes so that all tables, references, and figures are cited in numeric order.

Manuscript Corrections

Before publication, the manuscript editor will correct the manuscript such that it meets the standard publication format. The author(s) must respond within two days when the manuscript editor contacts the corresponding author for revisions. If the response is delayed, the manuscript's publication may be postponed to the next issue.

Gallery Proof

The author(s) will receive the final version of the manuscript as a PDF file. Upon receipt, the author(s) must notify the editorial office (or printing office) of any errors found in the file within two days. Any errors found after this time are the responsibility of the author(s) and will have to be corrected as an erratum.

Errata and Corrigenda

To correct errors in published articles, the corresponding author should contact the journal's Editorial Office with a detailed description of the proposed correction. Corrections that profoundly affect the interpretation or conclusions of the article will be reviewed by the editors. Corrections will be published as corrigenda (corrections of the author's errors) or errata (corrections of the publisher's errors) in a later issue of the journal.

7. ARTICLE PROCESSING CHARGES

There are no author fees required for manuscript processing and/or publishing materials in the journal since all cost is supported by the publisher, the Korean Shoulder and Elbow Society until there is a policy change. Therefore, it is the so-called platinum open access journal.

CiSE
Clinics in Shoulder and Elbow

Author's checklist

- ☐ Manuscript in MS-WORD (.doc) format.
- ☐ Double-spaced typing with 10-point font.
- ☐ Sequence of title page, abstract and keywords, introduction, methods, results, discussion, conclusions, acknowledgments, references, tables, and figure legends. All pages and manuscript text with line should be numbered sequentially, starting from the abstract.
- ☐ Title page with article title, authors' full name(s) and affiliation(s), address for correspondence (including telephone number, e-mail address, and fax number), running title (less than 10 words), and acknowledgments, if any.
- ☐ Abstract in structured format up to 250 words for original articles and in unstructured format up to 200 words for case reports. Keywords (up to 5) from the MeSH list of Index Medicus.
- ☐ All table and figure numbers are found in the text.
- ☐ Figures as separate files, in JPG, GIF, or PPT format.
- ☐ References listed in proper format. All references listed in the reference section are cited in the text and vice versa.
- ☐ Covering letter signed by the corresponding author.

Copyright transfer agreement

CiSE
Clinics in Shoulder and Elbow

Clinics in Shoulder and Elbow requires a formal written Copyright Transfer Form of the author(s) for each article published. We therefore ask you to complete and return this form, retaining a copy for your records. Your cooperation is essential and appreciated. Publication cannot proceed without a signed copy of this agreement. If the manuscript is not published in Clinics in Shoulder and Elbow, this agreement shall be null and void.

Copyright Transfer Agreement. I/we have read and agreed with the terms and conditions stated on this page of this agreement. I/we hereby confirm the transfer of all copyrights in and relating to the manuscript, in all forms and media of expression now known or developed in the future, including reprints, translations, photographic reproductions, microform, electronic form (offline, online) or any other reproductions of similar nature, to Korean Shoulder and Elbow Society, effective from the date stated below. I/we acknowledge that Korean Shoulder and Elbow Society are relying on this agreement in publishing the manuscript.

Manuscript Title:

Manuscript Number (if applicable):

Date:

All authors appearing in manuscript should be signed in order.

Each of the undersigned is an author of the manuscript and all authors are named on this document.

Print Name	Signature